Haryana Vet. **50** (December, 2011), pp 89-91

Research Article

AN OUTBREAK OF PNEUMONIC MANNHEIMIOSIS IN A LIVESTOCK FARM IN SUB-TEMPERATE REGION OF INDIA

R. K. SHARMA[1*], R. D. PATIL[2], R. S. KISHTWARIA[1] and R. K. ASRANI[2]
[1]Department of Livestock Farm, [2]Department of Veterinary Pathology
Dr. G. C. Negi College of Veterinary and Animal Sciences
CSK Himachal Pradesh Agricultural University, Palampur-176 062

ABSTRACT

Respiratory mannheimiosis is a highly contagious disease of ruminants caused by *Mannheimia haemolytica*. A sudden onset of a respiratory disease characterized by high fever with ocular and nasal discharge was observed in the month of July, 2011 in cow calves (six months to one year age) in a livestock farm. Necropsy examination was conducted on four carcasses. Grossly, lungs revealed congestion, haemorrhages and the prominent interlobular septa which were massively filled with fibrinous exudate. Microscopically, there was congestion, haemorrhages, fibrinous exudation along with massive infiltration of neutrophils in the alveoli, bronchi and bronchioles. Giemsa and Gram's stained impression smears from the lung tissue and other body tissues/fluid revealed the presence of characteristic oat shaped cells and bipolar gram negative bacteria, respectively. The presence of oat shaped cells along with gross and microscopic changes predominant in the lungs was indicative of an outbreak due to pneumonic mannheimiosis. Sick animals were isolated and immediately treated with antibiotics along with administration of non-steroidal anti-inflammatory drugs which lead to uneventful recovery.

Key words: Mannheimiosis, bovine calves, pathology, lungs, pneumonia

Respiratory tract infections are common in domestic and farm animals throughout the world. Respiratory mannheimiosis or pneumonic mannheimiosis is a highly contagious disease of intensively reared cattle particularly in animals of age from 6 months to 2 years and results in high morbidity and mortality. This disease is highly infectious with severe clinical symptoms and is often fatal (Mohamed and Addelsalam, 2008). The incubation period of the disease ranges from 3 to 5 days, however, acute onset is not uncommon (De Alvis, 1992). It is widespread in prevalence in ruminants and results in severe economical losses to the livestock industry (Jensen *et al.*, 1976; Kelly and Janzen, 1986). The disease is caused by *Mannheimia haemolytica* (formerly known as *Pasteurella haemolytica*) (Adamu and Ameh, 2007). *M. haemolytica* is a pathogenic Gram-negative, non-motile coccobacillus belonging to the family *Pasteurellaceae* and has three subspecies, five capsular serogroups and 16 serotypes (Dabo *et al.*, 2007).

The outbreaks of mannheimiosis are generally noted at the beginning of the rainy season; however, the disease can occur throughout the year in the endemic areas (Karimkhani *et al.*, 2011). Since this disease has similarities with respiratory diseases of cattle and sheep; therefore it is critical to diagnose the disease right at the outset of an outbreak to prevent further transmission for safeguarding the health of livestock.

MATERIALS AND METHODS

The calf section of the livestock farm of Himachal Pradesh Krishi Vishvavidyalaya, Palampur houses about 50 young cow calves at a time, of which 30 calves are of age between six months to one year. Sudden death of four calves was noticed within a period of 48 hours in July, 2011. These animals were immediately sent for detailed postmortem examination. Apparently 14 more calves were found lethargic and depressed. These calves developed fever (104-106^{0}F) and their feed intake was markedly reduced, although decline in water intake was not appreciably noticed. Bilateral muco-purulent discharge from the nostrils and coughing was also observed. Other typical findings were severe congestion and inflammation of conjunctiva along with muco-purulent ocular discharge. The expiratory grunts were audible in few cases. The auscultation of the lungs revealed respiratory sounds with rapid but shallow

*Corresponding author: rsharmaml@yahoo.com

respiratory rate. Occasionally some calves also showed irregular breathing pattern. The faeces of these animals had loose consistency, however, the urination was normal.

The representative tissue samples from the lungs and other body organs from all four dead calves were collected in 10% neutral-buffered formalin for histopathological studies. Fixed tissues were trimmed, embedded in paraffin, sectioned at 3-5 μ and stained with routine haematoxylin and eosin stain (Luna, 1968). Impression smears were prepared from the lung and other body tissues/fluid and fixed with methanol for subsequent staining using Giemsa and Gram's stains for identification of the pathogen.

RESULTS AND DISCUSSION

At necropsy, the massive frothy exudation was consistently seen in the trachea. Variable amount of serosanguineous exudation admixed with fibrin was also observed in the thoracic cavity. Lungs revealed generalized congestion along with massive haemorrhages. The interlobular septa were prominent, widened and massively filled with either fibrinous or fibrino-purulent exudation. The lesions were most severe in the cranial and middle lung lobes. On cut section, suppurative exudate oozing-out from small bronchi and bronchioles was evident. Other organs such as kidneys, spleen, liver, heart, lymph nodes, stomach and intestines revealed mild to moderate congestion or occasional haemorrhages.

Microscopically, tissue sections obtained from lungs revealed massive dilatation and engorged blood vasculature. The inter-alveolar spaces were completely filled with red blood cells. Numerous haemorrhages were observed in lung parenchyma. The alveolar spaces were diffusely filled with sero-fibrinous exudate admixed with neutrophils and red blood cells. Interlobular septa were thickened and markedly distended with fibrinous exudation. The alveoli and bronchioles were massively packed with variable proportions of neutrophils, macrophages, fibrin, exudation, erythrocytes and necrotic cellular debris (Fig. 1). Necrosis of intra-alveolar leukocytes mainly neutrophils leading to appearance of oat shaped inflammatory cells was conspicuous finding (Fig. 2). Tissue sections of kidneys, spleen, liver, heart, lymph nodes, and stomach and intestines revealed mild to moderate oedema admixed with fibrin. There was vascular congestion in these organs, however, haemorrhages were rarely observed in the parenchyma. The Gram's stained impression smears from lung and other body tissues/fluid revealed presence of characteristic bipolar gram negative bacteria.

The sick calves were isolated and taken care of with good management and feeding practices and were treated with antibiotics along with anti-inflammatory and supportive therapies in recommended doses for 5-7 days.

In domestic animals, *M. haemolytica* is responsible for causing various pathological conditions and respiratory disease is an important manifestation. Harsh climatic conditions, stocking density, onset of other viral or bacterial diseases act as predisposing

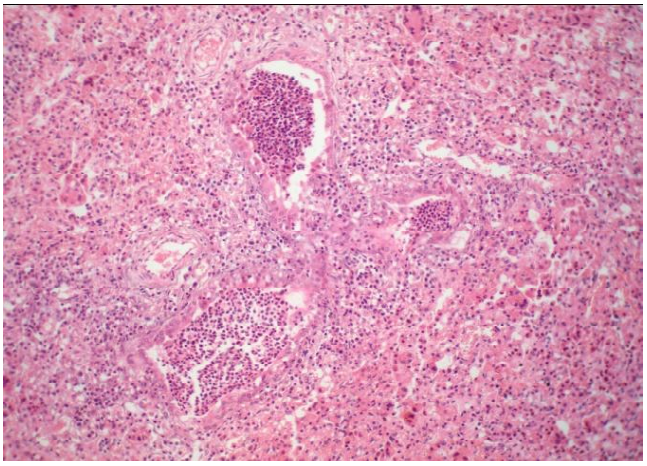

Fig 1. Photomicrograph from lung section of a calf showing bronchioles and alveoli densely packed with neutrophils. (H. & E. x 66)

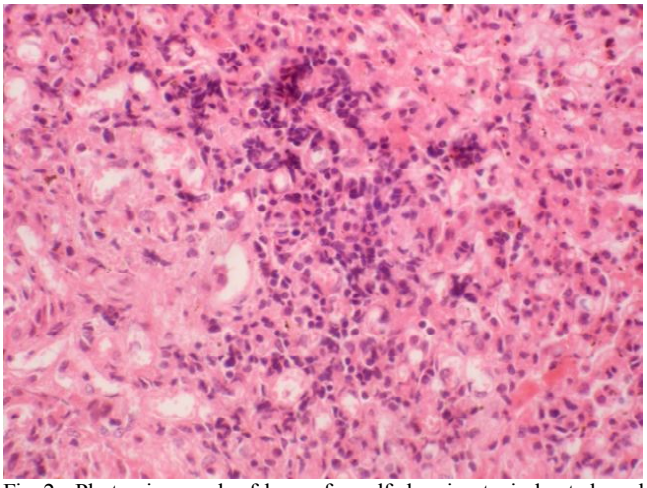

Fig 2. Photomicrograph of lung of a calf showing typical oat shaped inflammatory cells in the parenchyma. (H. & E. x 132)

factors. However, the manifestation of mannheimiosis is also reported without the involvement of any predisposing factor (Vestweber *et al.*, 1990). The manifestation of the disease occurs possibly due to the transfer of *Mannheimia* microorganisms from the nasopharynx into the lungs by draining along the trachea and settling into the bronchi, bronchioles and alveoli. This consequently results in release of *Mannheimia* endotoxins which infect lung lobules and causes thromboses along with occlusion of lymphatics, capillaries, and veins; thereby causing ischemic necrosis (Jensen *et al.*, 1976).

The cranio-ventral distribution of lesions, massive fibrinous/suppurative exudation, necrotic changes in lung parenchyma including necrosis of inflammatory leucocytes with the formation of characteristic oat shaped cells are strongly suggestive of pneumonic mannheimiosis (Maxie, 2007; Singh *et al.*, 2011). The present outbreak of disease was linked to pneumonic mannhaemiosis based on necropsy, histopathological examination and Gram's staining of impression smears. Necrosis of intra-alveolar leukocytes is a characteristic feature of infection with *M. haemolytica,* where leukotoxin is responsible for the neutrophil cell death and the necrotic leukocytes often exhibit oat shaped cells for their resemblance to grains of oats (Maxie, 2007). However, no attempts were made for isolations in the present study. But, presence of a sheep and goat farm merely hundred yards away from the cattle livestock farm raises concern about the strong possibility of transmission of disease among the ruminants. Delay in immediate treatment results in sick animals becoming chronically affected which means poor prognosis despite prolong therapy. The similarity of its clinical symptoms with those of other diseases would potentially mean chances of mistaken diagnosis. Therefore it is essential to quickly achieve to the specific diagnosis by conducting necropsy of the dead animals along with histopathological examination of the infected tissues such as lungs. Lung lesions generally consist of an acute to sub-acute fibrinous bronchopneumonia with or without an associated pleuritis (Dabo *et al.*, 2007). Thus, based on the gross, histopathological and stained impression smear examination along with relevance to clinical symptoms, the present outbreak was diagnosed as pneumonic mannheimiosis. Consequently effective preventive and therapeutic measures were adopted which helped in uneventful recovery of the sick calves and controlling the further spread of the disease.

REFERENCES

Adamu, J.Y. and Ameh, J.A. (2007). Pasteurellosis to mannheimiosis: Taxanomic changes. *Nigerian Vet. J.* **28**: 75-79.

Dabo M., Taylor, J.D. and Confer, A.W. (2007). *Pasteurella multocida* and bovine respiratory disease. *Anim. Hlth Res. Rev.* **8**: 129-150.

De Alwis M.C.L. (1992). Haemorrhagic septicaemia-a general review. *Br. Vet. J.* **148**: 99-112.

Jensen R., Pierson, R.E., Braddy P.M., Saari, D.A., Lauerman L.H., England, J.J., Keyvanfar, H., Collier, J.R., Horton, D.P., McChesney, A.E., Benitez, A. and Christie, R.M. (1976). Shipping fever pneumonia in yearling feedlot cattle. *J. Am. Vet. Med. Assoc.* **169**: 500-506.

Karimkhani, H., Zahraie Salehi, T., Sadeghi Zali, M.H., Karimkhani, M. and Lameyi, R. (2011). Isolation of *Pasteurella multocida* from cows and buffaloes in Urmia's slaughter house. *Arch. Razi Inst.* **66**: 37-41.

Kelly, A.P. and Janzen, E.D. (1986). A review of morbidity and mortality rates and disease occurrence in North American feedlot cattle. *Canadian Vet. J.* **27**: 496-500.

Luna, L.G. (1968). Manual of Histologic Staining Methods of the Armed Forces Institute of Pathology. (3rd edn.), McGraw Hill Book Company, New York.

Maxie, M.G. (2007). Jubb, Kennedy and Palmer's 'Pathology of Domestic Animals'. Volume-II. (5th edn.), Academic Press, New York.

Mohamed, R.A. and Addelsalam, E.B. (2008). A review on pneumonic pasteurellosis (respiratory mannheimiosis) with emphasis on pathogenesis, virulence mechanisms and predisposing factors. *Bulgarian J. Vet. Med.* **11**:139-160.

Singh, K., Ritchey, J.W. and Confer, A.W. (2011). *Mannheimia haemolytica* bacterial-host interactions in bovine pneumonia. *Vet. Pathol.* **48**: 338-348.

Vestweber, J.G., Klemm, R.D., Leipold, H.W., Johnson, D.E. and Bailie, W.E. (1990). Clinical and pathological studies of experimentally induced *Pasteurella haemolytica* pneumonia in calves. *Am. J. Vet. Res.* **51**: 1792-1798.