Haryana Vet. (Dec., 2014) **53 (2)**, 84-88

Research Article

THE ARTERIAL BLOOD SUPPLY OF THE FOOT OF THE NATIVE EGYPTIAN GOOSE (*ANSER ANSER DOMESTICUS*)

A.R. TOLBA* and S.M. DAGHASH
Anatomy and Embryology Department, Faculty of Veterinary Medicine
Cairo University, Cairo, Egypt

Received: 05.06.2014; Accepted: 21.09.2014

ABSTRACT

The present study was carried out on arterial supply of the foot in ten adult, healthy native Egyptian geese. Arteries were demonstrated by injection of coloured gum milk latex through the descending aorta and treated by the ordinary method of preservation. Foot received its arterial supply through the cranial tibial artery that gave two sets of arteries; dorsal and plantar. The dorsal set comprised the Rete tibiotarsale and A. metatarsalis dorsalis communis. The plantar set of arteries supplying the foot was derived from the Aa. intermetatarsales plantares and the plantar arch. Digital arteries arose from the latter arch except those of the 2nd digit and mostly the lateral artery of the 4th digit. Metatarsal pad was supplied by single pulvinar branch arising from either the plantar arch or common stem A. digitalis III lateralis and A. digitalis IV medialis. The interdigital web was supplied by fine transverse rami arising from the Aa. digitales III medialis and lateralis, A. digitalis II lateralis and A. digitalis IV medialis as well as a longitudinal branch arising from the later artery. These rami were anastomosed forming capillary network distributed all over the web.

Key words: Arterial supply, Egyptian goose, foot

Avian foot is subjected to many injuries; wounds, bumble foot, fibrosis and swelling of the metatarsal pad being the most common and may need surgical interference (Heidenreich, 1997; Cooper, 2002). On literature survey it was found that information about the arterial supply of foot region in goose was not adequate. On the other hand the arterial supply of the pelvic limb in birds has been outlined in domestic fowl (Mcleod *et al*., 1964; Koch, 1973; Baumel, 1975; Nickel *et al.*, 1977 and El-Gammal, 2012), quail (Fitzgerald, 1969; Can *et al.*, 2010), ostrich (El-Nahla *et al*., 2010) and other different domestic birds (Midtgard, 1981; Dursun, 2002). Therefore, the present study was performed for highlighting the arterial vascularization of the foot of native Egyptian goose.

MATERIALS AND METHODS

Present work was carried out on ten healthy domestic geese *(Anser anser domesticus)* weighing about 3.5 to 4 kg. Before exsanguinations, geese were anaesthetized by intramuscular injection of 0.5 cc of 2% xylazine hydrochloride to ensure proper relaxation and avoid vasoconstriction, then injected with heparin (Cal Heparin, 5000 I.U. diluted by 1-2 cm saline solution) through the wing vein. Each bird was exsanguinated through the common carotid arteries. Breast muscle and sternum were removed to expose the descending aorta through which a Nelaton catheter of size 8F to 10F was introduced just caudal to the heart. Injection approach comprised 60% latex neoprene coloured red with Rottring ink and the specimens were kept in 10% formalin, 4% phenol and 1% glycerin three days before dissection. Nomenclature used in this study was that given by the Baumel *et al.* (1993).

*Corresponding author: draymantolba@hotmail.com

RESULTS AND DISCUSSION

The arterial supply of the foot was from the cranial tibial artery (Fig. 1/2) that represented the continuation of the popliteal artery (Fig. 1/1) through the distal interosseous foramen (Fig. 1/a) between the tibiotarsus (Fig. 1/b) and fibula (Fig. 1/c). It descended along the cranial aspect of the tibiotarsus to its distal third and from here it detached 2-3 collateral branches that formed Rete tibiotarsale (Fig. 2/3) after which it continued distally as the A. metatarsalis dorsalis communis (Fig. 2/7).

Cranial tibial artery was the direct continuation of the popliteal artery and continued distally as common dorsal metatarsal artery. These observations are consistent with those of Mcleod *et al.* (1964), Baumel (1975) and Nickel *et al*. (1977) in domestic fowl, Can

et al. (2010) in Japanese quail and El-Nahla *et al*. (2010) in ostrich. However, Koch (1973) in the domestic fowl stated that the cranial tibial artery was divided proximal to the tarsal joint into two branches that supplied the toes.

The arterial architecture of the foot could be arranged into two sets i.e. dorsal and plantar.

I. The Dorsal Set: The dorsal set of arteries supplying the foot comprised the Rete tibiotarsale and A. metatarsalis dorsalis communis.

Rete tibiotarsale: The tibiotarsal rete (Fig. 2/3) were formed of multiple parallel vessels that located along the distal end of the cranial surface of the tibiotarsus, the flexor surface of the tarsus (Fig. 2/d) as well as the proximal end of the tarsometatarsus. These vessels comprised the collateral branches arising from the distal third of the cranial tibial (Fig. 1/2), deep fibular (Fig.1/5), superficial fibular (Fig.1/6) and lateral sural (Fig.1/14) arteries. They branched and re-united with cranial tibial artery that continued distally beyond this rete as the common dorsal metatarsal artery.

Similar observations with regard to Rete tibiotarsale were recorded by Fitzgerald (1969), Midtgard (1981) and Dursun (2002) in birds. Whereas, Baumel (1975), El-Gammal (2012) and Swielim *et al*. (2012) did not mention the fibular and lateral sural arteries as a component of this rete in domestic fowl and added that it was differentiated into two retae; Rete tibialis cranialis, proximal to the tarsal joint and Rete tarsi dorsalis, distal to this joint.

A. metatarsalis dorsalis communis: The common dorsal metatarsal artery (Fig.2/7) descended along the flexor surface of the tarsus, under the transverse ligaments of the tarsometatarsus. On reaching the level of the proximal vascular foramen (Fig. 2/f) of the tarsometatarsus, it gave of the Aa. tarseae plantares and was then divided into two branches; the medial and lateral dorsal metatarsal arteries.

A. metatarsalis dorsalis medialis: The medial dorsal metatarsal artery (Fig. 2 and 5/8) was the smaller of the two vessels and descended along the dorsomedial aspect of the tarsometatarsus, passed through the medial intertrochlear notch (Fig. 2 and 3/j) and terminated in between the metatarsophalangeal articulations of the 2nd and 3rd phalanx. It divided into the Aa. digitales II lateralis and Aa. digitales III medialis. Along its course it detached fine branches that supplied the tendon of the M. extensor digitorum communis, M. extensor proprius digiti III and M. extensor hallucis longus.

A. metatarsalis dorsalis lateralis: The lateral dorsal metatarsal artery (Fig. 2 and 5/9) was the larger of the two vessels and descended along the dorsal aspect of the tarsometatarsus and gave off branches supplying the tendon of the M. extensor digitorum communis as well as the M. extensor proprius digiti III and Mm. extensor breves digiti III and IV. The lateral dorsal metatarsal artery then passed through the distal vascular foramen (Fig.2 and 3/h) to join the planter arch.

II. The Plantar Set: The plantar set of arteries supplying the foot was derived from Aa. tarseae plantares and the plantar arch.

Aa. intermetatarsales plantares: Medial (Fig. 2 and 3/10) and lateral (Fig. 3/11) plantar intermetatarsal arteries were given off from the common dorsal metatarsal artery on the level of the proximal vascular foramina (Fig. 2 and 3/f) of the tarsometatarsus. Each of these vessels pierced through the corresponding proximal vascular foramen of the tarsometatarsus and gained the plantar aspect where it soon divided into two branches; an ascending or recurrent branch and a descending branch. Both ascending branches; represented the Aa. tarsales plantares, medialis (Fig. 2 and 3/12) and lateralis (Fig. 3/13) which extended proximally along the corresponding aspect of the tarsus, where it detaches fine articular branches to that joint and cutaneous branches supplying the skin on either side of the joint and then anastomosed with the corresponding medial (Fig. 1/15) and lateral (Fig. 1/16) branches of the A. suralis lateralis (Fig. 1/14). The descending branches were extended distally as the Aa. metatarsales plantares.

Aa. metatarsales plantares: Medial (Fig. 2 and 3/17) and lateral (Fig. 3/18) plantar metatarsal arteries extended distally, giving several small branches to the M. flexor hallucis longus and M. flexor digitorum longus as well as the tendon of the M. flexor digitorum profoundes and M. flexor digitorum superficialis. Two vessels were connected through 1-2 transverse communicating branches (Fig. 3/19) and terminated by joining the emerged lateral dorsal metatarsal artery through the distal vascular foramen to form the plantar arch.

Common dorsal metatarsal artery gave off the medial and lateral plantar intermetatarsal arteries which gave rise to the medial and lateral dorsal metatarsal arteries. On the other hand, Mcleod *et al.* (1964), Baumel (1975), Nickel *et al.* (1977), Baumel *et al.* (1993), El-Gammal (2012) and Swielim *et al*. (2012) in

the domestic fowl and El-Nahla *et al.* (2010) in ostrich reported that the common dorsal metatarsal artery terminated at the base of the digits by forming the digital arteries. Mcleod *et al*. (1964) added that the lateral dorsal metatarsal artery in duck pierced through the distal vascular foramen of the tarsometatarsus to join the plantar arch, in similitude to the distal perforating branch described by Ghoshal (1975) in the domestic animals.

Arcus plantaris: Plantar arch (Fig. 3/20) was formed by the communication between the plantar metatarsal arteries with the lateral dorsal metatarsal artery and was located on the deep face of the common digital flexor tendon just proximal to the metatarsophalangeal articulations and it detached the pulvinar branch and most of the digital arteries.

R. Pulvinaris: Pulvinar branch (Fig. 4/21) arose from the plantar arch. In five specimens it was given from the common stem of A. digitalis III lateralis and A. digitalis IV medialis. It entered the medial aspect of the metatarsal pad (Fig. 4/i) where it ramified into 2-3 branches**.**

Aa. digitales: Each digit was supplied by two arteries medial and lateral, except the 1st digit which was supplied by single artery extending on its plantar side. All digital arteries arose from the plantar arch except the lateral artery of the 2nd digit and the 4th digit.

A. digitalis I: Digital I artery (Fig. 2, 3, 4 and 5/22) arose from the medial side of the plantar arch and extended along the plantar aspect of the first digit.

Aa. digitales II medialis and Aa. digitales III medialis: Medial digital II artery (Fig. 3 and 4/23) and the medial digital III artery (Fig. 2, 3,4 and 5/25) originated by common stem from the plantar arch. This stem passed deep to the metatarsal pad, then bifurcated to give the medial digital II artery along the medial aspect of the 2nd digit. While the medial digital III artery joins the lateral bifurcation (Fig. 2 and 3/25') of the medial dorsal metatarsal artery (from the dorsal set) and extended along the medial aspect of the 3rd digit.

Aa. digitales II lateralis: Lateral digital II artery (Fig. 2 and 5/24) originated as the medial bifurcation of the medial dorsal metatarsal artery. It passed through the medial intertrochlear notch (Fig. 2 and 3 /j). The lateral digital II artery extended along the lateral aspect of the 2nd digit.

A. digitalis III lateralis and A. digitalis IV medialis: Lateral digital III artery (Fig. 3, 4 and 5/26) and the medial digital IV artery (Fig. 3, 4 and 5/27) arose by common stem from the plantar arch. This stem passed through the lateral intertrochlear notch (Fig. 2 and 3/k) deep to the metatarsal pad, giving fine twigs to this pad, then bifurcated to give the latter two vessels that extended along the lateral aspect of the 3rd digit and the medial side of the 4th digit, respectively.

A. digitales IV lateralis: Lateral digital IV artery (Fig. 3 and 4/28) was detached independently from the lateral plantar metatarsal artery just before it joined the plantar arch. It descended alongside the lateral aspect of the 4th digit.

Along their course, the digital arteries gave off fine branches that distributed dorsally to the digital extensor tendons and plantarly to the digital flexor tendons. Moreover, transverse anastomotic branches (Fig. 3 and 4/29) were observed between the medial and lateral digital arteries of the same digit on both dorsal and plantar aspects just distal to the interphalangeal articulations. Digital arteries of each digit were also communicated at the end of the digit, on the plantar aspect of the 3rd phalanx (Fig. 3, 4 and 5/q) forming a sort of terminal arch (Fig. 3 and 4/30).

Arterial supply of the interdigital (foot) web was achieved through numerous transverse rami (Fig. 2 and 5/31) arising from the A. digitalis II lateralis and Aa. digitales III medialis and ramified throughout the tela interdigitalis medialis (Fig. 2 and 5/n). Similar branches arose from A. digitalis III lateralis and A. digitalis IV medialis and ramified throughout the tela interdigitalis lateralis (Fig. 2 and 5/o). These rami were anastomosed forming a plentiful arterial rete that distributed all over the foot web. Moreover, a longitudinal branch (Fig. 2, 3, 4 and 5/32) was detached from A. digitalis IV medialis and extended distally across the tela interdigitalis lateralis towards its free margin.

In the domestic goose, medial and lateral plantar intermetatarsal arteries were given off from the common dorsal metatarsal artery on the dorsal aspect of the proximal end of the tarsometatarsus similar to that recorded by Baumel (1975), Baumel *et al.* (1993) in the domestic fowl. On the other hand, El-Gammal (2012) and Swielim *et al.* (2012) mentioned that in the domestic fowl, the corresponding vessels arose from the Rete tarsi dorsalis. On reaching the plantar aspect each of these vessels was soon divided into two branches; an ascending and a descending branch, the same was

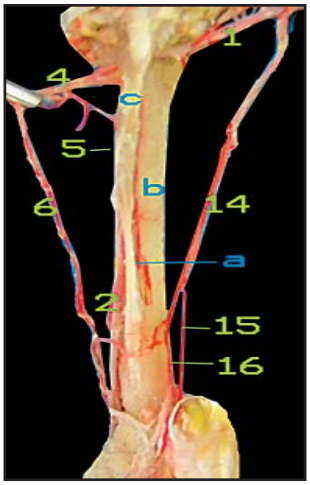

Fig 1. Photograph of left leg region of a goose showing arteries forming the Rete tibiotarsale (lateral view)

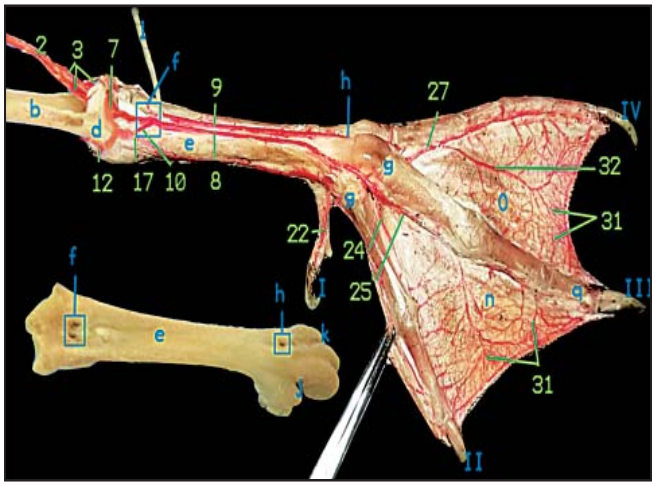

Fig 2. Photograph showing arteries of left shank and foot of a goose (dorsomedial view). The common digital extensor tendon was reflected.

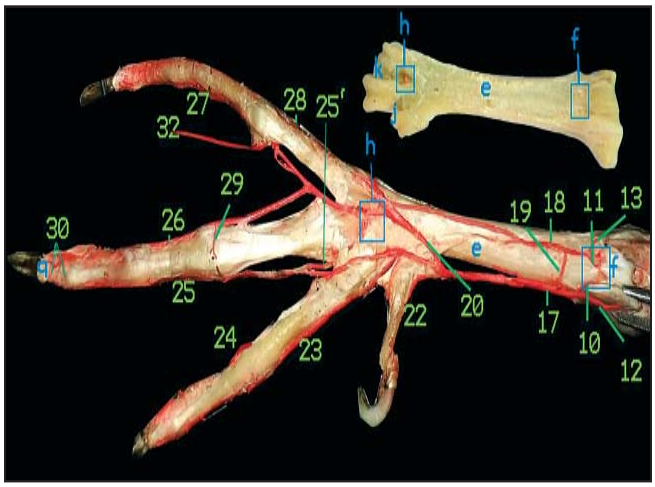

Fig 3. Photograph showing arteries of left shank, foot and tibiotarsus of a goose (plantar view). The digital flexor tendons were removed.

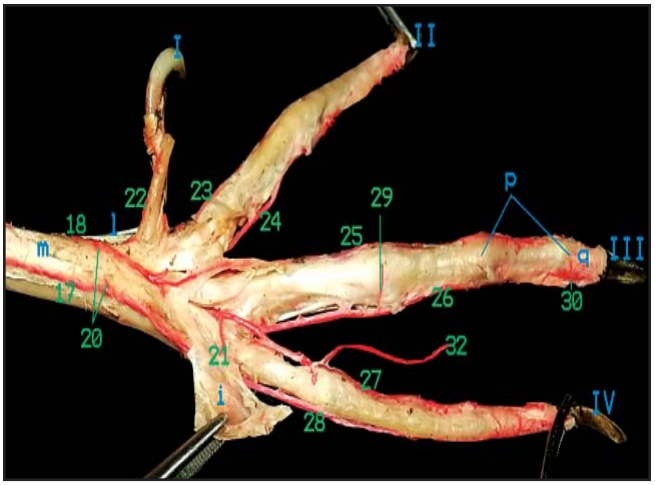

Fig 4. Photograph showing arteries of right foot of a goose (lateral view). The metatarsal pad was reflected.

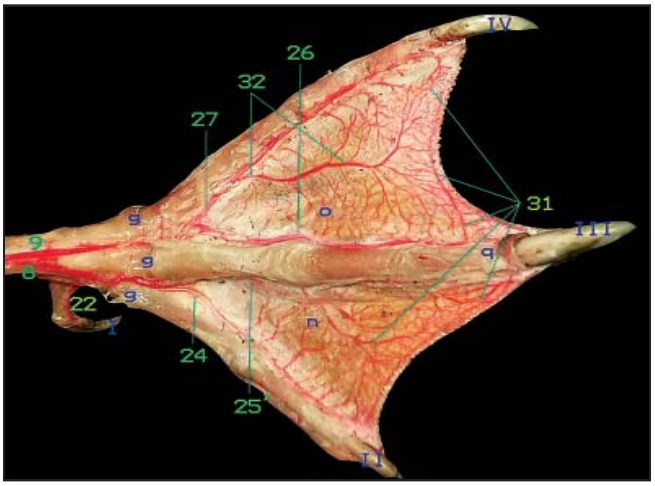

Fig 5. Photograph showing arteries of left foot of a goose (dorsal view of a dissected specimen).

Legend for the figures

1. A. poplitea
2. A. tibialis cranialis
3. Rete tibiotarsale
4. A. fibularis
5. A. fibularis profundus.
6. A. fibularis superficialis
7. A. metatarsalis dorsalis communis
8. A. metatarsalis dorsalis medialis
9. A. metatarsalis dorsalis lateralis
10. A. intermetatarsalis plantaris medialis.
11. A. intermetatarsalis plantaris lateralis.
12. A. tarsalis plantaris medialis.
13. A. tarsalis plantaris lateralis
14. A. suralis lateralis
15. R. medialis of 13
16. R. lateralis of 13
17. A. metatarsalis plantaris medialis
18. A. metatarsalis plantaris lateralis
19. Rr. communicans
20. Arcus plantaris
21. R. Pulvinaris
22. A. digitalis I
23. A. digitalis II medialis
24. A. digitalis II lateralis
25. A. digitalis III medialis

25'. Lateral Bifurcation of 8
26. A. digitalis III lateralis
27. A. digitalis IV medialis
28. A. digitalis IV lateralis
29. anastomotic branches
30. Arcus terminalis
31. Transverse branches
32. Longitudinal branch

a) Distal interosseous foramen
b) Tibiotarsus
c) Fibula
d) Tarsus
e) Tarsometatarsus
f) Proximal vascular foramen
g) Metatarsophalangeal articulation
h) Distal vascular foramen
i) Pulvinus metatarsalis.
j) Medial intertrochlear notch
k) Lateral intertrochlear notch
l) Common digital extensor tendon
m) Superficial digital fLexor tendon
n) Tela interdigitalis medialis
o) Tela interdigitalis lateralis
p) Pulvinus digitalis
q) Phalanx ungualis (terminalis).

recorded by El-Gammal (2012) and Swielim *et al.* (2012) in the domestic fowl. The present study revealed that each digit was supplied by two arteries medial and lateral, except the 1st digit was supplied by single artery.

In domestic fowl, El-Gammal (2012) and Swielim *et al.* (2012) revealed that the plantar arterial arch gave off the medial and lateral digital I, medial digital II, medial digital III and the lateral digital IV arteries, the medial dorsal metatarsal artery detached the lateral digit II artery, while the lateral dorsal metatarsal artery gave both lateral digital III artery and medial digital IV artery while Nickel *et al.* (1977) in the domestic fowl, mentioned that the first, second and fourth digits are supplied by one digital artery for each, whereas the third digit was supplied by two digital arteries. Digital arteries of the first and second digits and the medial digital artery of the third digit originated from the plantar arterial arch, whereas the lateral digital artery of the third digit and the digital artery of the fourth digit arose directly from the lateral metatarsal artery.

Plenty of arterial supply to the interdigital (foot) web of the geese as revealed in the present study explained its thermoregulatory mechanism as recorded by Kardong (2008) who mentioned that retia mirabilia in the legs and feet of birds transfer heat from the outgoing (hot) blood in the arteries to the incoming (cold) blood in the veins. The effect of this biological heat exchanger is that the internal temperature of the feet is much closer to the ambient external temperature, thus physiologically reducing heat loss.

The metatarsal pad was supplied by R. pulvinaris According to Baumel (1975,) and Nickel *et al.* (1977) in the domestic fowl, the pulvinar artery arose from the common dorsal metatarsal artery and passed through the distal foramen of the tarsometatarsus.

REFERENCES

Baumel, J.J. (1975). Aves Heart and Blood Vessels. In: The Anatomy of the Domestic Animals. Getty, R., Sisson, S. and Grossman's, J.D. (edts.). (5th edn.), W.B. Saunders Co., Philadelphia, PA, USA.

Baumel, J.J., King, A.S., Lucas, A.M. Breazile, J.E. and Evans, H.E. (1993). Systema Cardiovasculare. In: Nomina Anatomica Avium. Baumel, J.J., King, A.S., Lucas, A.M., Breazile, J.E. and Evans, H.E. (edts). Houghton Mifflin Co., London, UK.

Can, M, Ozudogru, Z. and Ozdemir, D. (2010). Arterial vascularization of the hind limb muscles in the Japanese quail (*Countrix countrix japonica*). *J. Anim. Vet. Adv.* **9(17):** 2265-2270.

Cooper, J.E. (2002). Birds of Prey. Health and Disease. Blackwell Science, Oxford.

Dursun, N., (2002). Evcil Kuslarin Anatomisi. Ankara Universitesi Veteriner Fakultesi, Ders Kitaplari, Ankara Universitesi Basimevi, Ankara.

El-Gammal, S. (2012). Anatomical studies on the blood supply of the pelvic limb of the chicken, with special reference to the renal portal system and renal elimination of some drugs. M.V.Sc. thesis. Fac. Vet. Med. Cairo Univ, Cairo.

El-Nahla, S.M., El-Mahdy, T., Abbott, L.C. and Hassan, S.A.M. (2010). The arterial supply of the pelvic limb of the adult ostrich (*Sturthio camelus*). *Anat. Histol. Embryol*. **39(4):** 339-354.

Fitzgerald, T.C. (1969). The Coturnix Quail, Anatomy and Histology. Iowa State University Press, Ames, Iowa.

Goshal, N.G. (1975). Heart and arteries of domestic animals. In: The Anatomy of the Domestic Animals. Getty, R., Sisson, S. and Grossman's, J.D. (edts.) (5th edn.). W.B. Saunders Co. Philadelphia, PA, USA.

Heidenreich, M. (1997). Birds of Prey: Medicine and Management. Malden, M.A. Blackwell Science, Oxford.

Kardong, K. (2008). Vertebrates: Comparative Anatomy, Function, Evolution. (5th edn.). McGraw-Hill, Boston.

Koch, T. (1973). Anatomy of Chicken and Domestic Birds. Translated from the German manuscript by B. H. Skold and L. Devries. Ames, IA, USA, The Iowa State University Press.

Mcleod, W.M., Trotter, D.M. and Lumb, J.W. (1964). Avian Anatomy. Minneapolis, Burgess Publishing Co . USA.

Midtgard, U. (1981). Patterns in the blood vascular system in the pelvic limb of birds. *J. Zoo*. **196(4):** 544-567.

Nickel, R., Schummer, A. and Seiferle, E. (1977). Anatomy of the Domestic Birds. (1st edn.) Berlin Hamburg, Verlag Paul Parey.

Swielim, G.A., Khlifa, E.F. and El-Gammal, S.M. (2012). Anatomical studies on the arterial blood supply of the pelvic limb of chicken. *Suez. Canal. Vet. Med. J.* **17 (2):** 171-190.