Haryana Vet. (June, 2015) **54 (1)**, 89-90

Clinical Article

CUTANEOUS HAEMANGIOMA IN A DOG- A CASE REPORT

DEEPIKA LATHER[1], VIKAS NEHRA[1]*, R.P. GUPTA[1], K.K. JAKHAR[1]
DIVYA AGNIHOTRI[2] and R.N. CHAUDHARY[2]
[1]Department of Veterinary Pathology
[2]Teaching Veterinary Clinical Complex, College of Veterinary Sciences, Lala Lajpat Rai University of Veterinary and Animal Sciences, Hisar-125 004, India

Received: 18.11.2014; Accepted: 29.01.2015

SUMMARY

A case of cutaneous swelling in a Labrador dog was presented with abnormal red coloured mass at the skin surface on left flank abdominal region. Histopathological examination of the mass revealed an unencapsulated, poorly demarcated large area of endothelial-lined blood vessels within a connective tissue stroma. Neoplastic endothelial cells were single layered, appeared flattened with scanty eosinophilic cytoplasm and had oval nuclei containing finely stippled chromatin and central nucleoli. There was moderate anisocytosis and anisokaryosis with few mitotic figures. In dogs, genetics and solar radiation are the contributing factors in the development of several skin neoplasms including haemangiomas and haemangiosarcomas. Because of the involvement of vascular endothelium such tumors can lead to serious deleterious effects. Haemostatic defects due to vascular tumors included haemorrhage directly from the tumor, thrombocytopenia, hypofibrinogenemia, and disseminated intravascular coagulation.

Keywords: Cutaneous haemangioma, dog, mitotic figures

Spontaneous tumors of endothelial cells of blood vessels have been found commonly in dog, less frequently in felines and equines, and sporadically in other domestic animals (Goldschmidt and Hendrick, 2002). Neoplastic tumors of the skin are common in canines (Scott and Paradis, 1990; Hill, *et al*., 2006). In dog, haemangiomas are typically benign, solitary, deep dermal tumors, whereas haemangiosarcomas are often present as a disseminated malignancy involving the spleen, heart, lung, liver, soft tissues of the trunk and extremities (Cooley *et al.*, 1997). In dogs, cutaneous haemangiomas are common as compared to primary canine cutaneous haemangiosarcomas (Hargis *et al.*, 1992). Haemangiomas occur more frequently in younger dogs.

A case of cutaneous swelling in a Labrador dog was presented to the Teaching Veterinary Clinical Complex, Lala Lajpat Rai University of Veterinary and Animal Sciences, Hisar with abnormal red coloured mass at the skin surface on left flank abdominal region. Representative tissue was collected by the excision biopsy in 10% buffered formalin, processed, and stained by Haematoxylin & Eosin staining technique (Luna, 1968). Histopathological examination of the tissue revealed unencapsulated, poorly demarcated large areas of endothelial-lined blood vessels within connective tissue collagenous stroma (Fig. 1). Neoplastic endothelial cells were single layered, appeared flattened with scanty eosinophilic cytoplasm and had oval nuclei containing finely stippled chromatin and central nucleoli (Fig. 2). There was moderate anisocytosis and anisokaryosis with few mitotic figures. These changes suggested the case to be of cutaneous haemangioma. According to the WHO classification of tumors of vascular tissue (Hendrick *et al.*, 1998), haemangiomas are well-circumscribed tumors consisting of vascular channels lined by well differentiated cells, whereas, locally infiltrative lesions with irregular vascular channels were classified as hemangiosarcomas.

Skin in dogs is the most commonly affected organ for both neoplastic and non-neoplastic tumors (Murphy, 2006; Bronden *et al.*, 2010). Although geographic differences for the types and frequencies of cutaneous vascular tumors in dogs are recognized; the reasons for these differences are not well understood. For some types of cutaneous tumors it is likely that both climate and the breeds of dogs in respective locations play an important role. In dogs it is now generally accepted that solar radiation is a contributing factor in the development of several skin neoplasms including haemangiomas and haemangiosarcomas (Hargis *et al.*, 1992; Hendrick *et al.*, 1998; Gross *et al*., 2005). Genetics should also be considered as a possible risk factor for these vascular skin tumors in dogs, as inherited forms of cutaneous angiomatosis in humans have been documented (Brouillard and Vikkula, 2007). In dogs there is a breed predisposition for scrotal vascular haematomas (Goldschmidt and Hendrick, 2002). Because of the involvement of vascular

*Corresponding author: drvikasnehra@gmail.com

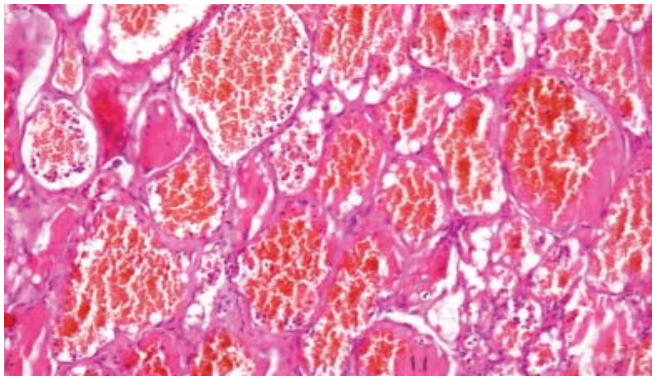

Fig 1. Haemangioma: Large areas of endothelial-lined blood vessels present within a connective tissue collagenous stroma H & E ×200

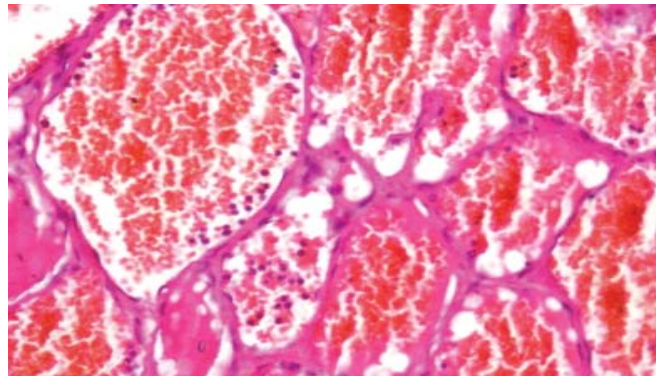

Fig 2. Haemangioma: Single layered flattened neoplastic endothelial cells in slit like sheets with scanty eosinophilic cytoplasm and oval nuclei H & E ×400

endothelium such tumors can lead to serious deleterious effects. Haemostatic defects due to vascular tumors included hemorrhage directly from the tumor, thrombocytopenia, hypofibrinogenemia, and disseminated intravascular coagulation (Hargis and Feldman, 1991).

REFERENCES

Bronden, L.B., Eriksen, T. and Kristensen, A.T. (2010). Mast cell tumours and other skin neoplasia in Danish dogs-data from the Danish veterinary cancer registry. *Acta Vet. Scand*. **52**: 6.

Brouillard, P. and Vikkula M. (2007). Genetic causes of vascular malformations. *Human Mol. Genet*. **16**: 40-149.

Cooley, D.M., Allen, D.K. and Waters D.J. (1997). Vascular neoplasms of dogs. *Kleintierpraxis* **42**: 859-870.

Goldschmidt, M. H. and Hendrick, M.J. (2002). Tumors of Skin and Soft Tissues. *In:* Tumors in Domestic Animals. Meuten, D.J. (edts.) (4th edn.). Iowa State Press, Ames, IA.

Gross, T.L., Ihrke, J.P. and Walder, E.J. (2005). Neoplasms and Other Tumors. In: Skin Diseases of the Dog and Cat: Clinical and Histopathologic Diagnosis. (2nd edn.). Blackwell Science, UK.

Hargis, A.M. and Feldman, B.F. (1991). Evaluation of hemostatic defects secondary to vascular tumors in dogs: 11 cases (1983-1988). *J. American Vet. Med. Assoc.* **198(5)**: 891-894.

Hargis, A.M., Ihrke, P.J., Spangler, P.J. and Stannard A.A. (1992). A retrospective clinicopathologic study of 212 dogs with cutaneous hemangiomas and hemangiosarcomas. *Vet. Pathol*. **29(4)**: 316-328.

Hendrick, M.J., Mahaffey, E.A. and Moore, F.M. (1998). Histological classification of mesenchymal tumors of skin and soft tissues of domestic animals. In: World Health Organization International Classification of Tumors in Domestic Animals (Vol. 2 series 2), Armed Force Institute of Pathology, Washington, DC, USA.

Hill, P.B., Lo, A. and Eden, C.A.N. (2006). Survey of the prevalence, diagnosis and treatment of dermatological conditions in small animals in general practice. *Vet. Rec.* **158(16)**: 533-539.

Luna, L.G. (1968). Manual of Histologic Staining Methods of the Armed Forces Institute of Pathology. (3rd edn.), McGraw Hill Book Co., New York.

Murphy, S. (2006). Skin neoplasia in small animals. Common canine tumours. *Practice* **28(7)**: 398-402.

Scott, D.W. and Paradis, M. (1990). A survey of canine and feline skin disorders seen in a university practice. *Canadian Vet. J.* **31(12)**: 830-835.