Haryana Vet. (December, 2016) **55 (2)**, 176-178

Research Article

COMPARATIVE STUDY OF ECHOGENICITY OF FETAL FLUID IN NORMAL AND UTERINE TORSION AFFECTED BUFFALOES

DEVENDER[1]*, R.K. CHANDOLIA[1], GYAN SINGH[2], A.K. PANDEY[2] and SONU KUMARI[3]
[1]Department of Veterinary Gynaecology and Obstetrics, [2]Teaching Veterinary Clinical Complex, College of Veterinary Sciences, [3]Regional Centre, Uchani (Karnal)
Lala Lajpat Rai University of Veterinary and Animal Sciences, Hisar-125 004, India

Received: 15.07.2016; Accepted: 19.11.2016

ABSTRACT

The present study was conducted on 20 clinical cases of advance pregnant buffaloes suffering from uterine torsion to measure the mean pixel values of fetal fluids ultrasonographically and to compare with normal advance pregnant buffaloes. The lower ventral area just lateral to linea alba (on both sides of the udder) in standing animals was scanned trans-abdominally by 2 Dimensional (2D) convex transducer and trans-rectally by linear array transducer for ultrasonographic images of fetal fluid. The data collected were statistically analyzed. The study revealed that the mean pixel values of fetal fluids in uterine torsion cases were significantly higher ($P<0.05$) than the normal advance pregnant buffaloes. Additionally, mean pixel values measured by trans-abdominal ultrasonography were significantly higher ($P<0.05$) than the pixel values measured by trans-rectal ultrasonography both in normal advance pregnant and uterine torsion affected buffaloes. These observations could be useful in determining the duration and severity of uterine torsion cases at the time of presentation of case to a veterinarian. This will also help in determining prognosis of the uterine torsion cases before going for further manipulations.

Key words: Buffaloes, pixel value, trans-abdominal, ultrasonography, uterine torsion

Uterine torsion or rotation of gravid horn on its longitudinal axis (Purohit *et al*., 2011) inflicts heavy economic losses to farmers due to death of fetus, dam or both and also lead to reduced milk yield. Uterine torsion has been reported as one of the serious cause of dystocia in buffaloes (Murty *et al*., 1999; Nanda *et al*., 2003; Amin *et al*., 2011). Unrelieved torsion is likely to be followed by hemorrhagic infarction as the degree of arterial occlusion or compression progresses (Noakes *et al*., 2009). Therefore, early and definite diagnosis of torsion can prevent irreversible damage of the uterus and might contribute to conservative treatment, which might spare the life of the dam and the fetus (Frazer *et al*., 1996).

It has been reported that the amniotic fluid appeared as a hypoechoic fluid with various amounts of echoic particles (Jonker, 2004). The allantoic fluid is the most important fetal fluid in bovine pregnancy. It is easily recognized since its echogenicity is lower than the amniotic fluid. The echogenicity of the allantoic fluid slowly increases during the pregnancy (Jonker, 2004; Kohan-Gadr *et al*., 2008). Till date, lot of studies have been carried out regarding biochemical, haematological and other stress parameters to evaluate the status of fetus and uterus in uterine torsion affected buffaloes. However, study regarding ultrasonographic assessment of fetal fluids is still lacking. Consequently, there is failure to predict the prognosis of fetus and dam in uterine torsion affected buffaloes, and advanced tools like ultrasonography might be useful in solving the problem. So, the present study was envisaged with the objective to measure mean pixel values of fetal fluids ultrasonographically in uterine torsion cases and compare them with the normal advance pregnant buffaloes.

*Corresponding author: devdhanda27@gmail.com

MATERIALS AND METHODS

The study was conducted in the Teaching Veterinary Clinical Complex (TVCC) with the collaboration of the Department of Livestock Production and Management of this university. Twenty clinical cases of uterine torsion in advance pregnant buffaloes were studied for ultrasonographic imaging and compared with twenty normal advance pregnant buffaloes (control group). The animals were admitted to the TVCC with the history of no progress in the parturition process or because of a general problem like colic, straining, reduced feed intake in late pregnant buffaloes (mostly between 8th and 10th month of pregnancy).

The case history for each animal was recorded in history sheet which included the age of the animal, parity, stage of gestation, duration of the condition, and previous

intervention and its nature. Diagnosis of uterine torsion was done by careful rectal and vaginal examinations after checking the broad ligament status. Uterine torsion having degree ≤180 was classified as light degree and the one having degree greater than 180 was classified as high degree uterine torsion arbitrarily, solely on the basis of manual judgment. Only those clinical cases of uterine torsion were considered for study which were fresh and have not been rolled previously in field for correction of uterine torsion. Most of the times, owners were unaware of duration of uterine torsion. Accordingly, the same was not considered in the present study.

A high quality ultrasound machine (SonoScape S6/S6Pro/S6BW; Portable Digital Color Doppler Ultrasound) equipped with 2D convex transducer having switchable frequency between 2.0-5.0 MHz designed for trans-abdominal approach was used for ultrasonographic imaging of fetal fluids. The lower ventral area just lateral to linea alba (on both sides of the udder) (Fig. 1) was shaved and coupling gel was applied to take ultrasonographic images. Proper shaving of site helped in proper imaging. Trans-rectal ultrasonography employed linear array transducer having frequency between 5.0-7.5 MHz to image fetal fluids. Pixel values were measured in "adobe photoshop" computer software. Minimum 3 to 4 areas for each image were selected to measure the mean pixel values of allantoic fluids. A particular area of image was selected and then clicked on "edit" and "histogram" to get the mean value. The ultrasound images recorded in the machine were reviewed in the scanner itself to re-examine the images in detail. The data collected were statistically analyzed for finding out average mean and standard error. Independent sample t-test was employed using computerized SPSS 16.0 software program. Differences at a $P<0.05$ were considered to be statistically significant.

Fig 1. Site and probe positioning for transabdominal ultrasonography in buffaloes

RESULTS AND DISCUSSION

In normal advance pregnant buffaloes, allantoic fluids appeared completely anechoic whereas in uterine torsion affected buffaloes, allantoic fluid has various amount of echoic particles (Fig. 2). In buffaloes with uterine torsion, the amniotic fluid (Fig. 3) appeared as a hypoechoic fluid with various amounts of echoic particles. The allantoic fluid appeared as an anechoic media (Fig. 3). Both fetal fluids were separated by a thin hyperechoic membrane which was the amniotic membrane (Fig. 3).

After taking sonographic image of fetal fluid in clinical cases of uterine torsion and control group buffaloes, mean pixel values were measured. It was observed that the mean pixel values of fetal fluids (allantoic fluid) in uterine torsion cases (Table 1) were significantly higher ($P<0.05$) than the normal advance pregnant buffaloes. Mean pixel values measured by trans-abdominal ultrasonography were significantly higher ($P<0.05$) than the pixel values measured by trans-rectal ultrasonography both in normal advance pregnant and uterine torsion affected buffaloes (Table 1).

Compared to the allantoic fluid, the echogenicity of the amniotic fluid was higher in normal as well as in uterine torsion affected buffaloes during advance gestation. This was reflected in higher mean pixel values. In the current study, mean pixel values (echogenicity) of fetal fluids were found increased in uterine torsion affected buffaloes. Previously, increase in echogenicity of fetal fluid in mare has been attributed to the passage of meconium *in utero*, hemorrhage, or inflammatory debris and that might reflect fetal hypoxia, placental detachment or placenta1 infection (Vaala and Sertich, 1994). The

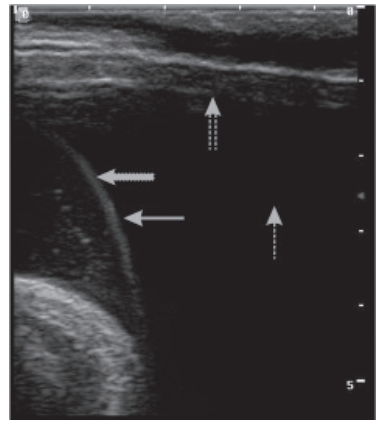

Fig 2. Trans-rectal sonographic image of fetal fluids in normal advance pregnant buffalo. In this image dotted double line, dotted single line, solid double line and solid single line arrow represents the uterine wall, allantoic fluid, amniotic fluid and amniotic membrane, respectively

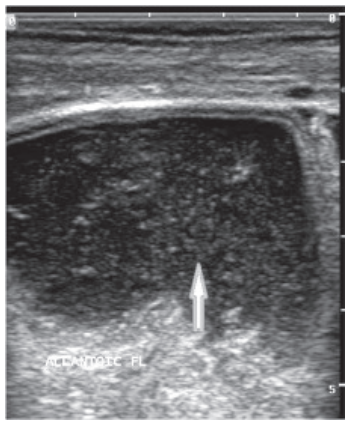

Fig 3. Trans-rectal ultrasonographic image of fetal fluids (shown by arrow) in buffalo having right side post cervical uterine torsion (greater than 180 degree). Various amount of echoic particles were observed in the fetal fluid

increase in echogenicity in the present study was comparable to the study done by other workers in different species (Sertich, 1993; Vaala and Sertich, 1994). The study revealed marginal increase in echogenicity after rolling the buffalo for correction of uterine torsion which might be attributed to redistribution of particles in the fetal fluids during rolling. Moreover, the trans-abdominal images for measuring mean pixel values are likely to be of inferior quality than images obtained by trans-rectal ultrasonography. Comparable findings were reported by Renaudin *et al*. (1997) in mares. This difference in quality of images might be due to the fact that trans-rectal ultrasonographic beams do not travel too far and take only the image of upper clear fetal fluid while trans-abdominal ultrasonography takes images of bottom or lower side fetal fluids which might have more particles.

Whenever a case of uterine torsion is presented, it is of utmost importance for a veterinarian to determine the prognosis of the case before going for further manipulations. From the present study, it could be possible to assess the condition of fetal fluids at the time of presentation of uterine torsion cases by measuring pixel values with the help of ultrasonography. This finding could be useful asset in determining the duration and severity of uterine torsion cases. This will also help in determining prognosis of the uterine torsion cases before going for further manipulations. It could be possible to visualize inflammatory changes in fetal fluid (by measuring pixel values) by ultrasonography in uterine torsion affected buffaloes. Till date, information regarding pixel values of fetal fluids in buffaloes suffering from uterine torsion is lacking which can make an error in judging the prognosis of the case. Hence, by assessing the ultrasonographic images of fetal fluids for pixel values, it could be possible to assess the prognosis of clinical case of uterine torsion in more efficient manner.

Table 1

Ultrasonographic measurement of mean pixel values of fetal fluids in control and uterine torsion affected buffaloes

Groups	Per-rectally	Trans-abdominally
Control group	0.61 ± 0.23^{a}	19.58 ± 1.12^{a}
Uterine torsion	8.55 ± 1.85^{b}	29.49 ± 2.52^{b}

Means with different superscript in a column indicate significant difference at $P<0.05$.

REFERENCES

Amin, S.M., Amer, H.A., Hussein, A.E. and Hazzaa, A.M. (2011). Creatine phosphokinase and aspartate aminotransferase profiles and its relation to the severity of uterine torsion in Egyptian buffalo. *Anim. Reprod. Sci.* **123**: 163-168.

Frazer, G.S., Perkins, N.R. and Constable, P.D. (1996). Bovine uterine torsion: 164 hospital referral cases. *Theriogenol*. **46**: 739-758.

Jonker, F.H. (2004). Fetal death: comparative aspect in large domestic animals. *Anim. Reprod. Sci.* **82(3)**: 415-430.

Kohan-Gadr, H.R., Lefebvre, R.C., Fecteau, G., Smith, L.C., Murphy, B.D., Suzuki, J., Girard, C. and Helie, P. (2008). Ultrasonographic and histological characterization of the placenta of somatic nuclear transfer-derived pregnancies in dairy cattle. *Theriogenol.* **69(2)**: 218-230.

Murty, K.K., Prasad, V. and Murty, P.R. (1999). Clinical observations on uterine torsion in buffaloes. *Indian Vet. J*. **76(7)**: 643-645.

Nanda, A.S., Brar, P.S. and Prabhakar, S. (2003). Enhancing reproductive performance in dairy buffalo: major constraints and achievements. *Reprod. Suppl*. **61**: 27-36.

Noakes, D.E., Parkinson, T.J. and England, G.C.W. (2009). Veterinary Reproduction and Obstetrics. (9th edn.). Saunders Publishing, China.

Purohit, G.N., Barolia, Y., Shekhar, C. and Kumar, P. (2011). Diagnosis and correction of uterine torsion in cattle and buffaloes. *Raksha Techn. Rev.* **1(1)**: 11-17.

Renaudin, C.D., Troedsson, M.H.T., Gillis, C.L., King, V.L. and Bodena, A. (1997). Ultrasonographic evaluation of the equine placenta by transrectal and transabdominal approach in the normal pregnant mare. *Theriogenol.* **47(2)**: 559-573.

Sertich, P.L. (1993). Clinical anatomy and evaluation of equine fetal membranes. In: Proc Ann Meeting Sot. *Theriogenol*. 178-184.

Vaala, W.E. and Sertich, P.L. (1994). Management strategies for mares at risk for periparturient complications. *Vet. Clin. North American Eq. Pract*. **10**: 237-265.