Haryana Vet. (December, 2016) **55 (2)**, 185-187

Research Article

AN OUTBREAK OF CONTAGIOUS ECTHYMA WITH RARE TONGUE LESIONS IN A GOAT FLOCK IN HARYANA

TARUN KUMAR[1]*, NEELESH SINDHU[1], AMAN KUMAR[2], GAURAV CHARAYA[3], ANKIT KUMAR[3] SUSHILA MAAN[2] and N.K. MAHAJAN[4]

[1]Teaching Veterinary Clinical Complex, [2]Department of Animal Biotechnology
[3]Department of Veterinary Medicine, [4]Department of Veterinary Public Health and Epidemiology
College of Veterinary Sciences, Lala Lajpat Rai University of Veterinary and Animal Sciences
Hisar-125 004, India

Received: 01.06.2016; Accepted: 19.11.2016

ABSTRACT

An outbreak of caprine contagious ecthyma (CE) in a flock of Amritsari goats in Hisar district of Haryana (India) with some rare clinical lesions is reported. Of the 12 adult goats recently introduced, nine goats (75%) were severely affected showing characteristic signs. The lesions were mainly confined to the mouth and oral cavity which included swollen lips, gingivitis and in later stages ulceration and scab formation on lips. Lesions on the dorsal surface of tongue were also observed in some cases which are relatively rare in occurrence. Representative samples (swab and scab samples) from severely affected goats were processed for confirmatory diagnosis by semi nested polymerase chain reaction (PCR) assay based on *CE* virus specific primers for B2L gene which give a characteristic band of 235 bp. All the representative samples were found positive confirming a CE outbreak. Washing of lesions with 3% iodine solution along with use of enrofloxacin to control secondary infection proved helpful in fast recovery.

Key words: Contagious ecthyma, goat flock, outbreak

Contagious ecthyma (CE) is an acute, contagious and economically important viral disease of sheep, goat and some other domesticated and wild ruminants. This disease is also known as contagious pustular dermatitis, scabby mouth or sore mouth and is caused by a parapox virus of the subfamily *Chordopoxvirinae*, family *Poxviridae* (Nandi *et al*., 2011; ICTV, 2014). The disease is more severe in goats than in sheep (Thomas *et al*., 2003). Disease is commonly recorded in young animals in the age group of 3-6 months and may occur at any time of the year but is more common in summer, fall and winter seasons (Radostits *et al.*, 2006). Lesions are mainly found around the mouth, the mucous membranes of the lips and gums but the virus can also spread to other parts of the body. Lesions include erythmatous spots or swelling followed by formation of papules and then scabs (McElroy and Bassett, 2007). The morbidity of the disease can be very high, approaching 100%, but the mortality rate in uncomplicated cases rarely exceeds 1%. Disease can be diagnosed on the basis of clinical signs, typical lesions and virus identification. Previously histopathology and even electron microscope have been used for viral identification which were time consuming and laborious techniques but now molecular technique like PCR assay is sensitive and rapid way to identify the causative agent (Maan *et al*., 2014). In this study an outbreak of CE in goats in Haryana is reported.

*Corresponding author: tarunvet@gmail.com

MATERIALS AND METHODS

Epidemiologic Aspect: Detailed history with respect to breed, area, size of herd and age was recorded. Seasonal relationship with the disease was also recorded. Clinical signs and specific gross lesions were recorded.

Samples Collection and Processing: Blood samples from juglar vein were collected from three representative cases in EDTA coated sterile vials and complete blood count was performed using fully automated haematoanalyser (MS4SE, France). Scabs and swab material were also collected without any preservative from these three cases for DNA extraction and polymerase chain reaction (PCR) assay.

Molecular Study: PCR assay based on major envelope membrane glycoprotein (B2L) gene of the virus was targeted. For amplification of partial B2L gene, the standard protocol as described by Inoshima *et al.* (2000) with some modifications was followed. This protocol amplified partial sequences of B2L gene by using a set of 3 primers pair in a semi-nested PCR format. During the first round of amplification a set of pan-parapoxvirus primer-1 (PPP-1) and pan-parapoxvirus primer-4 (PPP-4) was used to generate an amplicon of 594 bp. Later

Table 1
Primer pairs used in semi nPCR amplification of extracted viral nucleic acid

	Primer name	Primer sequence (5'–3')	Product size	Reference
Ist set of primer	PPP-1	GTCGTCCACGATGAGCAGCT	594 bp	Inoshima
	PPP-4	TACGTGGGAAGCGCCTCGCT		*et al.* (2000)
IInd set of primer	PPP-3	GCGAGTCCGAGAAGAATACG	235 bp	
	PPP-4	TACGTGGGAAGCGCCTCGCT		

in semi-nested PCR, an inner primer PPP-3 was used with PPP-4 to produce an amplicon size of 235 bp (Table 1). The PCR thermal cycling parameters used were: initial denaturation at 95^{0}C for 3 min, 35 cycles of denaturation (94^{0}C, 1 min), annealing (54^{0}C, 45 sec) and extension (72^{0}C, 45 sec), final elongation (72^{0}C, 10 min) and the PCR products were kept at 4^{0}C until used. The PCR amplicons were visualized using gel doc system after resolution under 1% agarose gel having ethidium bromide as dye.

Treatment: The affected animals were treated with enrofloxacin @ 5 mg/kg b. wt. I/M daily once for 5 days to control secondary bacterial infection along with supportive therapy including vitamin C and vitamins AD_3E. Mouth lesions were washed with 1:10,000 $KMnO_4$ solution along with single application of 3% iodine solution i.e. lugol's iodine.

RESULTS AND DISCUSSION

Anamnesis revealed that the affected goats were from village Pirwala, distt. Hisar, Haryana. Total flock size was 70; of which 12 adult goats were recently introduced in the flock. All these were purchased from Jalandhar district in state of Punjab. Out of these 12 goats, 9 goats (75%) were severely affected but no mortality was reported. Affected animals were of Amritsari breed having age between 1.5-2 years (adults).

Clinical examination revealed pyrexia (104^{0}F-105^{0}F) and characteristic signs of CE like severe proliferative ulcerated cauliflower like lesions around lips and localised crustated nodular like lesions covering whole dorsal surface of tongue (Fig. 1). Diarrhoea, pneumonia and loss of appetite were the other clinical signs in the affected goats. Haematological examination revealed anaemia (Hb=6.0 g%) and neutrophilia (82%) suggesting secondary bacterial infection in the affected animals. Nested PCR assay followed by gel electrophoresis revealed characteristic band of 235 bp (Fig. 2) and confirmed the disease. All the affected animals recovered within 5 days of treatment.

Contagious ecthyma is a common widespread viral disease of small ruminants affecting all age groups and is endemic in different parts of world including India. In the recent past, outbreaks of CE in sheep and goats have been reported from different parts of country like from Kashmir (Tufani *et al*., 2009), Uttarakhand (Venkatesan *et al*., 2011), Assam (Bora *et al*., 2012), Uttar Pradesh (Kumar *et al.*, 2014), Rajasthan (Maan *et al*., 2014). This report provided additional epidemiological information with first recent outbreak from Haryana along with rare appearance of CE lesions on the dorsal surface of tongue. After going through the published literature it was found that since decades there is no published report of this CE from Haryana state. This disease is regarded as one of the top 20 most important diseases in terms of impact on poor farmers in developing countries (Perry *et al*., 2002). The present outbreak was recorded in the month of December i.e. winter and these goats were mostly stall fed during these months. Maan *et al*. (2014) reported outbreaks of CE from Rajasthan (north western region of India) during the early summer (April-June). Kumar *et al.* (2014) reported another CE outbreak during the month of September 2012, in the Muzzaffarnagari sheep flock at CIRG, Makhdoom, India. Many other workers like Leite-Browning (2008), Nandi *et al*. (2011) too reported CE outbreaks in different months of year. So it can be concluded that the disease can occur anytime during the year. In the present outbreak stressors like transportation and extreme weather conditions appeared to be the predisposing factors.

Typical lesions of CE as described earlier were reported by many workers (Radostits *et al*., 2006) but lesions on the tongue are usually very rare in occurrence and were observed in the present outbreak in almost all the affected cases. PCR assay using B2L gene primers was found to be a rapid in detecting the disease which was in accordance to the reports of many scientists (Kanou *et al*., 2005; Klein and Tryland, 2005; Hosmani *et al*., 2007). Same primers set was also used by Ferede *et al*. (2014) and found them specific in detecting field outbreak of CE.

The present findings suggest occurrence of lesions even on tongue in contagious ecthyma affected cases

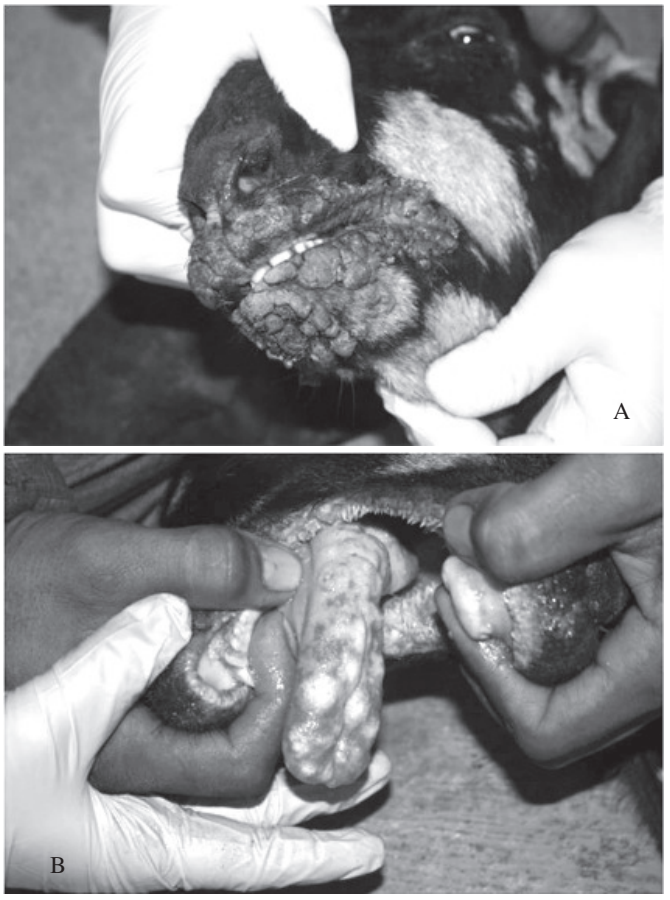

Fig 1. Clinical signs in affected goats. A. Scaby and ulcerated cauliflower like lesions around lips; B. Crustated papule like projections on dorsal surface of tongue.

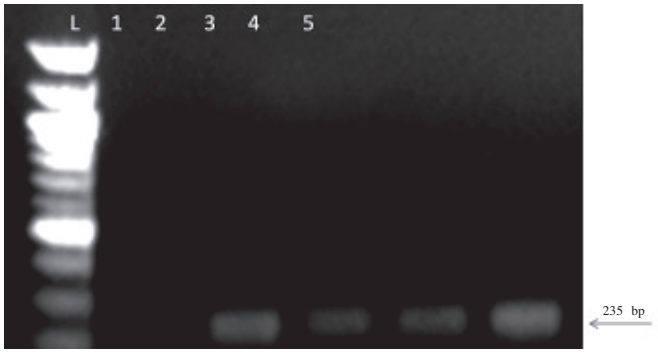

Fig 2. Electropherogram showing amplification of B2L gane with inner primers PPP-3 and PPP-4 of Orf virus (235 bp product size). L: 100 bp DNA ladder, L1: non-template/negative control. L2-4: field samples, L5: positive control.

and timely therapeutic management may be helpful in minimizing economic losses to the farmers.

REFERENCES

Bora, D.P., Barman, N.N., Das, S.K., Bhanuprakash, V., Yogisharadhya, R., Venkatesan, G, Kumar, A., Rajbongshi, G., Khatoon, E., Chakraborty, A. and Bujarbaruah, K.M. (2012). Identification and phylogenetic analysis of orf viruses isolated from outbreaks in goats of Assam, a north eastern state of India. *Virus Genes* **45(1)**: 98-104.

Ferede, Y., Habtamu, A. and Gebresellasie, S. (2014). Confirmatory diagnosis of contagious ecthyma by polymerase chain reaction at Adet Sheep Research Sub-Centre, Ethiopia: A case report. *J. Vet. Med. Anim. Hlth.* **6(7)**: 187-191.

Hosmani, M., Yadav, S., Kallesh, D.J., Mondal, B., Bhanuprakash, V. and Singh, R.K. (2007). Isolation and characterization of an Indian orf virus from goats. *Zoonoses Pub. Hlth*. **54**: 204-208.ICTV. (2014). http://www.ictvonline.org/virusTaxonomy.asp.

Inoshima, Y., Morooka, A. and Hiroshi, S. (2000). Detection and diagnosis of parapoxvirus by the polymerase chain reaction. *J. Virol. Methods* **84**: 201-208.

Kanou, Y., Inoshima, Y., Shibahara, T., Ishikawa, Y., Kadota, K., Ohashi, S., Morioka, K., Yoshida, K. and Yamada, S. (2005). Isolation and characterization of a parapox virus from sheep with popular stomatitis. *Japan Agric. Res. Quar*. **39**: 197-203.

Klein, J. and Tryland, M. (2005). Characterisation of parapoxviruses isolated from Norwegian semi-domesticated reindeer (*Rangifer tarandus tarandus*). *Virol. J.* **2**: 79.

Kumar, N., Wadhwa, A., Chaubey, K.K., Singh, S.V., Gupta, S., Sharma, S., Sharma, D.K., Singh, M.K. and Mishra, A.K. (2014). Isolation and phylogenetic analysis of an orf virus from sheep in Makhdoom, India. *Virus Genes* **48(2)**: 312-319.

Leite-Browning, M. (2008). Contagious ecthyma (Contagious ecthyma/ sore mouth) in sheep and goats Alabama Cooperative Extension System; Alabama A&M University and Auburn University.

Maan, S., Kumar, A., Batra, K., Singh, M., Nanda, T., Ghosh, A. and Maan, N.S. (2014). Isolation and molecular characterization of contagious pustular dermatitis virus from Rajasthan, India. *Virus Dis*. **25(3)**: 376–380.

McElroy, M.C. and Bassett, H.F. (2007). The development of oral lesions in lambs naturally infected with Orf Virus. *Vet. J.* **174(3)**: 663.

Nandi, S., Ujjwal, K. D. and Chowdhury, S. (2011). Current status of contagious ecthyma or orf disease in goat and sheep-A global perspective. *Small Rum. Res.* **96**: 73-82.

Perry, B.D., Randolph, T.F., McDermott, J.J., Sones, K.R. and Thornton, P.K. (2002). Investing in Animal Health Research to Alleviate Poverty. International Livestock Research Institute Nairobi, Kenya.

Radostits, O.M., Gay, C.C., Hinchliff, K.W. and Constable, P.D. (2006) In: Veterinary Medicine. A Text Book of the Diseases of Cattle, Sheep, Goats and Horses. (10th edn.) London, New York, Philadelephia: WB Saunders Co.

Thomas, K., Tompkins, D.M., Sainsbury, A.W., Wood, A.R., Dalziel, R., Nettleton, P.F. and Mc Innes, C.J. (2003). A novel poxvirus lethal to red squirrels (*Sciurus vulgaris*). *J. Gen. Virol*. **84**: 3337-3341.

Tufani, N.A., Hafiz, A., Makhdoomi, D.M. and Peer, F.U. (2009). Contagious Ecthyma in Small Ruminants and their Therapeutic Management. *Intas Polivet*. **10(2)**: 314.

Venkatesan, G., Balamurugan, V., Bora, D.P., Yogisharadhya, R., Prabhu, M. and Bhanuprakash, V. (2011). Sequence and phylogenetic analyses of an Indian isolate of orf virus from sheep. *Vet Ital.* **47(3)**: 323-332.