Haryana Vet. **49** (December, 2010), pp 35-37

Research Article

TOPOGRAPHY OF THE SUBCOMMISSURAL ORGAN OF THE PIG

P. KUMAR, PAWAN KUMAR[1] and GURDIAL SINGH
Department of Veterinary Anatomy, College of Veterinary Sciences
CCS Haryana Agricultural University, Hisar-125 004

ABSTRACT

The subcommissural organ of pig extended from pineal gland to recessus mesocoelicus on the ventral aspect of posterior commissure and formed partly the roof of third ventricle and cerebral aqueduct. The organ was comprised of two cellular layers i.e. a pseudostratified columnar ciliated ependyma towards the free ventricular surface and a hypendyma adjoining the nervous tissue of the posterior commissure. The subcommissural organ was divided cranio-caudally into four parts viz. pars-supracommissuralis, pars-precommissuralis, pars-subcommissuralis and pars-retrocommissuralis in mid sagittal plane. The organ in transverse plane depicted a horizontal strip of tissue which was continued on either side in the form of ventro-lateral limbs. An abrupt transition of the modified ependyma into simple ventricular ependyma was clearly discernible.

Key words: Subcommissural organ, pars-supracommissuralis, pars-precommissuralis, pars-subcommissuralis, pars-retrocommissuralis, pig

The circumventricular organs (CVOs) located around third and fourth ventricles of brain are unique because of their topographic location, presence of a well developed vascular system and absence of blood brain barrier. They participate in mechanism involving interaction between the brain, the cerebrospinal fluid, blood and nervous tissue (Leonhardt, 1980). The subcommissural organ (SCO) being one of the CVOs is a phylogenitically structure possessing a highly specialized area of ependyma located mainly towards the roof of third ventricle beneath the posterior commissure (PC). Far-reaching work has been done on topography of the SCO in buffalo (Ramkrishna and Saigal, 1985), goat (Kumar *et al.,* 1997), sheep (Saggar *et al.,* 2000), camel and horse (Kumar *et al.,* 1999, 2007). The present study was planned in pigs to investigate topographic location, extent and relations of the SCO.

MATERIALS AND METHODS

Heads of six adult pigs of either sex of local mixed breed were procured from local meat shops immediately after slaughter. The brain tissues containing SCO were excised transversely from mammillary body to caudal colliculi of corpora quadrigemina and fixed in 10 percent neutral buffered formalin for 48-72 h. The tissues were processed for paraffin technique of light microscopy to cut serial sections of 6-15 µm thickness in transverse and sagittal planes and stained with routine Harris' haematoxylin and eosin stain (Luna, 1968). Ocular micrometer was used to record the micrometric observations of the extent of the different segments of the SCO.

RESULTS AND DISCUSSION

The SCO in pig was situated on the ventral aspect of posterior commissure extending from pineal gland to the recessus mesocoelicus forming partly the roof of third ventricle and cerebral aqueduct. Similar findings on its extent have been reported in sheep (Barlow *et al.,* 1967; Saggar *et al.,* 2000), rabbit (Kimble and Mollgard, 1973), buffalo (Ramkrishna and Saigal, 1985), goat (Kumar *et al.,* 1997), camel and horse (Kumar *et al.,* 1999, 2007). The SCO cranially participated in the formation of caudal wall of recessus infrapinealis whereas caudally lined the recessus mesocoelicus and extended into anterior part of cerebral aqueduct. Topographically, the SCO in mid sagittal sections was divided into four parts which cranio-caudally extended as pars-supracommissuralis (PSC), pars-precommissuralis (PPC), pars-subcommissuralis (PSU) and pars-retrocommissuralis (PRC) by employing anatomical landmarks (Fig. 1). The division closely matched with rat (Mitro and Palkovits, 1981), buffalo (Ramkrishna, and Saigal,

[1]Corresponding author

1985), goat (Kumar *et al.,* 1997), sheep (Saggar *et al.,* 2000) and horse (Kumar *et al.,* 2007).

The PSC (Fig. 1) was anterior most convex shaped structure of the SCO extending from cranio-dorsal aspect of posterior commissure (PC) to its junction with pineal gland. This constituted second smallest portion (526.6 µ) of the SCO in the pig and had been reported the smallest in goat and sheep (Kumar *et al.,* 1997; Saggar *et al.,* 2000), the second largest (1065.6 µ) in horse (Kumar *et al.,* 2007) and a thin median band covering the posterior part of pineal stalk in buffalo (Ramkrishna and Saigal, 1985). The convex shaped PPC, a caudal continuation of PSC, was the second largest (1647 µ) segment of the SCO in pig and extended upto medial groove lining the cranial part of posterior commissure as observed in goat and sheep (Kumar *et al.,* 1997; Saggar *et al.,* 2000). Conversely, the PPC was the second smallest part (732.6 µ) of the SCO in the horse (Kumar *et al.,* 2007).

The strongly convex shaped PSU (Fig. 1) constituted the maximum portion of the organ (3.203 mm) and occupied most of the ventral aspect of PC and also participated in the formation of roof of the third ventricle. The free ependymal surface towards ventricle in the pig was regular as reported in horse (Kumar *et al.,* 2007) but was irregular in buffalo (Ramkrishna and Saigal, 1985) and sheep (Saggar *et al.,* 2000) due to the presence of folds and crypts. The strip of PSU was further subdivided into three subparts due to presence of two small folds in the horse (Kumar *et al.,* 2007). The PRC, the smallest (425 µ) among all the four parts, was caudal continuation of PSU extending from the level of recessus mesocoelicus to adjacent cranial part of cerebral aqueduct as reported in horse (Kumar *et al.,* 2007). In contrast, the PSC was the smallest constituent observed in goat (Kumar *et al.,* 1997) and sheep (Saggar *et al.,* 2000). The modified ependyma was distinct but cell layers were less discernible at the point where PRC transitioned into simple ventricular ependyma. This portion presented extensive folds and deep lateral grooves in its cranial part in buffalo (Ramkrishna and Saigal, 1985).

The SCO in transverse sections appeared in the form of a horizontal strip (Fig. 2) having two cells layers i.e. ependyma and hypendyma in contrast to

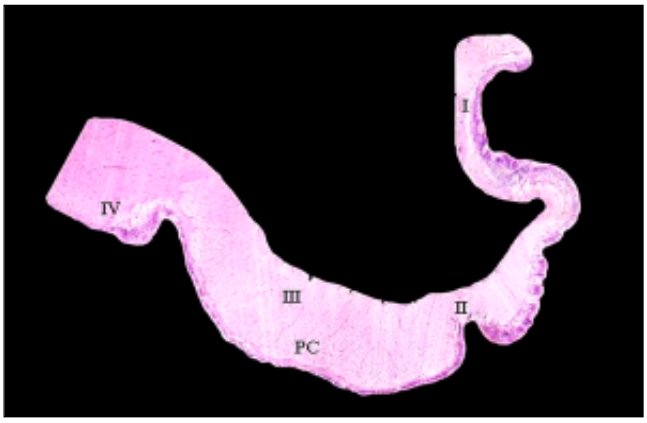

Fig 1. A composite photomicrograph of SCO in mid sagittal section showing pars supracommissuralis (I), pars-precommissuralis (II), pars-subcommissuralis (III), pars-retrocommissuralis (IV) along with posterior commissure (PC). (H. & E. x 25)

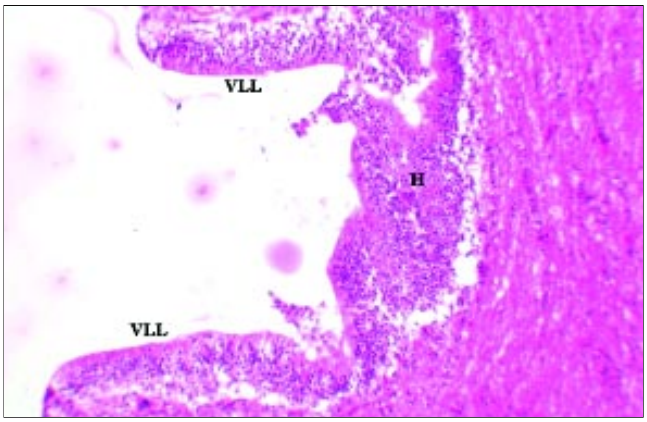

Fig 2. Photomicrograph showing horizontal strip (H) and ventro-lateral limbs (VLL) of SCO in transverse section. (H. & E. x 100)

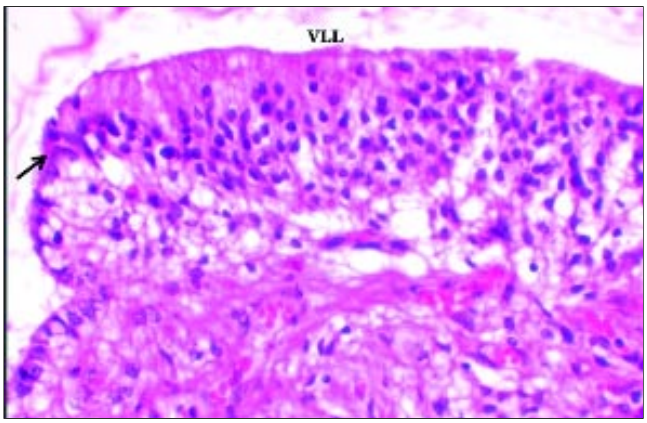

Fig 3. Photomicrograph showing magnified view of ventro-lateral (VLL) limb with an abrupt transition of pseudostratified columnar ciliated ependyma into simple ventricular ependyma (arrow). (H. & E. x 400)

three cell layers observed in goats and sheep (Kumar *et al.,* 1997; Saggar *et al.,* 2000). The ventral projections on either sides of horizontal strip were called as ventro-lateral limbs (Fig. 2) which formed lateral walls of third ventricle cranially and then of cerebral aqueduct caudally. However, these limbs were considered as additional parts in the SCO of buffalo and were reported to be present only in pars-precommissuralis region of the SCO in buffalo (Ramkrishna and Saigal, 1985). Maximum (148.9 µ) and minimum (81.9 µ) height of the organ was observed in PPC and PSC, respectively.

The SCO in pig had a length of 1.850-2.725 mm in transverse serial sections, however, the sagittal sections revealed the extension of the organ upto a distance of 5.470-6.257 mm. The variation in dimensions was due to folding and curvature of the SCO in sagittal sections. Collins and Woollam (1979) in rats recorded a maximum length of 1.0 mm and a maximum width of 0.5 mm. Ramkrishna and Saigal (1985) in young buffaloes reported 4.69-5.70 mm as the largest dimension of the organ whereas, maximum and minimum width of 2.34-3.35 mm and 1.14-1.60 mm were recorded at cranial and caudal portions of the organ, respectively. Kumar *et al.* (1997) in goat found the SCO to be 2.76-3.00 mm in length in transverse serial sections and 2.3-8.7 mm in the sagittal sections. Saggar *et al.* (2000) reported a length of 1.8-2.3 mm and 6.2-7.9 mm in sheep and Kumar *et al.* (2007) revealed 4.1 mm and 9.2 mm in horse in transverse and sagittal sections, respectively. The pseudostratified columnar ciliated ependyma of the SCO abruptly changed into simple cuboidal ependyma lining the ventricle (Fig. 3).

REFERENCES

Barlow, R.M., D'Agostino, A.M. and Cancilla, P.A. (1967). Morphological and histochemical study of the subcommissural organ of young and old sheep. *Z. Zellforsch.* **77**: 299-315.

Collins, P. and Woollam, D.H.M. (1979). The ventricular surface of the subcommissural organ. A scanning and transmission electron microscopic study. *J. Anat.* **129**: 623-631.

Kimble, J.E. and Mollgard, K. (1973). Evidence for basal secretion in the subcommissural organ of the adult rabbit. *Z. Zellforsch.* **142**: 223-239.

Kumar, Pawan, Kumar, S. and Singh, Y. (1997). Subgross structure of the subcommissural organ of goat. *Indian J. Anim. Sci.* **67**: 1062-1063.

Kumar, Pawan, Nagpal, S.K., Kumar, S. and Gupta, A.N. (1999). Histomorphology of the subcommissural organ of camel. *J. Camel Pract. Res.* **6**: 311-316.

Kumar, Pawan, Timoney, J.F. and Nagpal, S.K. (2007). Topography of the subcommissural organ in horse. *Haryana Vet.* **46**: 72-74.

Leonhardt, H. (1980). Ependym and Circumventricullare Organe. Neuroglia 1. Handbuch der microskopischen Anatomie des Menschen. Oksche A. and Vollrath L. (edts.), Springer-Verlag, New York.

Luna, L.G. (1968). Manual of Histologic Staining Methods of the Armed Forces Institute of Pathology. (3rd edn.), pp. 38-39. McGraw Hill Book Co., New York.

Mitro, A. and Palkovits, M. (1981). Morphology of the rat brain ventricles, ependyma and periventricular structures. *Bib. Anat.* **21**: 1-110.

Ramkrishna, V. and Saigal, R.P. (1985). Topographic organization of the subcommissural organ in buffalo *(Bubalus bubalis)* calves. *Indian J. Anim. Sci.* **55**: 311-355.

Saggar, D., Kumar, Pawan and Kumar, S. (2000). Topography of subcommissural organ of sheep. *Indian J. Vet. Anat.* **12**: 141-144.