Haryana Vet. **49** (December, 2010), pp 78

Clinical Article

MELANOMA IN A HARIANA COW

SATBIR SHARMA, R. N. CHAUDHARY[1] and KULDIP SINGH
Teaching Veterinary Clinical Complex, College of Veterinary Sciences
CCS Haryana Agricultural University, Hisar-125 004

SUMMARY

The present paper describes a case of melanoma in a Hariana cow which was observed as a lump hanging from left fold of flank with base at the level of stifle joint. The cut section of growth presented a soft interior of dark black colour. Histopathological examination of the growth confirmed it as a case of melanoma of low malignancy.

Key words: Melanoma, Hariana cow

Melanomas are considered rare in cattle than horses and dogs (Moulton, 1961; Crowel *et al.,* 1973). However, Ramakrisna and Muralimanohar (1980) and Prudhvi Reddy and Subba Raja (1990) have reported melanoma in cattle in India. We report a case of malignant melanoma in a Hariana cow.

A 5-6 year old Hariana cow was presented to the Teaching Veterinary Clinical Complex, CCS Haryana Agricultural University, Hisar in the month of August 2010. There was a lump hanging from left fold of flank with base at the level of stifle joint (Fig. 1). It was increasing in size since last six months at a slow rate but the size almost doubled in last one week with formation of a new nodule in the adjoining area.

Clinical examination revealed that it was a big elliptical growth with two smaller nodules at its antero-dorsal surface. It was covered by darker skin having sparse hair with ulceration on the surface. The animal was given Xylazin HCl (Xylaxin; @ 0.05mg/kg b.wt.) for sedation. In addition, 2% lignocain HCl (Lox) was infiltrated around the base of the mass. A series of horizontal mattress sutures were applied above the base of the tumour to arrest the haemorrhage and an elliptical incision was made to excise the tumour completely. The wound was dressed daily till the removal of sutures on 10th day. However, the recovery was uneventful.

The cut section (Fig. 2) of growth presented a soft interior of dark black colour. The histopathological section revealed heavy deposition of the melanin pigment in a wide spread manner obscuring the normal morphological features of tumour cells. Pleomorphic cells ranging from cuboidal to fusiform type with irregular branching were observed along with few mitotic figures. The case was diagnosed as melanoma of low malignancy. Melanoma may occur anywhere in the body but are most commonly located in perineal region and the root of the tail followed by head, udder, prepuce and limb (Stannard and Pulley, 1978). The abundance of melanin pigment is the most valuable marker for the identification of a melanocytic tumour (Sreenu *et al.,* 2003). A disturbance in metabolism associated with graying might have acted to stimulate the formation of new melanoblasts or stimulate their activity resulting in focal areas of overproduction in the dermis with subsequent tumour production (Theilen and Madwell, 1987).

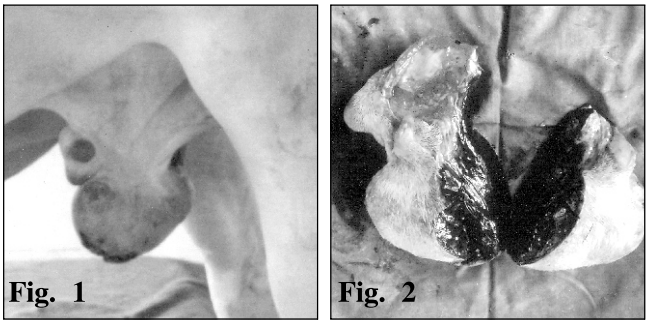

Figs 1 and 2. Melanoma in a cow. Note the cut section.

[1]Corresponding author

REFERENCES

Crowel, W.A., Chandler, E.W. and Williams, D.J. (1973). Melanoma in cattle: fine structure and a report of two cases. *Am J. Vet. Res.* **35**: 1691.

Moulton, J.E. (1961). Tumours in Domestic Animals. (2nd edn.), University of California Press, Los Angles, California, USA.

Prudhvi Reddy, K. and Subba Raja, S. (1990). A note on the incidence of melanoma in bovines. *Indian Vet. J.* **67**: 777.

Ramakrishnan, R. and Muralimanohar, B. (1980). Melanoma in domestic animals-a surgery. *Indian Vet. J.* **57**: 619.

Sreenu, M., Srinivas, M. and Nagaraj, P. (2003). Melanoma of the shoulder region in an ongle bullock. *Indian Vet. J.* **80**: 294-295.

Stannard. A.A. and Pulley, I.T. (1978). Melanoma. In Tumours in Domestic Animals. (2nd edn.), University of California Press, Los Angles, California, USA. pp. 62-70.

Theilen, G.H. and Madwell, B.R. (1987) Veterinary Cancer Medicine. (2nd edn.), Lea and Febiger, Philadelphia. pp. 314-325.