Haryana Vet. **48** (December, 2009), pp 29-32

Research Article

HISTOLOGICAL ARCHITECTURE OF ESOPHAGUS OF GOAT (CAPRA HIRCUS)

PAWAN KUMAR[1], R. MAHESH and P. KUMAR
Department of Veterinary Anatomy, College of Veterinary Sciences
CCS Haryana Agricultural University, Hisar-125 004

ABSTRACT

The present histological study was conducted on 6 young goats of local mixed breed. The cervical, thoracic and cardia portions of the esophagus revealed stratified squamous keratinized epithelium with papillated appearance except last portion. Lamina propria mucosae was formed by loose irregular connective tissue. Lamina muscularis mucosae was interrupted but of uniform thickness throughout the extent except its caudal most portion where it started diminishing and only a few longitudinally oriented smooth muscles were observed. Tunica submucosa had loose irregular connective tissue which became denser cranio-caudally. Esophageal glands were not observed throughout the extent of the organ. Tunica muscularis was constituted by an inner circular and an outer longitudinal layer which gradually became thicker towards the caudal portion where an additional oblique layer was also observed. A few nerve bundles were also observed at the junction of tunica muscularis layers. Tunica adventitia lined the cervical whereas tunica serosa lined the thoracic and caudal portion of the esophagus.

Key words: Esophagus, goat, histology

The esophagus plays an important role in transfer of ingested bolus from mouth cavity to stomach because of antiperistaltic action of its musculature. The literature is available on the microscopic structure of the esophagus in cow, sheep, dog (Goetsch, 1910) and buffalo (Gupta and Sharma, 1991). The present study was envisaged in goat to explore histological architecture of the esophagus along its different levels of extent especially in relation to occurrence of esophageal glands.

MATERIALS AND METHODS

The present study was conducted on esophagus of 6 goats immediately after their slaughter. The esophageal tissues collected from cervical, thoracic and cardia segments were fixed in 10% neutral buffered formalin and processed for paraffin technique of light microscopy. The paraffin sections of 5-6 μ were stained with routine Harris haematoxylin and eosin stain, Weigert's method for elastic fibres, Gomori's method for reticulum, Bielschowsky's method for axis cylinder and dendrites, Ayoub-Shklar's method for keratin and pre-keratin (Luna, 1968) and Crossman's trichrome stain for collagen fibres (Crossman, 1937). The sections were also stained by McManus' method for glycogen (PAS), Alcian blue method for muco-substances (pH 2.5), PAS-Alcian blue method for mucosubstances (pH 2.5) and diastase digestion method (Luna, 1968). Micrometric observations of epithelium were recorded with the help of ocular micrometer.

RESULTS AND DISCUSSION

The esophagus was lined by stratified squamous keratinized epithelium in cervical, thoracic and cardia portions (Figs 1-6). Its superficial surface was uneven and irregular due to folding of mucosa which at places presented papillae like structure. The deeper surface was also irregular and formed papillae of varying shapes and dimensions. The epithelium had been reported slightly keratinized in caudal cervical and thoracic regions but almost non-cornified in cardiac region in buffalo calves (Gupta and Sharma, 1991). The epithelium through out the post natal period and in adult did not show complete keratinization in opossum (Krause *et al.*, 1976). The epithelium was comprised of strata basale/germinativum, spinosum and corneum with varying number of cell layers (Fig 2). In most of places

[1]Corresponding author

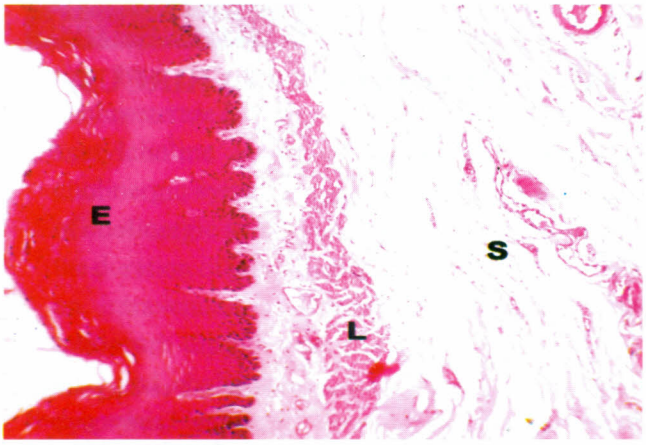

Fig 1. Stratified squamous keratinized epithelium (E), lamina muscularis mucosae (L) and tunica submucosa (S) of esophagus in cervical region. (H. & E. x 100)

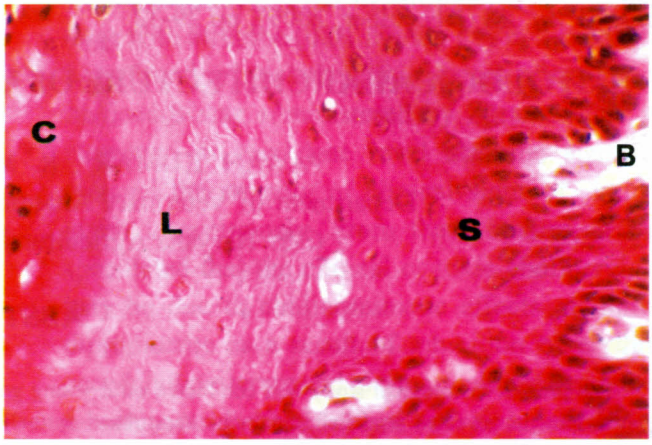

Fig 2. Strata basale (B), spinosum (S), deeper (L) and superficial (C) stratum of corneum in cervical region. (H. & E. x 400)

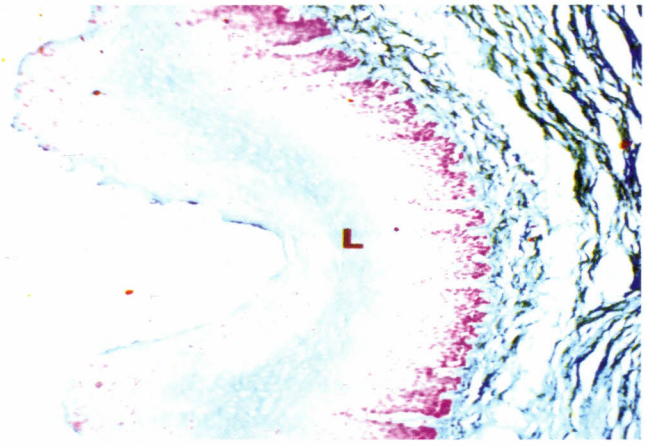

Fig 3. Strong Alcianophilic reaction in deeper stratum of corneum (L) of stratified squamous-keratined epithelium in cervical region. (Alcian blue x 400)

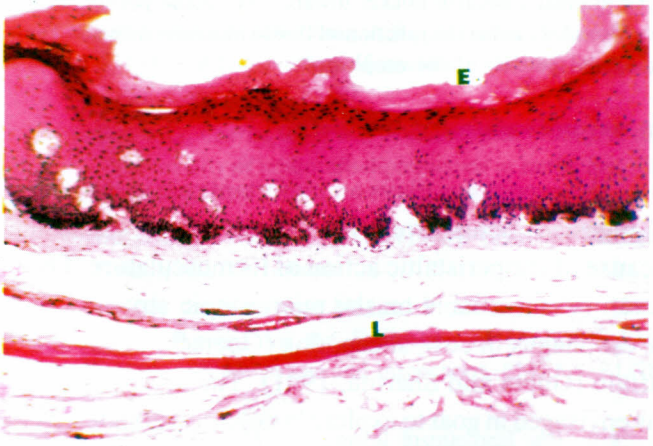

Fig 4. Stratified squamous keratinized epithelium (E) and isolated smooth muscles forming lamina muscularis mucosae (L) towards cardia region. (H. & E. x 100)

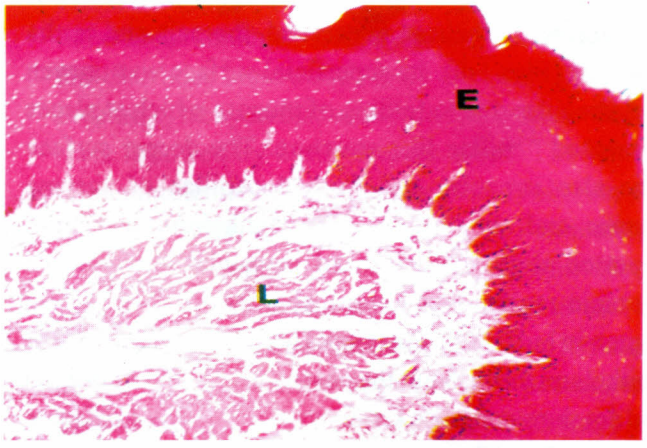

Fig 5. Thicker stratified squamous keratinized epithelium (E) and lamina muscularis mucosae (L) in thoracic region. (H. & E. x 100)

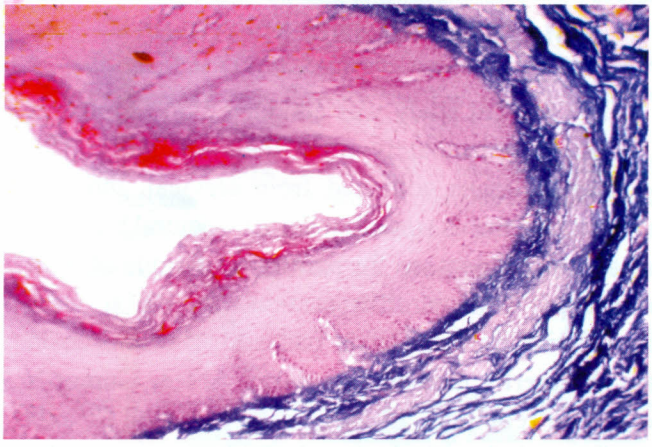

Fig 6. Distribution of collagen fibres in lamina propria mucosae and tunica submucosa of esophagus in cervical region. (Crossman's trichrome x 100)

the stratum corneum was thicker as compared to other layers and it was further subdivided in the cervical region into two secondary strata (Figs 1, 2) which can be compared with stratum lucidum and stratum corneum of plantar skin as reported earlier in ox, sheep and horse (Goetsch, 1910). The epithelium had been reported non-keratinised in dog, slightly keratinized in horse and pig and well keratinized in ruminants (Dellmann, 1993). True layers of stratum granulosum were not observed as reported in opossum (Krause *et al.*, 1976) and buffalo calves (Gupta and Sharma, 1991).

Stratum basale was constituted by single layer of columnar cells having vertically oriented oval to elongated nuclei (Fig 2). These nuclei were deeply basophilic due to condensation of darkly stained chromatin material throughout the nucleoplasm and also contained one or two eccentric nucleoli. The cytoplasm of these cells was eosinophilic. Stratum spinosum contained several layers of polygonal cells which varied in different regions. Their larger nuclei were oriented horizontally except those closer to stratum basale where these were oriented vertically. However the nuclei were less basophilic with prominent nucleolus which was generally single and centric/ eccentric in position. Superficial layers of stratum spinosum except cervical region were comprised of varying rows of irregular shaped nuclei having small aggregations of chromatin material throughout the nucleoplasm and centric/eccentric nucleolus (Fig 2). A few cells had lightly stained nuclei and a few cells had very large sized nuclei indicating some degenerative changes.

Deeper layers of stratum corneum comparable to stratum lucidum had 5-7 layers of lightly stained cells with tapering free ends (Fig 2). Their large, narrow, elongated nuclei with nuclear clefts were less basophilic because of small isolated clusters of less dense chromatin material. The density of nuclei was comparatively less than deeper layer. These cells possessed processes which intermingled with those of others. The finely granular cytoplasm was less eosinophilic and less dense except towards tapering ends where it was more eosinophilic. These cells showed a strong affinity for hyaluronic acid, weakly acidic sulfated mucosubstances and sialomucins as (Fig 3) demonstrated by Alcian blue stain (pH 2.5). PAS Alcian blue stain was also helpful to demarcate different strata of stratified squamous epithelium especially the processes of cells comprising deeper layers of stratum corneum. Stratum granulosum and stratum lucidum was absent in esophagus of buffalo calves (Gupta and Sharma, 1991). Stratum corneum varied in different regions. Its nuclei oriented in different directions were smaller, pyknotic and densely basophilic. Their cytoplasm was strongly eosinophilic. The keratin layer was thicker towards cardia (Fig 4) and at places this layer was desquamated. The epithelium was thicker in thoracic region (417.5 ± 42.1 μ) (Fig 5) as compared to cervical portion (337.2 ± 34.4 μ). It again decreased at the junction of esophagus and rumen (308.7 ± 27.2 μ).

The lamina propria mucosae was constituted by connective tissue cells, blood capillaries, collagen, reticular and a few elastic fibres as reported in domestic animals (Goetsch, 1910) and buffalo calves (Gupta and Sharma, 1991). The connective tissue extended into interpapillary pegs and reached up to the level of stratum lucidum in cervical region. The peg area was occupied by mainly the connective tissue cells. These pegs were broader and less deep than those of cervical region. Subepithelial portion had a dense arrangement of collagen fibers (Fig 6). The elastic fibers comparatively increased towards the thoracic portion. The blood capillaries increased in number towards lamina muscularis mucosae (LMM).

The LMM was formed by an interrupted single layer of smooth muscles (Figs 1, 5). It was thicker except at the junction of esophagus and rumen where it was represented by only a few isolated smooth muscle cells (Fig 4). Similar type of smooth muscles became thicker and regular in caudal cervical and thoracic regions and again modified into circularly arranged several slips of interrupted smooth muscles in buffalo calves (Gupta and Sharma, 1991). Two or more layers of longitudinally oriented smooth muscles formed a well developed muscularis mucosae throughout the esophagus in dog and was absent in upper region where esophageal glands were abundant in pig (Goetsch, 1910). In contrast the lamina muscularis mucosae was

as thick as outer layer of tunica muscularis (Dellmann, 1993) and was divided into an inner circular and an outer longitudinal layer of smooth muscles in pig (Sloss, 1954).

Tunica submucosa had loose irregular connective tissue containing bundles of collagen, few reticular and elastic fibers along with fine blood capillaries and small blood vessels which increased towards the deeper part (Figs 1, 6). A few isolated nerve bundles were also observed. Loose connective tissue allowed forming longitudinal folds in the mucosa of relaxed esophagus (Dellmann, 1993). Esophageal glands were not observed at any level of oesophagus studied during present investigation as reported absent in sheep and ox (Goetsch, 1910). However, seromucous tubulo-alveolar glands were reported in initial portion of esophagus in buffalo calves (Gupta and Sharma, 1991) and cervical region in ruminants (Banks, 1986). More thickening of stratified squamous epithelium or lamina muscularis mucosae had been reported in the species where esophageal glands were absent and also in the animals which depend on coarse feed especially vegetable fodders (Goetsch, 1910). The secretory units comprising of two different cell types continued to develop throughout the post natal life in the esophagus of opossum (Krause *et al.*, 1976).

Tunica muscularis was constituted by a thick inner circular and a thinner outer longitudinal layer of striated skeletal muscles. Some of the muscle bundles of outer layer passed obliquely and formed an interlocking pattern. The muscle bundles were separated from each other by fine collagen and reticular fibers. In thoracic region both the layers were almost of equal thickness. A few muscle fasciculi staining deeply eosinophilic were also observed at the periphery of outer layer of tunica muscularis. Towards cardia three layers of striated muscles were oriented as inner circular layer (thickest), outer longitudinal and middle oblique layer of muscles. Tunica muscularis had been reported to be composed of entirely striated muscles towards upper half of esophagus while in lower part smooth muscles appeared intermingled and constituted inner layer towards cardia in pig (Sloss, 1954). However, complete striated muscles had been reported in buffalo calves (Gupta and Sharma, 1991) and in ruminants (Banks, 1986).

Tunica adventitia having loose irregular connective tissue contained fine reticular, collagen and a few elastic fibers along with fine blood capillaries, small blood vessels, fatty tissue and isolated nerve bundles as reported in buffalo calves (Gupta and Sharma, 1991). Tunica serosa possessing a mesothelium covered the above structures in thoracic and cardia regions.

REFERENCES

Banks, W.J. (1986). Applied Veterinary Histology. (3rd edn.), Mosby Year Book, Baltimore.

Crossman, G.A. (1937). A modification of Mallory's connective tissue stain with a discussion of principles involved. *Anat. Rec.* **69**: 33-38.

Dellmann, H.D. (1993). Text Book of Veterinary Histology. (6th edn.), Lea and Febiger, Philadelphia.

Goetsch, E. (1910). The structure of the mammalian oesophagus. *Am. J. Anat.* **10**: 1-40.

Gupta, S.K. and Sharma, D.N. (1991). Regional histology of the oesophagus of buffalo calves. *Indian J. Anim. Sci.* **61**: 722-724.

Krause, W.J., Cutts, J.H. and Leeson, C.R. (1976). The postnatal development of the alimentary canal in the opossum. 1. Oesophagus. *J. Anat.* **122**: 293-314.

Luna, L.G. (1968). Manual of Histologic Staining Methods of the Armed Forces Institute of Pathology. (3rd edn.), McGraw Hill Book Co., New York.

Sloss. M.W. (1954). The microscopic anatomy of the digestive tract of *Sus Scrofa Domestica*. *Am. J. Vet. Res.* **57**: 578-593.