

EVALUATION OF STAINLESS-STEEL POSITIVE PROFILE END THREADED INTRAMEDULLARY PINS FOR MANAGEMENT OF LONG BONE FRACTURES IN DOGS

JAMTA RAM*, M.C. PARASHAR, S. SINGH, M.M. MALI¹ and M. AGRAWAL²

Department of Veterinary Surgery and Radiology, ¹Department of Veterinary Medicine,

²Department of Veterinary Pathology, Post-Graduate Institute of Veterinary Education and Research, Jaipur, RAJUVAS, Bikaner-334001 (Rajasthan)

Received: 05.05.2023; Accepted: 11.07.2023

ABSTRACT

The aim of the study was to evaluate the stainless-steel positive profile end threaded (PPET) intramedullary pins for the management of long bone fractures in dogs. Six dogs (n=6) with long bone fractures were included in the present study. All the fractures were stabilized with stainless steel PPET intramedullary pins under general anaesthesia. Modified Robert Jones bandaging was applied for providing external support to fractured limb before surgery and for two weeks after surgery in all the cases. Osteomyelitis was observed in two cases and with the help of antibiotic administration it was resolved successfully. Seroma formation at pin insertion site was seen in two cases. Subcuticular suture dehiscence was noted in one case. Radiographically slight bone shortening was observed in one case. Other complications like malunion and/or non-union was not seen in any of the cases. Normal ambulation of the affected limb was attained in all the cases.

Keywords: Dogs, Intramedullary pinning, Long bone fractures, Positive profile end threaded

How to cite: Ram, J., Parashar, M.C., Singh, S., Mali, M.M. and Agrawal, M. (2023). Evaluation of stainless-steel positive profile end threaded intramedullary pins for management of long bone fractures in dogs. *Haryana Vet.* 62(2): 104-107.

Orthopaedic affections constitute a major problem in the small animal practice and most of these affections are related to long bone diaphyseal fractures such as the femur, humerus, and tibia bones (Piermattei *et al.*, 2006). Internal fixation has many advantages over external fixation. It results in restoration of the precise anatomy of the bone and early function of the limb and allows fractures to unite while maintaining the function of the joints and soft tissues (Perren, 2002). One of the most widely used method for repairing long bone fractures is intramedullary pinning (Kaur *et al.*, 2015). The end threaded intramedullary pin (Schanz) can be effectively used in internal fixation of diaphyseal fracture of long bones in dogs (Parashar *et al.*, 2020). Both the positive and negative profile end threaded intramedullary pin were efficient for the management of long bone fractures in dogs as they resisted pin migration, pin breakage and fixation failure (Shivhare *et al.*, 2023). End-threaded intramedullary positive profile screw ended self-tapping pin was efficient in repairing of humerus shaft fracture because the distal threaded part of end threaded pin engaged the distal segment of fracture and resisted pin migration, pin breakage and all load acting on bone, i.e. compression, tension, bending, rotation. This leads to early fracture healing and ambulation of the limb (Singh *et al.*, 2022). The positive profile end threaded stainless steel intramedullary pin provided rigid fixation and early fracture healing in majority of the cases with an exception in two cases where it was failed due to improper management by the pet owners (Palli *et al.*, 2020). The present study was conducted with aim of evaluation of the stainless-steel positive profile end threaded intramedullary

pins for management of long bone fractures in dogs.

MATERIALS AND METHODS

The present study was conducted on six clients owned dogs (n=6) with fracture of long bones which were presented to the Veterinary Clinical Complex, Department of Veterinary Surgery and Radiology, PGIVER, Jaipur. Anamnesis related to breed, sex, age, etiology of fracture, limb involved and bone involved were recorded (Table 1). Physical and radiographical examination was carried out for diagnosis and confirmation of the type of fracture (Fig. 5) and dimensions of bone for selection of proper stainless steel PPET pins. Preoperative grade of lameness was also recorded in all the cases (Fig. 1) and code number A1 to A6 was given to all dogs. If required, the dogs were stabilized hemodynamically by administration of intravenous fluid and other medication besides analgesics and antibiotics. Modified Robert Jones bandage was applied on fractured limb site and temporarily immobilized till the day of surgery.

Aseptic surgical management was planned as early as possible. Intramuscular injection of Butorphanol @ 0.2 mg/kg body weight, Ceftriaxone Tazobactam @ 20 mg/kg body weight, Atropine sulphate @ 0.04 mg/kg body weight and Xylazine @ 1 mg/kg body weight were given as preanaesthetic medication in all the dogs. Anesthesia was induced by intramuscular administration of Ketamine @ 5 mg/kg body weight. Maintenance of anesthesia was achieved with the help of Isoflurane inhalant anesthesia using small animal anaesthesia machine.

In all the cases, open reduction and internal fixation of long bone fractures with stainless-steel PPET intramedullary pins using the approach detailed by Fossum

*Corresponding author: mukeshparashar77@gmail.com

Table 1. Table showing details of all the dogs included in the study

Case	Breed	Age (M)	Sex	Weight (Kg)	Etiology	Limb	Bone	Type of fracture	Location of fracture
A1	ND	3	M	9.0	Automobile accident	RH	Femur	Comminuted	Mid shaft
A2	ND	6	M	7.5	Fighting among animals	LH	Femur	Oblique	Proximal 1/3 rd
A3	Labrador	6	F	11.0	Fall from height	RH	Tibia	Oblique	Proximal 1/3 rd
A4	GSD	5	F	18.0	Fighting among animals	LF	Humerus	Comminuted	Mid shaft
A5	Pakistani bully	8	M	17.0	Automobile accident	RH	Femur	Comminuted	Proximal 1/3 rd
A6	Labrador	96	M	30.0	Automobile accident	RH	Tibia	Comminuted	Proximal 1/3 rd

Table 2. First wearing in days and grade of lameness in all dogs

S. No.	First weight bearing (days)	Grade of Lameness		
		Pre-operative	Post-operative (Day 30)	Post-operative (Day 60)
1.	2	3	2	0
2.	4	3	2	1
3.	1	3	1	0
4.	7	4	3	2
5.	10	3	3	2
6.	9	4	2	1
Mean±SE	5.50±1.52	3.33±0.21	2.17±0.31	1.00±0.37

(2019) was followed (Fig. 2). Ancillary cerclage wires were also used, if required in any case with orthopedic wire (Fig. 3). In majority of the animals at the fracture site mild bone loss along with minimal cortex to cortex contact after the reduction and stabilization of fracture was noticed. In all the cases surgical incision was sutured in three layers. Postoperatively, the limb was supported with a modified Robert Jones bandage for 2 weeks. Antiseptic dressing of surgical wound was performed on alternate days till complete wound healing. Postoperatively, all the dogs were administered with intramuscular inj. Meloxicam @ 0.2 mg/kg body weight once daily for 3 days and inj. Ceftriaxone Sodium+ Tazobactam @ 20 mg/kg body weight twice daily for 5 days postoperatively. An oral calcium supplement was advised @ 2-3 tsp twice a day for three weeks in all cases. The owners were advised to restrict the movement and activities of dogs for first 2-3 weeks. Postoperatively, all the dogs were evaluated at regular interval. PPET pins were removed in selected cases after complete radiographic healing of fractured bone.

RESULTS AND DISCUSSION

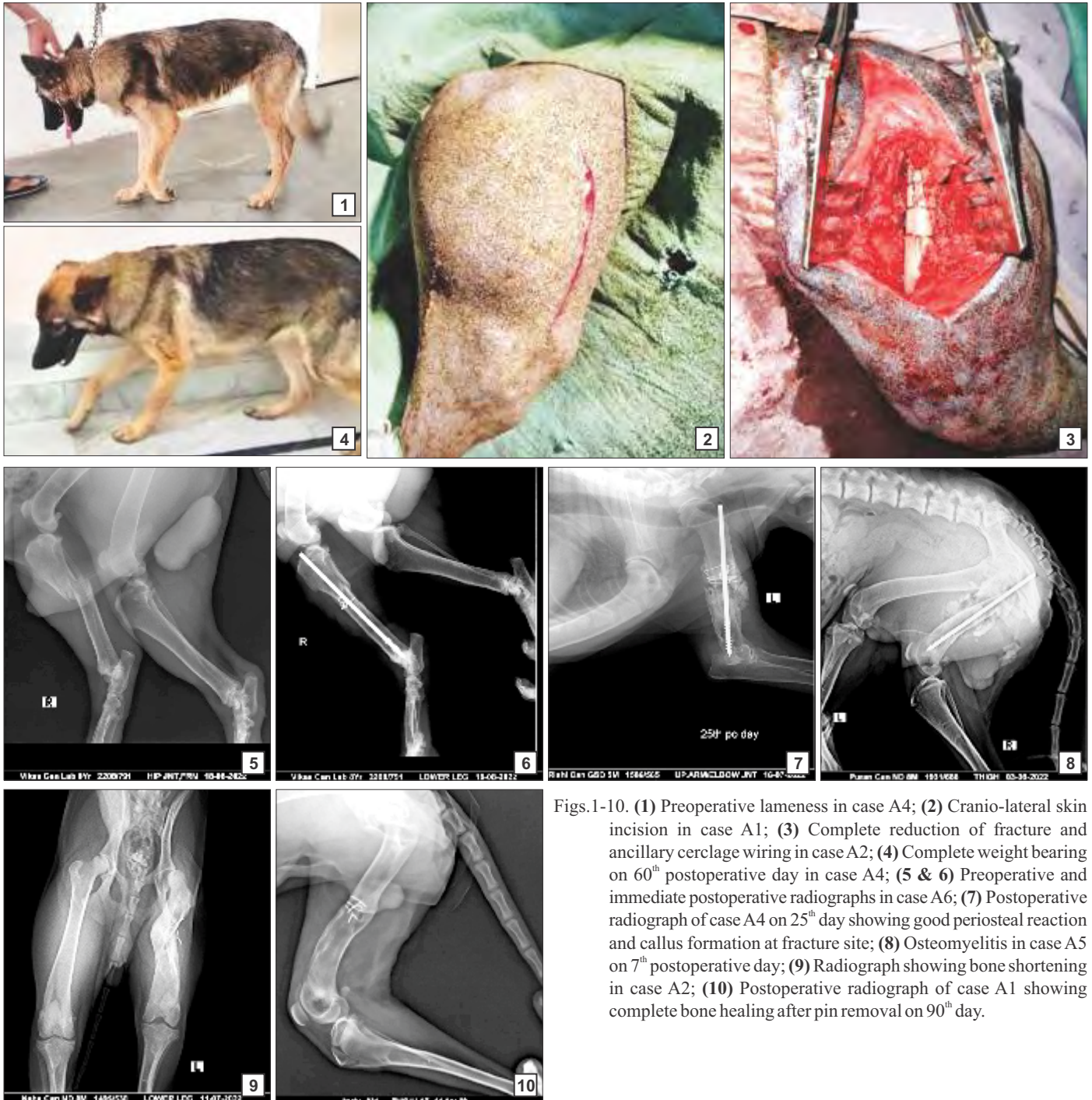
In the present study, the dogs presented with the fracture of long bones belonged to Non-descriptive, Labrador, German shepherd and Pakistani bully breeds with 33.33, 33.33, 16.66 and 16.66% report, respectively. Patil *et al.* (2018) also recorded more incidence in non-descript breed followed by German shepherd and Labrador dogs. However, the breed of dogs may vary on

the area of study Kushwaha *et al.* (2011). Males (66.66%) were more affected than females (33.33%). Similar findings have also been reported by Satish (2018), Abd El Raouf *et al.* (2019), Kumar (2019) and Yadav (2022). Patil *et al.* (2018) opined that, the population of male dogs was more as the people prefer to rear male dogs as companion animals compared to female dogs which could have impact on such a trend. Dogs having age below 12 months (83.33%) were more prone to fractures with 20.67±15.08 months mean age of the dogs. Similar, findings were recorded by Patil *et al.* (2018); Rajendra (2018); Abd El Raouf *et al.* (2019); Sodhi *et al.* (2021) and Yadav (2022). The mean weight of dogs was 15.42±3.39 kg. Kumar (2018) and Rajendra (2018) recorded similar findings. The etiology responsible for fracture was automobile accident in 50% cases, fighting among animals in 33.33% cases and fall from height in 16.66% cases. Kallianpur *et al.* (2018); Kumar (2018) and Palli *et al.* (2020) recorded similar observation of etiology. Highest affected limb was right hind limb (66.66%). These findings were in agreement to Kumar (2018) and Abd El Raouf *et al.* (2019). In the present study, femur was involved in three (50%) cases, tibia in two (33.33%) cases and humerus in one (16.66%) case. Similar observation recorded by Kumar (2018); Patil *et al.* (2018); Rajendra (2018) and Abd El Raouf *et al.* (2019). Highest fracture was of comminuted (66.66%) type followed by oblique (33.33%) type. In 66.66% fractures of the proximal third and 33.33% of mid shaft of bone was affected. However, Kushwaha *et al.* (2011) reported location of fracture in long bone as highest at distal followed by mid and proximal shaft. Contrary to it, Kallianpur *et al.* (2018) observed highest occurrence of transverse fracture followed by oblique and comminuted.

Immediate postoperative radiographs showed good reduction of fracture fragments in all the animals with minor fracture gaps (Fig. 6). First weight bearing of the affected limb was noticed on mean 5.50±1.52 postoperative days (Table 2). Normal function of the limb was restored by 30th postoperative day in cases A1, A2, A3 and A6 whereas; in cases A4 and A5 mild lameness was noticed which was due to neurological injury and split of proximal fracture fragment, respectively. All of the animals showed normal ambulation of the affected limb by

Table 3. Radiographic observations in all the cases

S. No.	Reduction of fracture fragment	Position of implant	Initial periosteal reaction (2-4 weeks)	Radiographic healing grade	Radiographic healing outcome	Limb function outcome
1.	Good	Excellent	Full	2	Complete union (9 weeks)	Excellent (6 weeks)
2.	Excellent	Excellent	Moderate	1	Complete union (10 weeks)	Excellent (8 weeks)
3.	Excellent	poor	Full	1	Complete union (6 weeks)	Excellent (6 weeks)
4.	Good	Excellent	Full	1	Complete union (7 weeks)	Good (10 weeks)
5.	Slight overriding	Excellent	mild	3	Moderate bridging (12 weeks)	Fair (10 weeks)
6.	Slight overriding	Good	Full	1	Complete union (8 weeks)	Excellent (7 weeks)



Figs.1-10. (1) Preoperative lameness in case A4; (2) Cranio-lateral skin incision in case A1; (3) Complete reduction of fracture and ancillary cerclage wiring in case A2; (4) Complete weight bearing on 60th postoperative day in case A4; (5 & 6) Preoperative and immediate postoperative radiographs in case A6; (7) Postoperative radiograph of case A4 on 25th day showing good periosteal reaction and callus formation at fracture site; (8) Osteomyelitis in case A5 on 7th postoperative day; (9) Radiograph showing bone shortening in case A2; (10) Postoperative radiograph of case A1 showing complete bone healing after pin removal on 90th day.

the 60th postoperative day (Fig. 4). Limb function outcome was excellent, good and fair with 66.67%, 16.67% and 16.67% cases, respectively. On 20-25th postoperative day, all the dogs showed good periosteal callus formation at the fracture site (Fig. 7). On the 40th postoperative day, when the full function of the limb appeared to have been restored, complete bridging periosteal callus was observed in all the patients. Initial periosteal reaction (2-4 weeks) was full (66.67%), moderate (16.67%) and mild (16.67%). Grade of radiographic healing at the time of complete weight bearing was 1.5±0.34 (Table 3). Radiographic healing outcome signified by, complete union (83.33%) and moderate union (16.67%) with mean time period 8.67±0.88 weeks was observed. These radiographic observations were in accordance with Yadav (2022). The implants were removed in three cases after 60th post-operative day. In cases A2 and A5 slight migration of intramedullary pin was noticed but in addition to exuberant callus at the fracture site it resulted in mild lameness in case A5. Mild osteomyelitis was noticed in case A2 and A5 (Fig. 8) during 4th and 7th postoperative day respectively and was subsided by administration of antibiotics. Similar findings were observed by Yadav *et al.* (2023). Complete radiographic healing was noticed in all the cases by 60th postoperative day (Fig. 10). Bone shortening was noticed in case A2 (Fig. 9), complications like non-union and mal-union were not noticed in any of the case under study. Moderate amount of external callus was noticed in majority of cases and this could be attributed to lack of complete rigid fixation at the fracture site due to pin migration and selection of young animals in the study. Piermattei *et al.* (2006) stated that, the young animals show excess callus at the fracture site though the fracture fixation was rigid. Palli *et al.* (2020) opined that, early fracture healing was noticed in majority of the cases and this could be attributed to rigid fixation achieved with the implant.

CONCLUSION

The stainless steel PPET intramedullary pins used in the present study provided rigid fixation and early fracture healing in majority of the cases with exception in two cases (slight pin migration) where it was failed because of improper postoperative management of patient by the pet owners. These complications can be avoided by proper care and management of patients postoperatively and educating the pet owners.

REFERENCES

- Abd El Raouf, M., Ezzeldeen, S.A. and Eisa, E.F.M. (2019). Bone fractures in dogs: A retrospective study of 129 dogs. *Iraqi J. Vet. Sci.* **33(2)**: 401-405.
- Fossum T.W. (2019). Principles of fracture diagnoses and management. In: Textbook of small animal surgery. Fossum TW, (5th Edn.), Elsevier Health Sciences Missouri. pp. 976-1025.
- Kallianpur, N., Singh, K., Gopinathan, A., Sarangom, S.B., John, C., Sowbharenaya, C. and Sharma, P. (2018). Investigation on relation between factors affecting occurrence and outcome of repair of long bone fractures in 216 dogs. *Intern. J. Liv. Res.* **8(2)**: 225-234.
- Kaur, A., Kumar, A., Kumar, D., Mohindroo, J. and Saini, N.S. (2015). Feasibility of C-arm guided closed intramedullary pinning for the stabilization of canine long bone fractures. *Vet. World.* **8(12)**: 1410-1415.
- Kumar B.B. (2019). Management of unstable long bone fracture with internal fixation in combination with tricalcium phosphate and autologous cancellous bone graft in dogs. M.V.Sc. thesis submitted to Birsa Agricultural University, Ranchi, India.
- Kumar R. (2018). Use of composite bone graft in long bone fracture healing stabilized by intramedullary pinning in canines. M.V.Sc. thesis submitted to Rajasthan University of Veterinary and Animal Sciences, Bikaner, India.
- Kushwaha, R.B., Gupta, A.K., Bhadwal, M.S., Kumar, S. and Tripathi, A.K. (2011). Incidence of fractures and their management in animals: a clinical study of 77 cases. *Indian J. Vet. Surg.* **32(1)**: 54-56.
- Palli, R.K., Devi Prasad, V., Makkena, S., Venkata Naidu, G. and Raju N.K.B. (2020). Evaluation of stainless-steel positive profile end threaded intramedullary pins for management of long bones fractures in dogs. *Pharma Innov.* **9(3)**: 397-401.
- Parashar, M.C., Singh, S., Singh, Y.P. and Kumar, V. (2020). End threaded intramedullary pinning for the management of femoral fracture in a dog. *Intern. J. Liv. Res.* **08(01)**: 31-33.
- Patil, M., Desai, S.B.V., Kasaralikal, V.R., Ramesh, B.K. and Tikare, V.P. (2018). Prevalence of fracture in animals in Karnataka state: four years study. *Intern. J. Liv. Res.* **8(3)**: 196-205.
- Perren, S.M. (2002). Evolution of the internal fixation of long bone fractures. *J. Bone Jt. Surg.* **84(B)**: 1093-1110.
- Piermattei, D., Flo, G. and DeCamp, C. (2006). Fractures: Classification, Diagnosis, and Treatment. In: Brinker, Piermattei, and Flo's Handbook of Small Animal Orthopedics and Fracture Repair. (4th Edn.), Saunders Elsevier, Missouri, USA, pp. 25-159.
- Rajendra, M.S. (2018). Evaluation of string of pearls interlocking plate with or without platelet rich plasma for repair of long bone fracture in canine. M.V.Sc. thesis submitted to Maharashtra Animal and Fishery Sciences University, Nagpur, India.
- Satish, R.M. (2018). Comparative evaluation of biphasic calcium phosphate as an osteoconductive and platelet rich fibrin as an osteoinducer for osseointegration in repair of long bone fracture with bone loss in dogs - a clinical study. Ph.D. thesis submitted to Maharashtra Animal and Fishery Sciences University, Nagpur, India.
- Shivhare, M., Tyagi, S.K., Malik, V., Kumar, V., Singh, C.K. and Singh, P.K. (2023). Evaluation of End-threaded Positive and Negative Profile Intramedullary Pins for Management of Long Bone Fractures in Dogs. *Indian J. Anim. Res.* **B-5029**: 1-7.
- Singh, S., Kumar, A., Kumar, A., Tyagi, S.P. and Sharma, M. (2022). Intramedullary implant fixation for management of diaphyseal fractures of humerus in dogs. *Haryana Vet.* **61(SI)**: 9-13.
- Sodhi, H.S., Kumar, A., Anand, A., Sangwan, V. and Singh, O. (2021). Comparison of titanium elastic nailing and end-threaded intramedullary pinning for distal femoral fractures in young dogs. *Indian J. Anim. Res. Online First Article*, (Article id: **B-4454**): 1-8.
- Yadav, B. (2022). Comparative evaluation of positive profile end threaded intramedullary pinning and elastic nailing technique for femoral fracture in dogs. M.V.Sc. thesis submitted to Rajasthan University of Veterinary and Animal Sciences, Bikaner, India.
- Yadav, B., Parashar, M.C., Singh, Y.P. and Singh, S. (2023). Evaluation of positive profile end threaded intramedullary pins for the repair of femur fractures in dogs. *Haryana Vet.* **62(SI)**: 61-64.