

## A NOVEL APPROACH FOR MANAGEMENT OF PARAPHIMOSIS IN A BULLYKUTTA DOG

M. PALANISAMY\*, M. SELVARAJU, S. MANOKARAN<sup>1</sup>, D. GOPIKRISHNAN,  
A. GANESAN<sup>2</sup> and M. PERIYANNAN<sup>3</sup>Department of Veterinary Gynaecology and Obstetrics, <sup>1</sup>Department of Clinics,  
Veterinary College and Research Institute, Namakkal, Tamil Nadu<sup>2</sup>Department of Veterinary Gynaecology and Obstetrics,  
Veterinary College and Research Institute, Tirunelveli, Tamil Nadu<sup>3</sup>Veterinary Dispensary, Thondi, Ramanathapuram-623 403, Tamil Nadu

Received: 11.03.2023; Accepted: 15.05.2023

## SUMMARY

The present case describes a new approach to prevent recurrence and management of paraphimosis in a 7-month-old male *Bully Kutta* dog. The case was treated with a surgical procedure aimed at repositioning the penis, maintaining urethral patency, and compromising breeding value. The animal recovered uneventfully without much complications.

**Keywords:** Bully Kutta dog, Paraphimosis, Surgical procedure

**How to cite:** Palanisamy, M., Selvaraju, M., Manokaran, S., Gopikrishnan, D., Ganesan, A. and Periyannan, M. (2023). A novel approach for management of paraphimosis in a Bullykutta dog. *Haryana Vet.* 62(2): 150-151.

Congenital and acquired penile and preputial abnormalities are common in large breed of dogs; they often predispose the stud male dogs to various complications like urinary dysfunction and breeding failure in young to mid aged dogs (Singh *et al.*, 2019). Usually the surgical interventions of penile and preputial defects need to be aimed at correcting or preventing urinary dysfunction rather than restoring reproductive performance (Papazoglou and George, 2002). The present case explicates the successful surgical management of paraphimosis in a Bully Kuttadog.

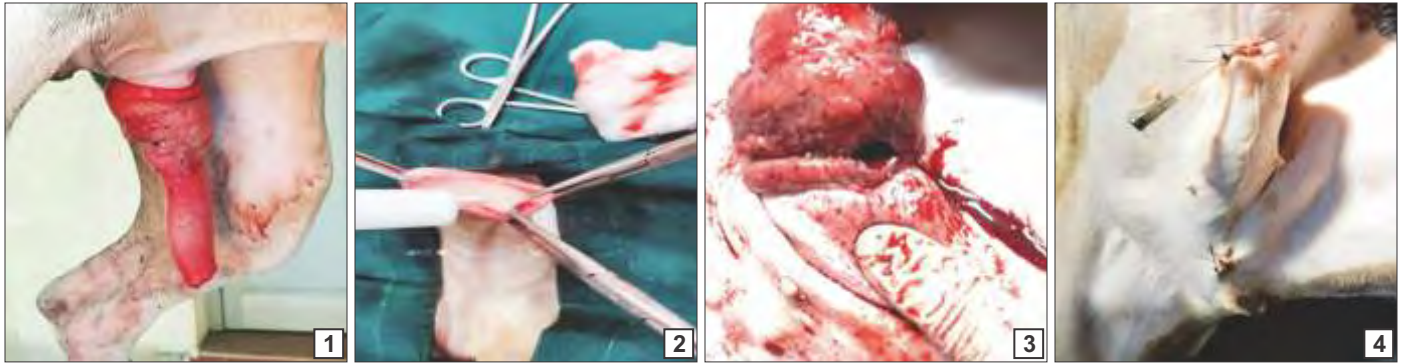
A sexually intact seven-month old Bully Kutta dog weighing 28 Kg was presented to the Veterinary Clinical Complex, Namakkal with the history of persistent penile protrusion from the preputial sheath a day before the presentation to the ward and failed to achieve detumescence resulting in persistent penile erection beyond 24 hours. Visual inspection of penis revealed severe erythema, edema and self-mutilated contusions over the pars longa part of penis (Fig. 1). Hematological examination revealed reduced hemoglobin and elevated serum Alkaline Phosphatase and the serum biochemical parameters were within the physiological limits on both day 0 and 10 (Table 1).

The surgical procedures were aimed at preserving the penile and preputial tissues by manual repositioning and reducing the size of preputial ring by applying a modified purse-string suture pattern so that the anatomical architecture of the tissues was preserved. Briefly, for manual repositioning of penis into prepuce, the dog was pre anaesthetized with Inj. Atropine Sulphate (0.04 mg/Kg body weight) administered subcutaneously

and Inj. Xylazine hydrochloride (1 mg/Kg body weight) administered intramuscularly. Anaesthesia was induced with Inj. Diazepam at 0.25 mg/Kg and Inj. Ketamine hydrochloride at 5 mg/Kg intravenously (0.25 mg/Kg body weight) and maintained with Inj. Ketamine hydrochloride at 5 mg/Kg was administered intravenously.

Initially the penis was washed with normal saline and lubricated with 4% glycerine, then the constricted preputial cavity was raised and the penis was repositioned into the prepuce. Inj. Streptopenicillin was infused into the prepuce to prevent adhesion between prepuce and penis, followed by reduction of preputial opening by application of a modified purse-string suture (Fig. 2). After manual repositioning of penis into the preputial cavity, the dog was presented with a history of recurrence of penile protrusion of penis and preputial bleeding from the prepuce. Since the manual repositioning failed; it was decided to perform castration followed by modified purse-string suture by maintaining the urethral patency. Briefly, the anaesthesia was induced administered by diazepam at a dosage of 0.25 mg/Kg and Inj. Propofol at a dosage of 4 mg/Kg intravenously and maintained with Inj. Propofol at 2 mg/Kg intravenously. The lacerations in the bulbous part of penis were sutured with 1-0 catgut and by retaining the patency of urethra was maintained by fixation of the urinary catheter (Fig. 3). Castration was performed by through a pre-scrotal approach by adopting standard procedures (Fig. 4). For postoperative treatment the animal was treated with Inj. Ceftriaxone at 15 mg/Kg B.Wt. intravenously and Inj. Tramadol at a dosage of 2 mg/Kg B.Wt. subcutaneously for three days. and as a post operative follow up therapy Tab. Cefpet (Cefpodoxime

\*Corresponding author: drmpamy@gmail.com



Figs. 1-4. (1) Strangulated penis on day 0. (note the prepuce constricting the penis at the level of bulbous glandis); (2) Infusion of streptopencillin to prevent the adhesion; (3) Presence of lacerations in the bulbous part of penis; (4) Surgical reposition and castration to prevent the recurrence.

**Table 1. Haemato-biochemical changes**

Parameter	Day 0	Day 10
Haemoglobin (g/dL)	9.7	12.8
PCV (%)	34.4	33.9
RBC (106/ $\mu$ l)	4.82	5.6
WBC (103/ $\mu$ l)	18	20.53
Neutrophils (%)	78	80
Lymphocytes (%)	20	18
Monocytes (%)	2	2
Platelet Count(105/ $\mu$ l)	7.94	7.26
Total Protein(g/dL)	6.06	6.1
Albumin (g/dL)	3.19	3.34
Serum Alkaline Phosphatase SAP(U/L)	316	26.6
BUN (mg/dL)	10.6	14.8
Creatinine (mg/dL)	0.6	0.8
Phosphorus (mg/dL)	7.78	8.9
Glucose (mg/dL)	146	98

Proxetil @ 5 mg/Kg body weight), Tab. Prednisolone (@ 0.5 mg/Kg B.Wt.), Tab. Grillinctus (Terbutaline sulphate) 2.5 mg/ total dose was also prescribed for five days. An Elizabethan collar was recommended to prevent self-mutilation. Animal recovered uneventfully without much complications.

Paraphimosis is a common urologic emergency that occurs after penile tumescence becomes trapped in the

constricted prepuce, which often leads to strangulation of the glans and painful vasoconstriction, distal venous congestion, edema, and even necrosis. The exposed penile tissue undergoes ischemia, dryness and excoriation preventing spontaneous retraction of penis (Kustritz, 2001). Paraphimosis requires immediate surgical interventions to prevent life threatening penile and urethral injuries. Therefore timely surgical management is extremely important to prevent recurrence and fatal injury. Recurrent penile affections can only be prevented by castration i.e., by removal of hormonal sources. It can be concluded that prevention of urinary dysfunction must be the most important step rather than maintaining the breeding value of the dogs (Bielas and Szulańczyk-Mencel, 2009).

## REFERENCES

- Papazoglou, L. and George, K. (2002). Surgical conditions of the canine penis and prepuce. *Compend. Contin. Educ. Vet.* **24(3)**: 204-219.
- Kustritz, M.V.R. (2001). Disorders of the canine penis. *Vet. Clin. North Am. Small Anim. Pract. Vet.* **31(2)**: 247-258.
- Bielas, W. and Szulańczyk-Mencel, K. (2009). Disorders of the penis and foreskin: dogs and cats. *Weterynaria w Praktyce* **6(1/2)**: 30-35.
- Singh, G. Dutt, R., Kumar, S., Kumari, S. and Chandolia, R.K. (2019). Gynaecological problems in she dogs. *Haryana Vet.* **58(SI)**: 8-15.