

**HORMONAL MANAGEMENT OF FOLLICULAR CYST IN A SHE DOG**

JAHANVI SHARMA, PURURAVA SHARMA\*, HARISH KUMAR, VIJENDER NEGI, AKSHAY SHARMA,  
PRAVESH KUMAR and PANKAJ SOOD

Department of Veterinary Gynaecology and Obstetrics,  
DGCN College of Veterinary and Animal Sciences, Palampur, Himachal Pradesh

Received: 19.05.2023; Accepted: 30.07.2023

**SUMMARY**

A she dog with history of vaginal bleeding since last one month was presented to the clinical complex. During anamnesis, she had undergone the surgery of tubal ligation, apart from this, normal feeding, urination and defecation was reported by the owner. Clinical examination revealed clotted blood in vaginal region albeit no growth was detected on per vaginal examination. The result of exfoliative vaginal cytology indicate the presence of the superficial and keratinized epithelial cells with 130-ohm vaginal electrical resistance. Based on B-mode transabdominal ultrasonography, the she dog was diagnosed with follicular cyst and therapeutically managed with human chorionic gonadotropin (hCG).

**Keywords:** Follicular cyst, Human Chorionic Gonadotropin, She dog, Vaginal leeding

**How to cite:** Sharma, J., Sharma, P., Kumar, H., Negi, V., Sharma, A., Kumar, P. and Sood, P. (2023). Hormonal management of follicular cyst in a she dog. *Haryana Vet.* 62(2): 157-158.

Canine breeding has emerged as a popular hobby across the globe with significance of dog as a companion to human beings (Singh *et al.*, 2019). Cystic conditions of ovaries have been reported in canines. Follicular cysts are the fluid filled structures on the surface of ovary and show great variation in size. They are anovulatory, mostly occur singly, surrounded by a granulosa cell lining, having diameter of 1-1.5cm and secrete considerable amounts of estrogen (>20pg/ml). Higher prevalence is noted in she dogs < 3 years of age (Sridevi, 2015) and are believed to occur due to failure of release of luteinizing hormone (LH) or inability of the Graffian follicle to respond to LH (Lopate and Foster, 2010). The size of follicle at the time of ovulation vary from 9 to 12 mm in diameter (Concannon, 2009). The diameter of follicular cyst shows great variation ranging from a few mm up to 300 mm (Ervin and Homanns, 1986). Ovarian cysts primarily occur in intact she dogs, however, formation of cystic structures has also been reported in the remnants of canine and feline ovaries. Due to increased estrogen levels related to follicular cysts the she dog shows signs of prolonged behavioral estrus with vaginal bleeding, and vaginal exfoliative cytology reveals presence of superficial cells. Under estrogen dominance for more than 30-40 days, the tone of vulva changes from the turgid swelling that is the characteristic of heat to a flaccid edema. The important signs suggesting hormonal imbalance due to excessive estrogen dominance include lichenification and hyperkeratosis (Sforna *et al.*, 2003). Besides bilateral, symmetrical alopecia on the caudal aspects of thighs have been observed (Ghaffari *et al.*, 2009). It has also been found that prolonged exposure to estrogen predisposes the uterus to cystic endometrial

hyperplasia (Devi *et al.*, 2021). Amongst the various diagnostic tools, the ultrasonography can be used to diagnose follicular cysts. As far as treatment is concerned, progesterone reduces clinical signs of estrus associated with follicular cyst but not advised due to close association with cystic endometrial hyperplasia. Therefore, ovariohysterectomy is the treatment of choice but to provide the she dog with future opportunity of breeding; Gonadotropin Releasing Hormone (GnRH) @ 20-25µg IM every 24-48 hours up to 3 doses or Human Chorionic Gonadotropin (hCG) @ 22 units/kg IM every 24-48 hours, have been used successfully (Sridevi, 2015).

A she dog aged 8 years was presented at clinics of the university with history of vaginal bleeding since last one month, however, feeding, urination and defecation was normal. Also, according to owner, the she dog had undergone surgery of tubal ligation previously. On clinical examination, clotted blood could be seen in vaginal region but per no abnormal growth was felt on per vaginal examination. Using ovulation detector (Draminiski®) 130 vaginal electrical resistance was measured, usually seen during estrus. Vaginal cytology revealed superficial and keratinized squamous cells (Fig. 1). On trans-abdominal sonography, a cyst of 23.4×24.7 mm was seen (Fig. 2) diagnosed as follicular cyst.

For therapeutic management, the she dog was treated with a three dose treatment protocol of hCG i.e. 700 IU in divided doses of 350 IU via intravenous and intramuscular route at 72 hours interval. The she dog responded to treatment successfully as sonographic examination a week later revealed complete resolution of cyst with no vaginal bleeding thereafter (Figs. 3 and 4).

\*Corresponding author: pururavasharma@gmail.com

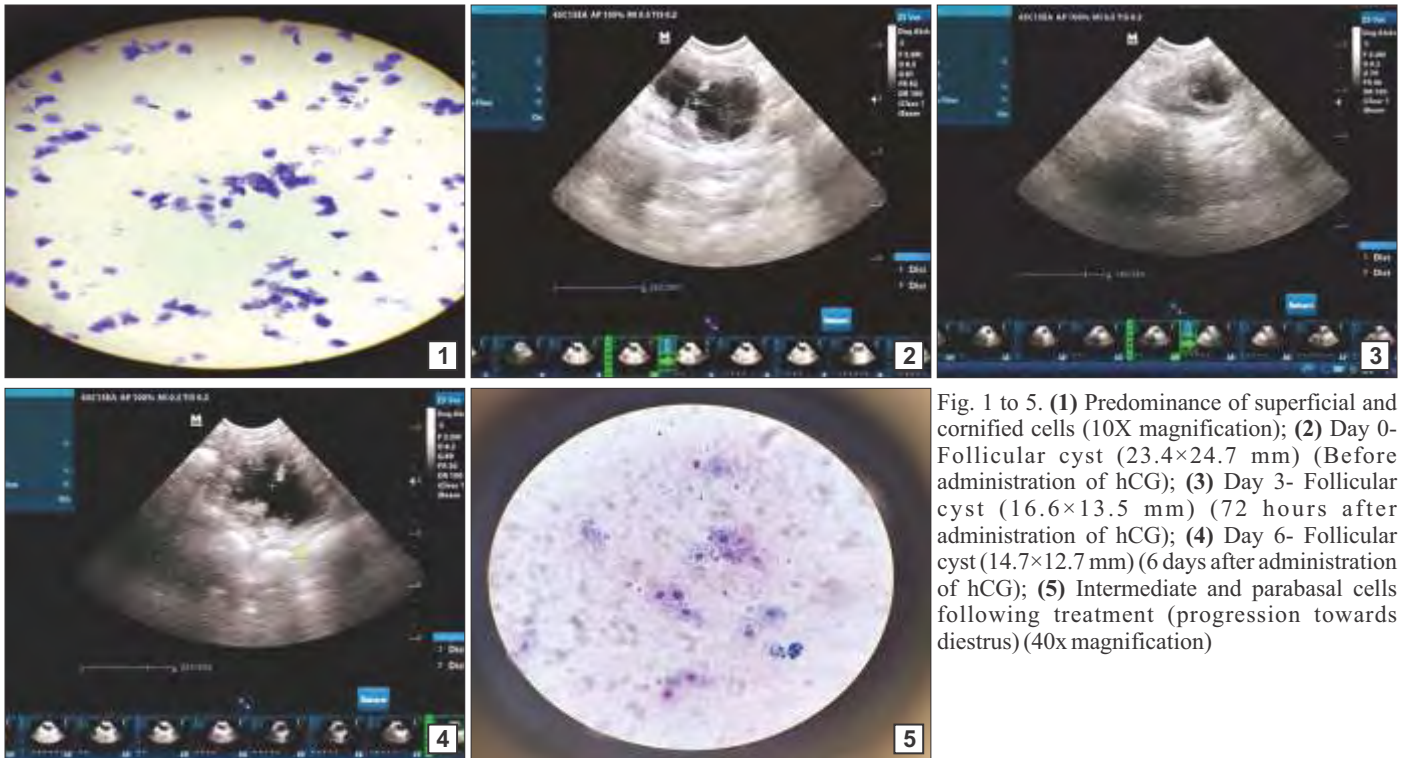


Fig. 1 to 5. (1) Predominance of superficial and cornified cells (10X magnification); (2) Day 0- Follicular cyst (23.4×24.7 mm) (Before administration of hCG); (3) Day 3- Follicular cyst (16.6×13.5 mm) (72 hours after administration of hCG); (4) Day 6- Follicular cyst (14.7×12.7 mm) (6 days after administration of hCG); (5) Intermediate and parabasal cells following treatment (progression towards diestrus) (40x magnification)

Also, the vaginal cytological picture showed parabasal and intermediate cells indicating progression towards diestrus (Fig. 5). In the outcome, hormonal therapy proved to be an implicit tool in the treatment of follicular cysts, as hCG administration offers an economical and plausible approach taking into consideration the future breeding value of the she dog avoiding any unnecessary surgical intervention.

## REFERENCES

- Concannon, P.W. (2009). Endocrinologic control of normal canine ovarian function. *Reprod. Domest. Anim.* **44**(2): 3-15.
- Devi, M.K., Arunmozhi, N., Rangasamy, S., Prabu, C., Umamageswari, J., Sridevi, P. and Pugazharasi, C. (2021). Management of follicular cyst associated with cystic endometrial hyperplasia in a Labrador she dog. *Haryana Vet.* **60**(1): 157-159.
- Ervin, E. and Homans, P. (1986). Giant ovarian cyst in a bitch. The Compendium on continuing education for the practicing veterinarian. **8**(10): 698-700.
- Ghaffari, S.M., Dezfoulian, O., Aldavood, S.J. and Masoudifard, M. (2009). Estrogen-related alopecia due to polycystic ovaries in a terrier dog. *Comp. Clin Path.* **18**: 341-343.
- Lopate, C. and Foster, R. (2010). Ovarian disease in the dog: perspectives and treatment options. *Clin. Theriogenol.* **2**(3): 169-176.
- Sforna, M., Brachelente, C., Lepri, E. and Mechelli, L. (2003). Canine ovarian tumours: a retrospective study of 49 cases. *Vet. Res. Commun.* **27**(1): 359-361.
- Singh, G., Dutt, R., Kumar, S., Kumari, S. and Chandolia, R.K. (2019). Gynaecological problems in she dogs. *Haryana Vet.* **58**: 8-15.
- Sridevi, P. (2015). Canine Reproduction. The theory and practice. (1<sup>st</sup> Edn.), Active Ads & Printers Pvt. Ltd., Hyderabad. 150-151.