

COMPARING AND CORRELATING ULTRASOUND FEATURES OF UDDER, TEATS AND SUPRAMAMMARY LYMPHNODES IN HEALTHY AND MASTITIC CROSS BRED DAIRY COWS

PARDEEP SHARMA*, KANIKA BHARDWAJ, ADARSH KUMAR¹, RAKESH THAKUR²

Department of Veterinary Medicine, ¹Department of Veterinary Surgery & Radiology,

²Department of Livestock Farm Complex,

Dr. G.C. Negi, College of Veterinary & Animal Sciences, Choudhary Sarwan Kumar
Himachal Pradesh Agricultural University, H.P., India

Received: 27.01.2023; Accepted: 24.05.2023

ABSTRACT

The clinical, morphometric and sonographic assessment of the udder, teat and supramammary lymph node in forty-seven crossbred jersey cows {normal (n=10); subclinical mastitis (n=12) and clinical mastitis (n=25)} was performed. Hyperechoic echotexture of udder parenchyma and lactiferous tissue was observed in clinical mastitis. Teat wall and teat sinus appeared hyperechoic in clinical mastitis and anechoic to hypoechoic in healthy and subclinical mastitis. Teat cisternae width (TCW) decreased significantly ($p < 0.01$) in subclinical as well as clinical form of mastitis in comparison to healthy quarters. Non-significant decrease in teat canal length (TCL), teat end width (TEW) and teat wall thickness were observed. Supramammary lymph nodes width and length increased significantly ($p < 0.05$) in clinical form of mastitis as compared to healthy animals. In case of subclinical mastitis, supramammary lymph nodes length increased non-significantly ($p > 0.05$) while width increased significantly ($p < 0.05$). Various patterns of vascularity were observed in supramammary lymph nodes in infected animals and increased vascularity of lymph nodes was observed in clinical mastitis cases. Among teat parameters, teat canal length (TCL) was significantly increased ($p < 0.05$) in bovines of more than eight years age (1.39 ± 0.01 cm) when compared to the bovines of two to four years (1.12 ± 0.06 cm) and five to eight years (1.01 ± 0.05 cm). Lymph node width (LNW) seemed to be unaffected by age, parity, and stage of lactation risk factors. The results of this study provided the baseline information regarding udder, teat and supra-mammary lymph node morphometry in healthy, subclinical and clinical mastitis cases and it is concluded that non-invasive ultrasonographic methods can verify the existing mastitis situation in dairy cows and can be used as preventive measures to timely diagnose and control bovine mastitis in dairy herds.

Keywords: Doppler, Echogenicity, Lactating cattle, Mammary gland, Sub-clinical

How to cite: Sharma, P., Bhardwaj, K., Kumar, A. and Thakur, R. (2023). Comparing and correlating ultrasound features of udder, teats and supramammary lymphnodes in healthy and mastitic cross bred dairy cows. *Haryana Vet.* 62(2): 14-19.

Mastitis, the most prevalent production disease in the dairy herds, is defined as an inflammation of the mammary gland predominantly caused by the bacterial and unknown pathogens. It is a common health problem in lactating dairy cows; a serious animal welfare issue that causes huge economic loss to the dairy farmer in terms of reduction in the milk production, milk wastage and treatment cost. Pathological changes decrease the functional capacity of udder, lactiferous tissue, and cause agalactia in severe cases. Indirect diagnostic tests for subclinical mastitis are California mastitis test (CMT), somatic cell count (SCC) and bacterial culture, however these tests are time consuming and are laborious methods. The CMT, is a rapid, early screening qualitative measurement of SCC in milk of infected quarters is useful in preventing mastitis in early lactation (Wallace *et al.*, 2002) however, CMT relies only on visual observation, the results are often subjective. To overcome this issue quick, advanced confirmatory tests such as ultrasonographic examination for diagnosing mastitis are needed. The losses caused by mastitis have been reduced to some extent in countries where such modern husbandry techniques and diagnostics are used, but there is a need for a reevaluation of mastitis in the light of non-invasive diagnostic techniques such as ultrasonography.

Ultrasonographic teat and udder measurements in modern husbandry of dairy cattle, could act as an intensive control and preventive measures against mastitis. Ultrasonographic examination is made with 5-10 MHz frequency scanner to study teat and glandular parenchyma structures in standing animal (Franz *et al.*, 2009). Ultrasonographic techniques can be used to determine the intramammary factors that may lead to the development of mastitis and these factors should be taken into consideration in the control and prevention of mastitis. On perusal of the available literature, ultrasonographic studies have been done in udder and teat disorders in cows but no standard measurements for future references on changes in udder, teats and supramammary lymph nodes in different form of mastitis has been done. This study was therefore aimed to provide the ultrasonographic appearance and measurements of udder, teat and supramammary lymph nodes in subclinical and clinical mastitis and its relation to healthy animals. In addition to this, the effect of age, parity, stage of lactation on ultrasonographic measurements in healthy and mastitis animals was also studied.

MATERIAL AND METHODS

Study design and Sample collection

The present study was carried out in 47 cross bred

*Corresponding author: docpradeepsharma@gmail.com

jersey bovines {Healthy animals (n=10); Subclinical mastitis (n=12) and Clinical mastitis (n=25)} of Livestock Farm Complex and bovine patients suffering from various teat and udder affections presented to Veterinary Clinical Complex, College of Veterinary and Animal Sciences, Palampur. These animals were subjected to systemic evaluation for the diagnosis of disease condition using California mastitis test (CMT) and further ultrasonographic measurements and studies of udder, teat and supramammary lymph node structures. The age of these cows varied between 4 and 14 years. Permission from the owners of the animals was obtained to use the clinical information in the current study.

Laboratory Diagnosis: California Mastitis Test (CMT)

A plastic milk paddle with 4 shallow cups was taken. The cups were marked as left-fore (LF), left-hind (LH), right-fore (RF) and right-hind (RH). Five ml milk sample from each separate teat was taken in paddle and mixed with 5 ml CMT reagent in swirling motion. The mixture was examined for precipitation or gel formation. Description of the visible reaction interpretation is given below (Table 1).

Table 1. Description of the visible reaction interpretation

Observation	Infection Index
Mixture remains liquid, no traces of precipitate	0 (Negative for mastitis)
Traces of precipitate which tend to disappear with movement of paddle	1 (Subclinical mastitis)
Mixture of thick gel and on circular motion it tends to move towards centre and distinct gel formation	2, 3 (Clinical mastitis)

Ultrasonographic examination

Ultrasonography of teats and udder was done using Siemens Acuson X300 ultrasound system premium edition and portable Sonosite M-Turbo ultrasound system. A 5.3 to 10 MHz linear transducer was used to scan the mammary glands and associated structures such as udder parenchyma, teats and supramammary lymph node (SMLN). Scanning was conducted by transcutaneous and water bath techniques (Sendag and Dinc, 1999). Water bath technique included dipping of the teat in a plastic cup filled with warm water having a temperature of 37°C. This technique has been shown to improve image quality (Santos, 2004). The anatomical position of supramammary lymph nodes was found in accordance with the descriptions given by Bradley *et al.* (2001). Animal was prepared by shaving the coarse hair on the udder and skin over supramammary lymph node. Coupling gel (Rison ultrasound gel, Pioneer

Surgeon product, Delhi) was liberally applied on udders and supramammary lymph node followed by thorough ultrasonographic examination of udder parenchyma and lymph nodes. Length (LNL) and width (LNW) of lymph nodes was measured. Vascular pattern of lymph nodes was also recorded.

Transverse and longitudinal ultrasound images of the udders and teats were obtained. The ultrasound images were recorded using a portable flash disk through a USB port. Digital analysis of the ultrasonograms obtained was conducted using Adobe Photoshop 10.0 (Adobe system Inc., 1990-2007). Following the clinical examination, ultrasonographic measurements were taken to determine teat canal length (TCL), teat end width (TEW), teat wall thickness (TWT), and the teat canal width (TCW). Teat canal length (TCL) was measured from the level of Furstenberg’s rosette to the tip of teat. Teat end width (TEW) was measured on the level of Furstenberg’s rosette. Teat cisternae width (TCW) and Teat wall thickness (TWT) was measured at point one cm proximal to Furstenberg’s rosette. These measurements were recorded and documented.

Statistical analysis

Microsoft Excel was used to determine significant difference between parameters. For comparison of ultrasonography teat parameters between healthy, subclinical, and clinical mastitis results, Student’s t-test was used. The effect of length and width measurements of the supramammary lymph nodes on ultrasonography were compared between the groups. Analysis of Variance (ANOVA) was used to compare means of different groups. All statistical analyses were performed using the SPSS 26 version.

RESULTS AND DISCUSSION

CMT was utilized to classify the cows into different grades of mastitis. Cows which are classified as having no mastitis had negative results for CMT in all four quarters. Those which were classified as having subclinical mastitis had trace findings in the CMT in three or four quarters and the cows showing positive results for CMT along with physical, chemical changes in the milk and pathological changes in the glandular tissue of the udder were classified as clinical mastitis (Sharma *et al.*, 2011).

Udder ultrasonography

B-mode ultrasonographic examination of udder parenchyma in healthy udder appeared to be hypoechoic, containing anechoic milk in glandular alveoli (Figure 1a). Hyperechoic echotexture of udder parenchyma and lactiferous tissue was present in clinically affected cases of mastitis (Fig. 1b). Hypoechoic to hyperechoic fluid was

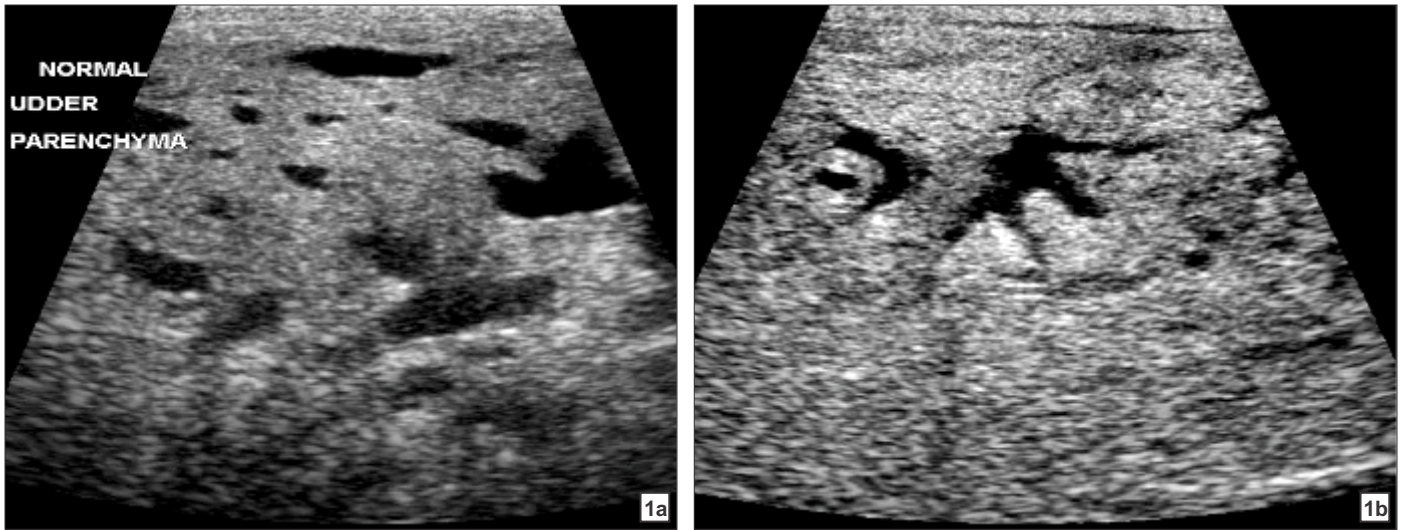


Fig. 1a. Ultrasonographic image showing hypoechoic udder parenchyma containing anechoic milk in glandular alveoli of healthy udder.
 Fig. 1b. Ultrasonographic image of udder parenchyma showing hyperechoic areas around lactiferous tissue in mastitic udder.

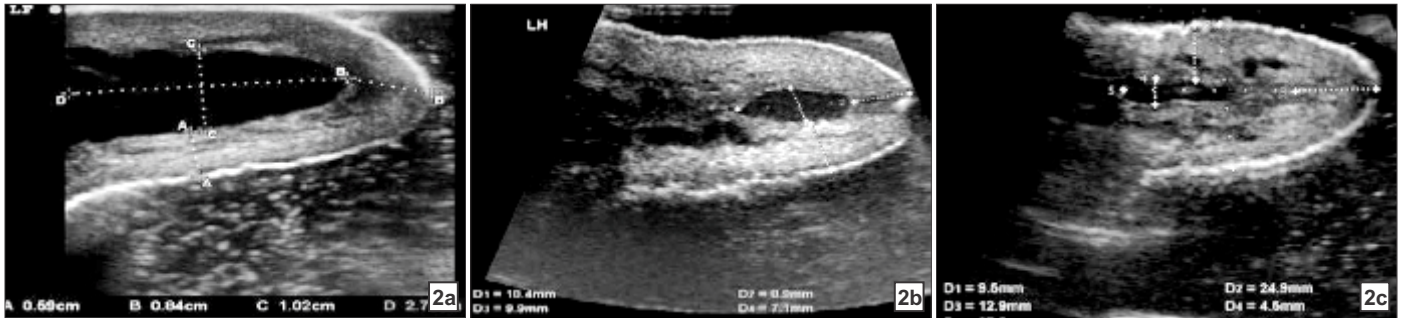


Fig. 2a-c. (2a) Ultrasonographic image of teat showing teat parameters in healthy cow. (2b) Ultrasonographic image of teat showing teat parameters in subclinical mastitis. (2c) Ultrasonographic image of teat showing teat parameters in clinical mastitis.

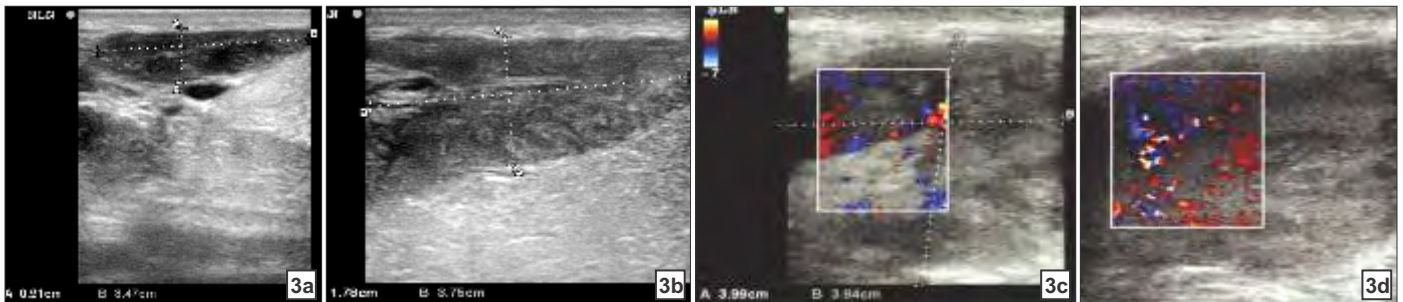


Fig. 3a-d. (3a) Ultrasonographic image of supramammary lymph node in healthy animal. (3b) Ultrasonographic image of supramammary lymph node in subclinical mastitis. (3c) Ultrasonographic doppler image of supramammary lymph node in clinical mastitis. (3d) Ultrasonographic doppler image showing increased vascularity pattern supramammary lymph node in mastitis.

Table 1. Ultrasonographic variables of teat in healthy, subclinical, and clinical mastitis (Mean ± S.E.)

CMT score	TCL (cm)	TEW (cm)	TWT (cm)	TCW (cm)	TCW:TWT
Healthy (n=10)	1.16±0.08	2.06±0.07	0.81±0.05	0.92±0.09 ^b	1.12±0.20 ^b
Subclinical (n=12)	0.99±0.13	1.82±0.12	0.78±0.05	0.56±0.11 ^a	0.60±0.14 ^a
Clinical (n=25)	1.02±0.03	1.77±0.01	0.77±0.02	0.48±0.07 ^a	0.78±0.03 ^a

Figures with different superscript (a and b) in a column differ significantly ($p < 0.05$).

present inside the glandular alveoli in subclinical and clinical mastitis. Santos *et al.* (2015) also observed similar changes in udder parenchyma in mastitis affected mammary glands. Several small hyperechoic areas in udder parenchyma were due to presence of inflammation

(Escobedo and Gill, 2018) and increased cellular contents (fibrotic tissue followed by inflammation stage). In this study, sonographic inspection revealed homogenous and hyperechoic glandular udder parenchyma which was similar with the findings of Javadi and Acorda (2011) in

Table 2. Supra-mammary lymph node measurement by ultrasonography

Type of mastitis	LNW (cm)	LNL (cm)
Normal (n=10)	1.07 ± 0.12 ^a	3.31 ± 0.10 ^a
Subclinical (n=12)	2.26 ± 0.39 ^b	3.89 ± 0.17 ^{ab}
Clinical (n=25)	3.91 ± 0.23 ^c	4.24 ± 0.22 ^b

Figures with different superscript (a, b and c) in a column differ significantly (p<0.05).

Table 3. Factors affecting ultrasonographic measurements (Mean ± S.E.)

Factors		TCL(cm)	TEW(cm)	TWT(cm)	TCW(cm)	TCW/TWT(cm)	LNW(cm)	LNL(cm)
Age in years	2 to 4 (n=19)	1.12 ± 0.06 ^a	2.12 ± 0.08	0.81 ± 0.04	0.65 ± 0.06	0.43 ± 0.03 ^a	3.14 ± 0.28	4.93 ± 0.24
	5 to 8 (n=17)	1.01 ± 0.05 ^a	1.83 ± 0.07	0.74 ± 0.03	0.67 ± 0.08	1.02 ± 0.16 ^b	3.55 ± 0.23	4.60 ± 0.30
	More than 8 (n=10)	1.39 ± 0.01 ^b	2.08 ± 0.07	0.87 ± 0.05	0.72 ± 0.16	0.94 ± 0.24 ^b	3.11 ± 0.45	4.69 ± 0.41
Parity	1 st (n=11)	1.09 ± 0.08	1.91 ± 0.17	0.80 ± 0.06	0.63 ± 0.09	0.90 ± 0.18	3.70 ± 0.34	4.44 ± 0.24 ^a
	2 nd to 4 th (n=18)	1.03 ± 0.06	2.07 ± 0.07	0.72 ± 0.03	0.74 ± 0.09	1.14 ± 0.16	3.28 ± 0.27	5.15 ± 0.26 ^{ab}
	5 th to 8 th (n=15)	1.02 ± 0.05	1.89 ± 0.08	0.72 ± 0.04	0.74 ± 0.04	1.15 ± 0.08	3.66 ± 0.26	4.31 ± 0.22 ^a
	More than 8 th (n=2)	1.08 ± 0.07	1.79 ± 0.16	0.70 ± 0.04	0.60 ± 0.03	0.70 ± 0.01	4.58 ± 0.17	5.29 ± 0.32 ^b
Stage of lactation	Early (n=22)	1.01 ± 0.08 ^a	2.03 ± 0.13	0.74 ± 0.03	0.72 ± 0.05	0.97 ± 0.02	3.43 ± 0.22	5.27 ± 0.23 ^b
	Mid (n=10)	0.98 ± 0.12 ^a	2.01 ± 0.11	0.77 ± 0.04	0.74 ± 0.11	0.96 ± 0.08	3.29 ± 0.29	4.11 ± 0.25 ^a
	Late (n=14)	1.58 ± 0.09 ^b	2.05 ± 0.09	0.78 ± 0.11	0.74 ± 0.09	0.94 ± 0.04	3.91 ± 0.34	4.71 ± 0.34 ^{ab}

Figures with different superscript (a, b) in a column differ significantly (p<0.05).

dairy cows.

Ultrasound features of teat wall and teat sinus of mastitic cows appeared hyperechoic while in cows without mastitis and with subclinical mastitis, the teat wall and teat sinus appeared anechoic to hypoechoic (Fig. 2a, 2b and 2c). Gland cistern and teat sinus contain clots in the milk of mastitic animals which could attribute to increased heterogenous echogenicity in these structures, compared to normal teats (Radositits *et al.*, 2007).

Gland sinus appeared as homogenous anechoic area and teats of non-mastitis cows on ultrasonographic examination appeared as hypoechoic structures with anechoic lumens, like that reported by Cartee *et al.* (1986).

Ultrasonographic variables of teat in mastitis

Table 1 represents the ultrasonographic teat measurements in centimetres for normal, subclinical and clinical mastitis. Results showed that teat cisternae width (TCW) decreased significantly (p<0.01) in subclinical as well as clinical form of mastitis. Percent decrease in teat cisternae width was found to be 39.13 per cent in sub-clinical mastitis and 47.82 per cent in clinical mastitis. Ratio of teat cisternae width to teal wall thickness (TCW: TWT) also decreased significantly in clinical (p<0.05) and subclinical mastitis (p<0.01). Non-significant decrease in teat canal length (TCL), teat end width (TEW) and teat wall thickness were observed. In contrast to current study, Klein *et al.* (2005) reported that teat canal length was significantly longer in healthy quarters (1.74 cm) in comparison to infected quarters (1.58 cm). Secker *et al.*

(2009) also observed similar findings related to teat cisternae width which decreased significantly at 1% level of significance. Sani *et al.* (2017) observed that there were non-significant differences (p>0.05) in TCL, TEW and TWT while ratio TCW: TWT decreased significantly (p<0.05) in subclinical cases.

Supra-mammary lymph node measurement

As shown in Table 2 and Figures 3a and 3c width

(LNW) and length (LNL) of supramammary lymph nodes (SMLN) in centimeters increased significantly (p<0.05) in clinical form of mastitis as compared to healthy animals. In case of sub-clinical mastitis, LNL increased non-significantly (p>0.05) (Fig. 3b) while LNW increased significantly (p<0.05). LNW increased by 1.12 times and 1.54 times in sub-clinical and clinical form, respectively. LNL increased by 0.17 times and 0.28 times in sub-clinical and clinical form of mastitis, respectively. There was alteration in size and dimensions of lymphnode, but no architectural changes were observed. Khoramian *et al.* (2015) also stated that size of SMLN varies with status of infection in mammary glands.

Various patterns of vascularity were observed in SMLN in infected animals. Increased vascularity of lymph nodes was also seen in clinical mastitis cases (Fig. 3d). Risvanli *et al.* (2019) also observed various types of vascular patterns in SMLN of CMT positive groups with likely reason behind increased vascularity of SMLN ipsilateral to CMT positive quarters was infection leading to proliferative increase of lymphocytes.

B-Mode and colour doppler ultrasonography are extensively used as non-invasive procedures to monitor lymph node pathologies in humans and in diagnosis of breast cancers in females (Lee *et al.*, 2002). To the best of our knowledge, such studies using the colour doppler ultrasonography methods about the evaluation of supramammary lymph nodes are not available for crossbred dairy cows in India.

In the present study, we found that supramammary lymph nodes had significantly increased length and width in the lactating cows included in the clinical mastitis group although there was a nonsignificant difference in the subclinical mastitis. This could be concluded that B- mode ultrasonography of SMLN can be used in conjunction with colour doppler (for vascular pattern) to determine condition of mastitis since mastitis leads to lymphocytic proliferation in SMLN.

Ultrasonographic measurements of teats in relation to animal physiological factors

The effect of age, parity, and stage of lactation on various ultrasonographic measurements of teat and lymph node was studied (Table 3). It was found that among teat parameters, teat canal length (TCL) was significantly increased ($p < 0.05$) in bovines of more than eight years age (1.39 ± 0.01 cm) when compared to the bovines of two to four years (1.12 ± 0.06 cm) and five to eight years (1.01 ± 0.05 cm). Similar findings with significant difference ($p < 0.01$) in TCL of younger and older age cows were reported by Celik *et al.* (2008). Too short and too long TCL could be one of the influencing reasons for mastitis in dairy herds (Seyfried, 1992). In late lactation stage teat canal length (1.58 ± 0.09 cm) was found to be increased significantly ($p < 0.05$) when compared to early (1.01 ± 0.08 cm) and mid (0.98 ± 0.12 cm) lactation stages. In relation to our study, Ludek *et al.* (2010) similarly noticed significant ($p < 0.01$) extension of teat canal in late stage of lactation by 0.16 cm immediately after milking. An increase in length of teat canal at late lactation stage might be attributed to the fact that mechanical stretch inflicted over teat throughout the lactation due to milking tends to increase teat canal length.

Lymph node width (LNW) seemed to be unaffected by age, parity, and stage of lactation risk factors. Lymph node length (LNL) was found to be increased significantly ($p < 0.05$) in bovines belonging to more than 8th parity (5.29 ± 0.32 cm) and in early stages of lactation (5.27 ± 0.23 cm). Khoramian *et al.* (2015) showed positive correlation of somatic cell count with size of supramammary lymph node. Somatic cell counts tend to be higher in early stages of lactation (Yohannes and Alemu, 2018) and in pleuriparous bovines which justifies increased size of supramammary lymph node in the current study. However, effect of the above-mentioned risk factors remained non-significant ($p > 0.05$) on teat end width, teat wall thickness, teat cisternae width, lymph node width and teat cisternae width to teat wall thickness ratio. In contrast, Seker *et al.* (2009) found significant effect of age over teat end width ($p < 0.05$).

In the present study, no significant difference was

found between teat canal length, teat end width and teat wall thickness, however teat cistern width decreased significantly in subclinical and clinical mastitis when compared to the healthy non mastitic animals. The supramammary lymphnode length and width in clinical and SMLN width increased significantly in subclinical mastitis in relation to healthy quarters. No such detailed studies to compare udder, teats and supramammary lymph nodes of healthy and mastitic animals in crossbred dairy cows was reported in the literature. The observations of the study and those of others, although conducted are for short period and are in other breeds, suggest that there is a need to repeat such study with large sample size in controlled environmental conditions. The study is unique to describe and establish the teat and supramammary lymphnode measurements in healthy and mastitic jersey crossbred cows and its correlation to age, parity and lactation number for future reference while performing mammary gland ultrasonography for screening of mastitis in dairy herds.

The study provided the baseline information regarding udder, teat and supramammary lymphnode morphometry in healthy, sub-clinical, and clinical mastitis cases and it is concluded that non-invasive ultrasonographic methods can verify the existing mastitis situation in dairy cows and can be used as preventive measures to timely diagnose and control bovine mastitis in dairy herds. These non-invasive procedures can deliver crucial information of udder, teat and supramammary lymphnodes measurements and based on this healthy animal with desirable traits could be selected for future breeding programmes which in turn could decrease mastitis incidences in dairy farms. It could also be concluded that supramammary lymph node measurement in lactating animals could timely provide an important clue for severity of mastitis in dairy herds, however, further control studies involving a greater number of mastitis cases should be performed.

REFERENCES

- Bradley, K., Bradley, A.J. and Barr, F.J. (2001). Ultrasonographic appearance of the superficial supramammary lymph nodes in lactating dairy cattle. *Vet. Rec.* **148(16)**: 497-501.
- Cartee, R.E., Ibrahim, A.K. and McLeary (1986). B-mode ultrasonography of the bovine udder and teat. *J. Am. Vet. Med. Assoc.* **188**: 1284-1287.
- Celik, H.A., Aydin, I., Colak, M., Sendag, S. and Dinc, D.A. (2008). Ultrasonographic evaluation of age-related influence on teat canal and the effect of this influence on milk yield in brown swiss cows. *Bull. Vet. Inst. Pulawy.* **52**: 245-249.
- Escobedo, O. and Gill, L. (2018). Mastitis, and the use of ultrasound in practice. *Int. Dairy Topics.* **15(6)**: 11-12. www.positiveaction.info
- Franz, S., Floek, M. and Hofmann-Parisot, M. (2009). Ultrasonography of the bovine udder and teat. *Vet. Clin. North Am. Food Anim.* **25(3)**: 669-85.

- Javadi, T. and Acorda, J.A. (2011). Ultrasound features and echo mean values of udder and teat in dairy cows with mastitis. *Philipp. J. Vet. Med.* **37(2)**: 167-176.
- Khoramian, B., Rajhi, A., Ghasemzadeh-Nava, H., Ahrari-Khafi, M.S. and Bahonar A. (2015). Ultrasonography of the supramammary lymph nodes for diagnosis of bovine chronic subclinical mastitis. *Iran. J. Vet. Res.* **16(1)**: 75-77.
- Klein, D., Khal J.L., Stüger H.P. and Baumgartner, W. (2005). Ultrasonographic measurement of the bovine teat: breed differences, and the significance of the measurements for udder health. *J. Dairy Res.* **72**: 296-302.
- Lee, S.W., Choi, H.Y., Beek, S.Y. and Lim, S.M. (2002). Role of color and power doppler imaging in differentiating between malignant and benign solid breast masses. *J. Clin. Ultrasound.* **30**: 459-464.
- Ludek, S., Frantisek, L., Jiri, B., Alena, J. and Michal, R. (2010). Changes in teat parameters caused by milking and their recovery to their initial size. *Arch. Tierz.* **53(6)**: 650-662.
- Radostits, O.M., Gay, C.C., Hinchcliff, K.W. and Constable, P.D. (2007). *Veterinary Medicine*. (10th Edn.), S.B. Saunders Company Ltd., Elsevier, London.
- Risvanli, A., Dogan, H., Safak, T., Kilic, M.A. and Ibrahim, S. (2019). The relationship between mastitis and the B-mode, colour Doppler ultrasonography measurements of supramammary lymph nodes in cows. *J. Dairy Res.* **86**: 315-318.
- Sani, R.N., Yousefi, M.H., Javan, A.J. and Hivechi (2017). Evaluation of teat ultrasound measurements for diagnosis of subclinical mastitis in Holstein dairy cow. *Philipp. J. Vet. Med.* **54(2)**: 118-123.
- Santos, D.A.S., Vicente, W.R.R., Canola, J.C. and Léga, E. (2004). B-mode ultrasonography in cows during lactation to evaluate the teat anatomy using four different techniques. *Braz. J. Vet. Res. Anim. Sci.* **41**: 350-354.
- Santos, V.J.C., Simplicio, K., Sanchez, D., Coutinho, L., Teixeira, P, Barros, F., Almeida, V., Rodrigues, L., Bartlewski, P., Oliveira, M., Feliciano, M. and Vicente, W. (2015). B-mode and doppler sonography of the mammary glands in dairy goats for mastitis diagnosis. *Reprod. Domest. Anim.* **50(2)**: 251-255.
- Seker, I, Yüker, M., Saat, N. and Ozmen, O. (2009). Relationship between California Mastitis test score and ultrasonographic teat measurements in dairy cows. *Aust. Vet. J.* **87**: 480-483.
- Sendag, S. and Dinc, D.A. (1999). Ultrasonography of the bovine udder. *Turkish J. Vet. Anim. Sci.* **23**: 545-552.
- Seyfried, G. (1992). The sonographic measurement of teat structures and the significance of udder health of 'Braun and Fleckvieh'-cows. University of Veterinary Medicine Vienna, Austria.
- Sharma, N., Singh, N.K. and Bhadwal, M.S. (2011) Relationship of somatic cell count and mastitis: an overview. *Asian-australas. J. Anim. Sci.* **24(3)**: 429-438.
- Wallace, J.A., Leslie, K.E., Dingwell, R.T., Schukken, Y.H. and Baillargeon, P. (2002). An evaluation of a diagnostic and treatment protocol for intramammary infections in early postpartum dairy cows. Published in proceedings of Annual Meet National Mastitis Council held at Orlando, Florida on 3-6 Feb 2002, pp. 159-160.
- Yohannes, K. and Alemu, B. (2018). Prevalence of bovine mastitis in lactating cows and associated risk factors in and around Wolayta Soddo, uthern Ethiopia. *Int. J. Adv. Res. Biol. Sci.* **5(12)**: 60-69.

THE HARYANA VETERINARIAN

Editors/Editorial Board Members are highly thankful to all the distinguished referees who helped us in the evaluation of articles. We request them to continue to extend their co-operation and be prompt in future to give their valuable comments on the articles for timely publication of the journal.