Haryana Vet. **46** (December, 2007), pp 19-21

Research Article

TOPOGRAPHIC RELATIONS BETWEEN THE SPINAL CORD SEGMENTS AND VERTEBRAE IN CAMEL (CAMELUS DROMEDARIUS)

R. K. JAIN[1] and A. N. GUPTA
Department of Veterinary Anatomy and Histology, College of Veterinary Sciences
CCS Haryana Agricultural University, Hisar -125 004

ABSTRACT

Bilateral retro caudal measurements of the spinal cord segments and their relations with the corresponding vertebrae were recorded in six dromedary camels. The segment length in the cervical region rapidly increased from C_1 to C_5 followed by a sharp decrease in length till T_1. Thereafter, the length of all the segments remained approximately constant till T_{12}. The lumbar region showed a remarkable decrease in the segment length from L_1 to L_7 followed by a gradual decrease from L_7 till the termination of the spinal cord at fifth coccygeal vertebra. The transverse and vertical diameters of the spinal cord were variable through out the length. The number of rootlets was directly proportional to the transverse diameter of the spinal cord. The relations between the spinal cord segments and the body, spinous processes and the transverse processes were also recorded.

Key words: Spinal cord, vertebrae, camel

The details of the topographic relations between the spinal cord and the vertebrae are important to understand the physiology of the central nervous system. These relations have been studied in cattle (Habel, 1951), sheep (Goller, 1957), goat (Sharma *et al*., 1973) and horse. However, the information in camel is lacking in the literature barring a few fragmentary reports (Hifny *et al*., 1985). Therefore, the present investigation was carried out to record the topographic relations between the spinal cord segments and the corresponding vertebrae in camel.

MATERIALS AND METHODS

During present study six apparently healthy adult camels were embalmed with 10% formalin as per standard technique. The spinal cord was exposed both ways, dorsally by laminectomy and laterally by paramedian section using an electric saw. A close search was made with naked eye and a hand lens to examine the surface and extent of the each spinal cord segment and the corresponding vertebra in the vertebral canal to establish their topographic relations.

RESULTS AND DISCUSSION

Camel possessed the longest spinal cord among the domesticated animals. It extended from the level of the foramen magnum to the end of the second sacral vertebra as reported earlier (Hifny *et al.* 1985), however, sometimes it terminated at the cranial one third of the second sacral vertebra or to sacrum. (Smuts and Bezuidenhout, 1987). Sharma and Rao (1971) reported that the termination of spinal cord took place at the middle of the sacrum in Indian buffalo while in Egyptian buffalo at the cranial limit of the third sacral vertebra (Abu-Zaid, 1982). The termination of the spinal cord in ox occurred at the level of first sacral vertebra (Habel, 1951) or at middle of the sacrum (McLeod, 1958). However, in goat the spinal cord terminated at the caudal end of the third sacral vertebra (Sharma *et al*., 1973). The average length of the spinal cord in camel was 214.02 cm. It measured 138.67 cm in Indian buffalo (Sharma and Rao, 1971), 188.65 cm in Egyptian buffalo (Abu-Zaid, 1982) and 54.5 to 56.2 cm in goat (Sharma *et al.*, 1973).

The cervical enlargement in camel extended from C_6 to T_2 as reported earlier (Hifny *et al.*, 1985) and in Indian buffalo (Abu-Zaid, 1982). In Egyptian buffalo (Abu-Zaid, 1982), it extended from C_5 to T_1 where as in sheep from C_6 to T_1 (Goller, 1957). The lumbar enlargement extended from L_6 to S_1 in camel, it extended from L_2 to S_1 in Indian buffalo (Sharma and Rao, 1971), from L_4 to S_1 in sheep and goat (Goller, 1957, Sharma *et al.*, 1973) and from L_4 to S_2 in Egyptian buffalo (Abu-Zaid, 1982).

The whole cervical part of the spinal cord

[1]Corresponding author

occupied its corresponding cervical portion of the vertebral column in camel. The segmental length in the cervical region rapidly increased from C_1 (6.0 cm) to C_5 (17.0 cm) followed by a sharp decrease in length till T_1 (5.0 cm). The segment length in the thoracic region showed a gradual increase from T_1 (5.0 cm) to T_5 (7.5 cm), followed by an approximately constant length upto T_{12} with an average of 8.0 cm. The cranial displacement of the thoracic spinal segments from 2nd to 8th in camel were similar to the results as reported in Indian buffalo (Sharma and Rao, 1971).

The lumbar region showed a remarkable decrease in the segment length from L_1 (7.0 cm) to L_7 (2.0 cm) followed by a gradual decrease from the L_7 to the termination of the spinal cord at coccygeal vertebra (Co_5, 0.5 cm) . The first five lumbar spinal cord segments showed a caudal displacement. In camel the cranial displacement began at the 7th lumbar spinal segment was also reported in Egyptian buffalo at 6th segment (Abu-Zaid, 1982), 4th in cattle (Dellmann and McLure, 1975) and 2nd lumbar segment in Indian buffalo (Sharma and Rao, 1971).

The average transverse diameter of the spinal cord at its beginning was 1.32 cm, it gradually increased caudally and was highest at the level of C_8 (1.70 cm) and T_1 (1.60 cm) where it formed the cervical enlargement (intumescentia cervicalis) and then again there was a gradual decrease in the diameter and smallest of which was recorded at the level of T_9 (0.98 cm). From the level of T_{10} the diameter again started increasing gradually and became large at L_7 (1.40 cm) and S_1 (1.38 cm) which formed the lumbosacral enlargement (intumescentia lumbalis). These two enlargements represented the origin of the brachial and lumbosacral plexuses, respectively.

The number of nerve rootlets was directly proportional to the transverse diameter of the spinal cord. The average number of nerve rootlets was 25 at the level of C_1, 70 at the C_8, and 68 (cervical enlargement) at T_1 and it was again recorded 25 at T_2 and 26 at T_3 level and then again started increasing gradually caudally to 54 at L_7 and 52 at S_1 (lumbar enlargement). The conus medullaris segment of the spinal cord showed the least number of the rootlets and the minimum number was at Co_5 level.

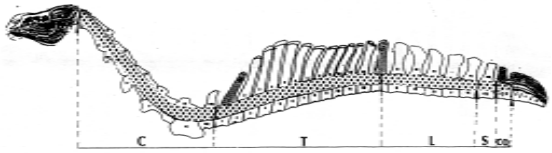

Fig 1. Composite diagram showing relationship between spinal cord segments, and bodies and spinous processes of vertebrae. C: cervical, T: thoracic, L: lumbar, S: sacral, Co: coccygeal region. (Lines on the ventral side represent the levels of the bodies of the vertebrae).

Relation between spinal cord segments and body of vertebrae

The first segment of the cervical spinal cord laid entirely in the atlas, while the second segment covered the cranial 2/3rd of the axis. The third to seventh cervical segments showed a cranial displacement by a distance ranging between 5.3 – 9.0 cm. The last cervical segment occupied the cranial 2/3rd part of the last cervical vertebra (Fig 1).The maximum cranial displacement was observed at the third, while the minimum at the seventh cervical vertebra segment.

The first segment of the thoracic spinal cord occupied the caudal 1/3rd of the last cervical vertebra and cranial half of the first thoracic vertebra. The second, third and fourth thoracic segments were completely displaced cranially from their corresponding thoracic vertebra to occupy the body of the preceding one. The 5th to 9th thoracic segments were located at the level of their corresponding vertebra and 9th thoracic segment terminated at the level of caudal border of the body of the corresponding vertebra. Last three thoracic segments showed a caudal displacement ranging between 2.5 – 3.0 cm.

The first five lumbar spinal segments showed a caudal displacement ranging between 2.0 – 3.0 cm. The last two lumbar segments were lodged with in the 6th lumbar vertebra. So the 6th lumbar vertebra occupied the caudal part of 5th, 6th and 7th segments. The sacral spinal segments

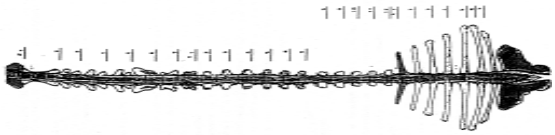

Fig 2. Composite diagram of dorsal view of vertebral column showing relationship between spinal cord segments and transverse processes of the vertebrae. (Lines on right side represent levels of transverse processes).

were comparatively smaller and all the five segments were lodged with in the last lumbar vertebra. Similar finding has been reported earlier (Hifny *et al.*, 1985).The coccygeal spinal segments were also comparatively smaller and tapered forming the conus medullaris. All the five segments were lodged in to the first, second and cranial half of the 3rd sacral vertebra where the spinal cord term inated.

Relation between spinal cord segments and spinous processes

The relationship was calculated by drawing a vertical line between the caudal margin of the summits of spinous processes and corresponding spinal cord segment. The dorsal tubercle of atlas vertebra was related vertically to cranial 1/4th of the second cervical segment, while the spinous process of second cervical vertebra (axis) laid opposite to the cranial 1/3rd of the third cervical segment. The spinous process of last cervical vertebra was related vertically to caudal margin of the 8th cervical segment (Fig 1).

The spinous process of first thoracic vertebra laid at the level of caudal 1/3rd part of third thoracic segment, while those of 2nd, 3rd and 4th thoracic vertebrae were related to caudal 1/5th of the 4th, 5th and 6th thoracic segments, respectively. The spinous processes of 9th and 10th thoracic vertebrae were located at the level of 10th and 11th thoracic segments, respectively, while those of the last two thoracic vertebrae were related to their corresponding segments. Almost similar findings had been reported in this species (Hifny *et al.*, 1985).

The caudal margin of spinous process of first lumbar vertebra was related vertically to the caudal 1/4th of first lumbar segment. The spinous process of 5th and 6th lumbar vertebrae was placed opposite to their corresponding segments, while that of last lumbar vertebra was present opposite to the end of the sacral segment. Hifny *et al.* (1985) stated that the spinous process of first lumbar vertebra laid vertical to the caudal most 1/3rd of the last thoracic segment, while that of the last lumbar vertebra opposite to the middle of the 4th lumbar segment.

Relation between spinal cord segments and transverse processes

The relationship was calculated on the basis of drawing a transverse line from the caudo-lateral angle of the transverse processes to the spinal cord segment (Fig 2). The wing of atlas vertebra laid at the level of cranial 1/4th of second cervical segment, while the transverse processes of second and third cervical vertebrae laid at the cranial 1/3rd of the third and fourth cervical segments. The transverse processes of 4th, 5th and 6th cervical vertebrae were present at the level of middle of the 5th, 6th and 7th cervical segments, respectively. However, the transverse process of last cervical vertebra laid opposite to the caudal margin of 8th cervical segment. The transverse processes of first six thoracic vertebrae lay opposite to their next corresponding spinal cord segments, while the last six transverse processes were placed opposite to their corresponding segments. The transverse processes of lumbar vertebrae were generally related to their corresponding lumbar spinal cord segments. The cranial border of the wing of sacrum laid opposite to the caudal end of 3rd sacral spinal segment.

REFERENCES

Abu-Zaid, S.M.S. (1982). Some gross anatomical studies on the prenatal and postnatal morphological features on the spinal cord of the water buffalo (*Bos bubalis*). Ph.D. thesis, Faculty of Vet. Med. Cairo Univ., Egypt.

Clair, L.E. and Hardenbrook, H.J. (1956). Lumbar epidural anaesthesia in cattle. *J. Am. Vet. Med. Assoc.* **129**: 405 – 409.

Dellmann, H.D. and McLure, R.C. (1975). Central nervous system In: "Sisson and Grossman's, The Anatomy of the Domestic Animals". Vol. I & II revised by Getty R. (5th edn.). W.B. Saunders Co., Philadelphia, London.

Goller, H. (1957). Topographie und segmentaler Feinbau des Ruckenmarkes des (*Ovis aries*).

Habel, R.E. (1951). Topography of the equine and bovine spinal cord. *J. Am. Vet. Med. Assoc.* **118**:122 - 124.

Hifny, A, Ahmed, A.K, Mansour, A.A. and Abdel – Moneim, M.E. (1985). Some anatomical studies on the spinal cord in camel. *Assiut Vet. Med. J.* **15**: 11-20.

McLeod, W.M. (1958). Neuroanatomy. In: "Bovine Anatomy" (2nd edn.), Burgess Publishing Co., Minneopolis, Minnesota.

Sharma, D.N. and Rao, G.S. (1971). Anatomy of spinal cord segments of buffalo (*Bubalus bubalis*). *Acta Anatomica* **79**: 51 – 59.

Sharma, D.N., Singh, Y. and Dhingra, L.D. (1973). Anatomical studies on the spinal cord segments of goat (*Capra hircus). Haryana Agri. Univ. J. Res.* **111**: 87 – 92.

Smuts, M.M.S. and Bezuidenhout, A.J. (1987). The Nervous system In: "Anatomy of the Dromedary". Clarendon Press, Oxford, UK. pp. 182 – 183.