Haryana Vet. (June, 2016) **55 (1)**, 108-109

Clinical Article

SURGICAL CORRECTION OF CONGENITALLY FUSED VULVA LABIA IN A HOLSTEIN FRIESIAN CROSS BRED HEIFER

RAMESH TIWARY[1]*, ANIL GATTANI[2], AJEET KUMAR[2], ANIL KUMAR[3] and G.D. SINGH[1]
[1]Department of Veterinary Surgery and Radiology, [2]Department of Veterinary Biochemistry, [3]Department of Veterinary Medicine, Bihar Veterinary College, Patna - 800 014, India

Received: 29.10.2015; Accepted: 04.02.2016

SUMMARY

A case of congenitally developed fused labia in a 16-month-old Holstein Friesian crossbred heifer is described. Grossly there was only one small opening in the dorsal vulvar commissure. The abnormality of the vulva was surgically corrected. The heifer was artificially inseminated post surgically in subsequent heat. The animal conceived and calved normally.

Key words: Congenital fused labia, crossbred heifer

Congenital defects present at birth occur frequently in cattle (Leipold and Dennis, 1986) and these defects may enhance perinatal mortality, decrease maternal productivity and reduce the value of defective neonates (Rousseaux, 1994). The factors responsible for causing the abnormalities are genetic, environmental or a combination of these factors (Roberts, 1971; Rousseaux, 1994). Congenitally fused labia syndrome is defined as a variable occlusion of the labia majora by connective tissue (Wedi *et al.,* 2011). This syndrome was described in heifers by Oettle and Coubrough (1985) and Balasubramanian *et al.* (1991). However, no information regarding the subsequent fertility was recorded. In the present study, we describe the surgical treatment of congenitally fused labia and subsequent conception in a crossbred Holstein-Friesian heifer.

A 16 month old crossbred heifer was brought to the Teaching Veterinary Clinical Complex, Bihar Veterinary College, Patna, with a history of congenitally fused labia. The heifer showed normal signs of estrous. On examination, one small opening of 8 mm in diameter at dorsal commissure was observed and animal was urinating normally through this orifice. The opening was sufficient to pass an artificial gun. The animal's genitalia were thoroughly examined per rectally and were found to be normal showing presence of regressing corpus luteum on right ovary. Haemostat was inserted through the opening at dorsal commissure and directed downward. A pouch due to congenital complete closure of vulvar lips at ventral surface was observed (Fig. 1).

Blood sample was collected from the jugular vein for biochemical and hormonal analysis. Serum total proteins, albumin, blood urea nitrogen (BUN) and creatinine concentration were estimated using Coral clinical systems reagent kits (India) and serum progesterone, 17α-estradiol and testosterone concentrations were determined by enzyme immunoassay (elisaVUE, Gene Front, Hyderabad, India) according to the manufacturer's instructions.

Animal was restrained in trevis under standing sedation with xylazine @ 0.05 mg (Xylaxin 2%, Indian Immunologicals, Hyderabad) intravenously and caudal epidural analgesia achieved with 6 ml lignocaine hydrochloride injection (Xylocaine 2% Astra Zeneca, Bangalore) injected aseptically between sacro-coccygeal joint. The surgical site was prepared aseptically and painted with povidone iodine. Haemostat inserted in opening at dorsal commissure was directed downward and opened to stretch the vulva to avoid any irregular incision on the vulvar mucosa and downward longitudinal incision was given to separate the vulvar attachments (Fig. 2). The mucosal surface of each vulvar lip was sutured with subcutaneous vulvar skin using catgut 1/0 by continuous suture pattern (Fig. 3). Post operatively, the animal was administered ceftiofur @ 1mg/ kg b wt. intramuscularly (Inj. Xyrofur, Neovet, Intas Pharmaceuticals Ltd., Ahmedabad) daily for three days, 4 ml meloxicam (Inj. Melonex power, Neovet, Intas Pharmaceuticals Ltd., Ahmedabad) intramuscularly once daily for 3 days and advised topical spray (D'Mag, Neovet, Intas Pharmaceuticals Ltd., Ahmedabad) three times daily. Uneventful recovery was observed after 7th day. Fifteen days post surgery, the heifer showed spontaneous standing heat and inseminated successfully. Animal did not show heat in next three months after insemination and found positive for pregnancy per-rectally. After full term pregnancy, a healthy calf was born.

*Corresponding author: vettiwary@gmail.com

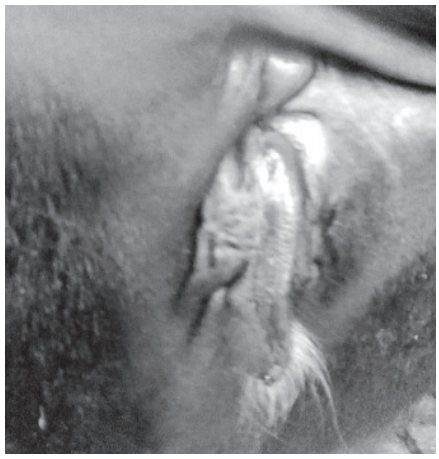

Fig 1. Fused vulva labia in a crossbreed Holstein Friesian heifer with small opening in the dorsal vulvar commissures

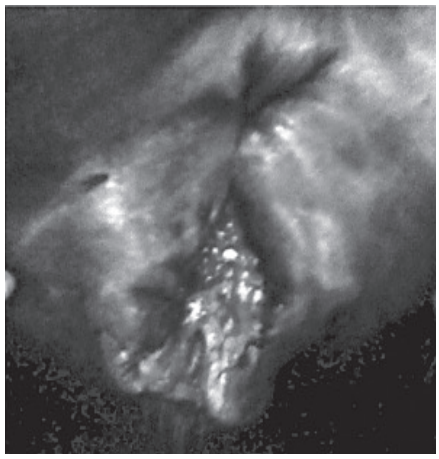

Fig 2. Labia got separated after incision

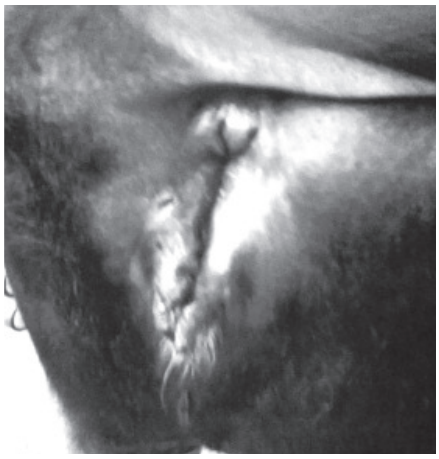

Fig 3. Appearance of vulva after application of sutures

Genetic or environmental factors or a combination of both are frequently pointed to as the causative factors of congenital defects. However, the causes of congenitally fused labia are still unknown. External as well as internal congenital anomalies of the female reproductive tract may be the result of enzymatic defects or prenatal drug exposure (Craighill, 1993) and consumption of certain types of synthetic steroids in early pregnancy (Seller and Bobrow, 1987). In the present case, normal oestrous behaviour and per rectal examination of genital tract suggested that there was not any reproductive disorder in the heifer due to congenitally fused labia.

The values of different parameters were: serum total proteins (6.2 g/dl), albumin (3.4 g/dl), BUN (19.26 mg/dl), creatinine (1.21 mg/dl), serum progesterone (0.42 ng/ml), 17α-estradiol (13.18 pg/ml), and testosterone (2.8 ng/dl). The serum biochemical and hormonal concentrations showed that animal's metabolic and hormonal status was relatively normal. Postoperative complications such as pneumovagina and urovagina or both were not seen. There was no purulent/mucopurulent/ foamy vaginal discharge post-operatively except for physiological edema. Isachenko *et al.* (2002) in common marmosets emphasized that this defect is inherited recessively and affects the conception. The normal conception in the heifer in this study highlights the importance of surgical intervention. Recently, the birth of a healthy calf from congenitally fused labia in Brown-Swiss heifer has also been reported (Yilmaz *et al*., 2014). The present case provides evidence that congenitally fused labia anomaly may be easily treated surgically.

REFERENCES

Balasubramanian, S., Seshagiri, V.N., Kathiresan, D., Asokan, A. and Pattabiraman, S.R. (1991). Congenitally fused labiae vulva in a heifer. *Vet. Rec*. **129**: 55-56.

Craighill, M.C. (1993). Congenital anomalies of the female reproductive tract. *Curr. Opin. Obstet. Gynecol*. **5**: 758-763.

Isachenko, E.F., Nayudu, P.L., Isachenko, V.V., Nawroth, F. and Michelmann, H.W. (2002). Congenitally caused fused labia in the common marmoset (*Callithrix jacchus*). *J. Med. Primatol*. **31**: 350-355.

Leipold, H.W. and Dennis, M. (1986). Congenital Defects Affecting Bovine Reproduction. In: Current Therapy in Theriogenology. Morrow D.A. (edt.). WB Saunders, Philadelphia, PA, USA

Oettle, E.E. and Coubrough, R.I. (1985). A pregnant heifer with a congenital incompletely developed vulva. *J. South African Vet. Assoc*. **56**: 137-138.

Roberts, S.J. (1971). Veterinary Obstetrics and Genital Diseases. CBS Publishers and Distributors, New Delhi, India

Rousseaux, C.G. (1994). Congenital defects as a cause of perinatal mortality of beef calves. *Vet. Clin. North American Food Anim. Pract*. **10**: 35-51.

Seller, M.J. and Bobrow, M. (1987). Congenital Abnormalities and the Pathologist. In: Fetal and Neonatal Pathology. Keeling (edt.). Springer-Verlag, Berlin, Germany.

Wedi, E., Nayudu, P.L. and Michelmann, H.W. (2011). A case report of spontaneous opening of congenitally fused labia in a female common marmoset (*Callithrix jacchus*) followed by pregnancy and birth of twins. *J. Med. Primatol*. **40(5)**: 351-3.

Yilmaz, O., Yazici, E., Ucar, M. and Birdane, M.K. (2014). The treatment of congenitally developed fused vulva labia in a Brown-Swiss heifer. *Turkish J. Vet. Anim. Sci.* **38**: 116-119.