Research Article

Haryana Vet. (Dec., 2018) **57 (2)**, 175-177

HISTOMORPHOLOGICAL AND MICROMETRICAL STUDIES ON RETE OVARII IN BUFFALOES

NAWESHA KUMARI, NEELAM BANSAL*, VARINDER UPPAL and ANURADHA GUPTA
Department of Veterinary Anatomy, College of Veterinary Science, GADVASU, Ludhiana

Received: 20.03.2018; Accepted: 25.11.2018

ABSTRACT

The present study was conducted on ovaries of eighteen buffaloes divided into three groups; prenatal, prepubertal and adult with six animals in each group. The tissue samples were collected in 10% Neutral buffered formalin (NBF), processed and stained to observe the detailed histomorphological and micrometrical observations. The results showed that rete system in buffalo was divisible into intraovarian rete, connecting rete and extraovarian rete in the medulla during prenatal life. The extraovarian rete and connecting rete were located in the hilus of the ovary whereas the intraovarian rete were present at the cortico-medullary junction. The lining epithelium of all types of tubules varied from simple to pseudostratified columnar type. The shape of these tubules varied from rounded to oval in shape. The intraovarian rete was divided into rete cords and tubules. The rete cells from rete cords migrated to form the granulosa cells of ovarian follicles. The intraovarian rete tubules, connecting and extraovarian rete tubules were well developed during prenatal and prepubertal life, but diminished with the age of animal. Micrometrical observations showed that the diameter of intraovarian rete and extraovarian rete decreased but that of connecting rete increased with the age of animals. It may be concluded from the present findings that the number of rete ovarii decreased from prenatal to puberty and contained more amount of connective tissue separating the rete tubules in pubertal animals.

Key words: Buffalo, Histomorphology, Micrometry, Rete ovarii

Rete ovarii were also referred as a vestigial network of cells and tubules within the ovary (Goswami, 1985). According to Dellman and Eurell (2006), the ovarian medulla consisted of loose connective tissue strands of smooth muscles, blood and lymph vessels, nerves and network of irregular channels called rete ovarii, rete system which was divided into three parts; extraovarian rete, connecting rete and intraovarian rete. As different terminology had been used for various components of rete ovarii, Byskov (1978) named it as rete system which was divided into three parts as extraovarian rete (ER), connecting rete (CR) and intraovarian rete (IR). Gill (2000) designated the part of rete system located within the periovarian tissue as extraovarian rete, part within the medulla as intraovarian rete, and connecting tubules between extraovarian and intraovarian as connecting rete.

MATERIALS AND METHODS

The present study was conducted on ovaries of eighteen buffaloes collected from slaughter house and Teaching Veterinary Clinical Complex and post-mortem hall, GADVASU, Ludhiana. These animals were divided into three groups viz; Group I (Prenatal), Group II (Prepubertal) and Group III (Pubertal) animals with six animals in each group. Age of prenatal animals was calculated by measuring the foetal body length in centimetres with a calibrated inelastic thread along the vertebral column between the most anterior part of frontal bone to the rump at ischiatic tuberosity and designated as curved crown rump length (CVRL) (Edward 1965). The approximate age of the foetuses was calculated by using the formula given by Soliman (1975).

$$Y = 28.66 + 4.496\,X \text{ (CVRL} < 20 \text{ cm)}$$

$$Y = 73.544 + 2.256\,X \text{ (CVRL} \geq 20 \text{ cm)}$$

Where Y is the age in days and X is the CVRL in cm.

The age of prepubertal and pubertal animals was calculated from the dentition (Saini *et al.,* 1993). After determining the age, the left and right ovaries were collected and fixed in 10 % neutral buffered formalin (10 % NBF). After processing, the paraffin sections of 5-6 µm were obtained and were stained with Hematoxylin and eosin for routine histomorphology, Masson's Trichrome for collagen fibres, Gridley's for reticular fibres, Verhoeff's for elastic fibres and Holmes's for neuronal elements (Luna, 1968). Micrometrical parameters were recorded on Hematoxylin and eosin stained sections by means of standard method of micrometry using Nikon 80 i camera mounted microscope with the help of image J software

RESULTS AND DISCUSSION

Histomorphology:

The results showed that rete system in buffalo was divisible into intraovarian rete, connecting rete and extraovarian rete during prenatal life. The extraovarian rete and connecting rete were located in the hilus of the ovary whereas the intraovarian rete were present at the cortico medullary junction. The lining epithelium of all types of tubules varied from simple to pseudostratified columnar type. The shape of these tubules varied from rounded to oval in shape. The intraovarian rete was divided into rete cords and tubules. The rete cells from rete cords migrated to form the granulosa cells of ovarian follicles. The intraovarian rete tubules, connecting and extraovarian rete tubules were well developed during prenatal and prepubertal life, but diminished with the age of animal as

*Corresponding author : bansal.neelam@rediffmail.com

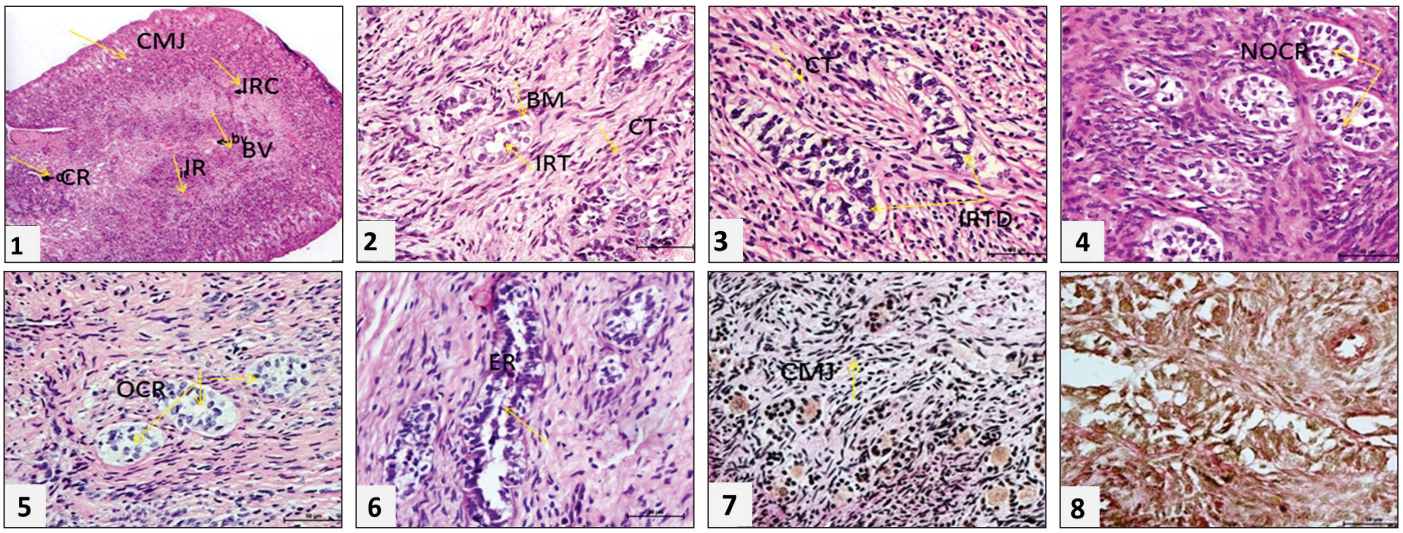

Fig 1: Longitudinal section of 34 cm CVRL buffalo foetus showing formation of intraovarian rete (IR) surrounded by medullary blood vessel (BV), connecting rete (CR) at the junction of medulla and pedicle. Intraovarian rete cords (IRC) were observed at the corticomedullary junction (CMJ). (H. & E. X 40). 2: 48 cm CVRL buffalo foetus showing intraovarian rete tubles (IRT) lined by simple columnar and pseudostratified columnar epithelium with a distinct basement membrane (BM). Abundance of connective tissue (CT) separating the intraovarian rete tubules. (H. & E. X 400). 3: Degenerated intraovarian rete tubules (IRTD) with increase in connective tissue (CT) in the intertubular area during pubertal life. (H. & E. X 400). 4: Normal ovarian proper connecting rete (NOCR) lined by pseudostratified columnar type of epithelium with less luminal contents during prepubertal period. (H. & E. X 400). 5: Ovarian proper connecting rete (OCR) showing decrease in the tubular component and increase in the intertubular connective tissue during pubertal period. (H. & E. X 400). 6: Elongated and rounded extraovarian rete containing amorphous cellular debris in the lumen in prepubertal group. (H. & E. X 400). 7: Less amount of elastic fibres in the connective tissue stroma at corticomedullary junction (CMJ) and cortex. (Verhoeff's stain X 400). 8: Few reticular fibers in intertubular area of connecting rete during prepubertal life. (Gridley's stain X 400).

observed by Abd el- hafez (2011) in bovines.

At 25 cm CVRL of buffalo foetus, the medulla contained darkly stained part in the centre called rete system which was differentiated into intraovarian rete, connecting rete and extraovarian rete based on their location. At 34 cm CVRL, intraovarian rete was divided into intraovarian rete cords and intraovarian rete tubules. Large number of blood vessels was observed at cortico-medullary junction. The connecting rete was present at the junction of ovarian pedicle and medulla (Fig. 1). Similar observations have been reported by Gill (2000) in buffalo foetus ovary. At 48 cm CVRL, the medulla consisted of loose connective tissue strands of smooth muscles, numerous blood vessels, lymph vessels, nerves and darkly stained network of irregular channels called rete system which was divided into 3 parts: as intraovarian rete, connecting rete and extraovarian rete in prenatal life. Intraovarian rete was present within the medulla, whereas extraovarian was located in periovarian tissue and connecting rete connected with extraovarian and intraovarian rete. At this stage, intraovarian rete tubules were well differentiated and were lined by simple columnar and pseudostratified columnar epithelium with a distinct basement membrane. Abundance of connective tissue separating the intraovarian rete tubules were also observed as seen in Fig 2. During prepubertal group, the intraovarian rete cords could not be observed. The number and size of intraovarian rete tubules was decreased, but the connecting tissue elements in between these had been increased. Intraovarian rete was smaller in size and ocassionally had a lumen in pubertal animals (Fig 3). These tubules appeared as disorganized epithelial structures lined by simple columnar to pseudostraified columnar epithelium surrounded by a basement membrane. The connecting rete were well organised and lined by pseudostratified columnar type of epithelium with less luminal contents during prerepubertal period (Fig 4), while there was decrease in the tubular component and increase in the intertubular connective tissue during pubertal period (Fig 5). There was an increase in the

Table 1

Micrometrical observations (Mean ± S.E.) on tubular diameter (µm) and epithelial thickness (µm) in rete system in buffalo ovary

Rete System	Intra Ovarian Rete		Connecting Rete		Extraovarian Rete	
Age Group	Tubular diameter	Epithelial thickness	Tubular diameter	Epithelial thickness	Tubular diameter	Epithelial Thickness
Prenatal	6.77 ± 0.02	2.94 ± 7.08	7.92 ± 0.08	3.07 ± 7.70	8.99 ± 0.07	3.14 ± 0.06
Prepubertal	229.74 ± 0.88	9.38 ± 0.17	198.55 ± 0.27	7.13 ± 0.03	198.48 ± 0.98	11.48 ± 0.28
Pubertal	232.50 ± 3.60	26.24 ± 0.77	236.59 ± 1.47	44.87 ± 0.60	224.08 ± 5.32	26.27 ± 1.15

number and size of extraovarian rete in pubertal group (Fig 6).

The intertubular area of intraovarian rete, connecting rete and extraovarian rete also showed the presence of collagen fibres separating the individual tubules along with the few elastic and reticular fibres. The amount of reticular fibres was more in the intertubuler area of large blood vessels (Figs 7 and 8). Few neuronal elements were also demonstrared in the intertubuler area of intraovarian rete tubules and cortico-medullary junction. There was decrease in the fibrous component during prepubertal life. The number and amount of collagen fibres decreased in the intertubular area of the rete system. It was observed that the intertubular area of ovarian proper connecting rete contained more collagen fibres as compared to mesovarian connecting rete. The amount of reticular and elastic fibres was less as compared to collagen fibres in the intertubular area of ovarian proper connecting rete. However, the tunica intima of large blood vessel showed well differentiated elastic fibres present in the wavy pattern but the intertubular area of mesovarian connecting rete contained less amount of elastic fibres and neuronal elements. Similar findings have been reported by Bhardwaj (1996) and Goswami (1985) in buffalo ovary.

The histomorphological observations showed that the volume of rete ovarii decreased from birth to puberty and contained more amount of connective tissue separating the rete tubules in pubertal animals. Most of these tubules showed degenerative changes leading to diminished lumen. It may be due to the fact that the rete system became prominent during post pubertal life as polycystic, metaplastic resembling Brenner Islands and long tubular structures, so with the advancing age it became more atrophic and became solid adenomatous, cystic or polycystic in sheep ovary as noticed by Smith (2011) in sheep, Sauramo (1954) in human ovaries, Byskov (1975) in cat, mink and ferret, and Wenzel *et al*. (1987) in bovines.

Micrometry:

The micrometrical observations on the tubular diameter and epithelial thickness of intraovarian, connecting and extraovarian rete tubules of prenatal, prepubertal and pubertal buffalo ovaries are depicted in Table 1. It is interpreted from the present data that the diameter of all the tubules increased significantly from group I to group II and III. The diameter of intraovarian, connecting and extraovarian rete tubules varied from 6.77

It may be concluded from the present findings that number of rete ovarii decreased from birth to puberty and contained more amount of connective tissue separating the rete tubules in pubertal animals.

REFERENCES

Abdel-Hafeez, H.H. (2011). Morphological studies on the bovine ovary. Ph.D. thesis submitted to Assiut University, Assiut, Arab Republic of Egypt.

Bhardwaj R.L. (1996). Age related morphological, histochemical and biochemical studies on the ovary of Indian buffalo *(Bubalus bubalis*). Ph.D. thesis submitted to Punjab Agricultural University, Ludhiana, India.

Byskov A.G. (1975). The role of the rete ovarii in meiosis and follicle formation in the cat, mink and ferret. *J.Reprod. Fert.* **45**: 201-209.

Byskov A.G. (1978). The anatomy and ultrastructure of the rete system in the fetal mouse ovary. *Biol. Reprod.* **19**: 720-735.

Dellmann H.D. and Eurell J.A. (2006). Textbook of Veterinary Histology. 6th edn. Williams and Wilkins, Baltimore, Maryland.

Edward M.J. (1965). Observations on the anatomy of reproductive organs of cows with special reference to those features sought during examination per rectum. *New Zealand Vet. J.* **13**(**2**): 25-37.

Gill G.S. (2000). Morphogenesis and histogenesis of ovary of buffalo (*Bubalus bubalis)*. M.V.Sc thesis submitted to Punjab Agricultural University, Ludhiana, India.

Goswami R.K. (1985). Histomorphological and histochemical observations on ovary in Murrah buffaloes. M.V.Sc. thesis submitted to Haryana Agricultural University, Hisar, India

Luna, L.G. (1968). Manual of histological staining methods of armed forces Institute of Pathology. 3rd edn. McGraw Hill Book Company, New York, USA.

Saini A.L, Singh B and Gill R.S. (1993). Estimation of age from teeth in dairy animals. *Indian Dairy Man*. **45**:143-145.

Sauramo H. (1954). Development, occurrence, function and pathology of the rete ovarii. *Acta Obstetrics Gynaecology Scand Suppl* **33**: 29-46.

Smith, P. (2011). Development of the Rete ovarii in the sheep ovary. M.Sc. thesis submitted to University of Otago, Dunedin, New Zealand.

Soliman, M.K. (1975). Studies on the physiological chemistry of the allantoic and amniotic fluids of buffaloes at various periods of pregnancy. *Indian Vet. J.* **52**: 111-117.

Wenzel, J.G.W., Odend'hal, S. and Player, E.C. (1987). Histological and histochemical characterization of the bovine rete ovarii through the estrous cycle and gestation. *Anat. Histo. Embryo.* **16**: 124-135.