Haryana Vet. (Dec., 2018) **57 (2)**, 219-221

Short Communication

RETROSPECTIVE STUDIES ON TUMOUR INCIDENCE IN BOVINES OVER A PERIOD OF TEN YEARS (2005-2014)

SONU SHARMA, R.P. GUPTA and DEEPIKA LATHER*

Department of Veterinary Pathology, College of Veterinary Sciences,

Lala Lajpat Rai University of Veterinary and Animal Sciences, Hisar-125004, Haryana

Received: 03.02.2018; Accepted: 22.11.2018

SUMMARY

Retrospective study of 111 tumours recorded over a period of last 10 years i.e. from 2005 to 2014 available in the department revealed different types of epithelial and mesenchymal origin tumour. In cattle and buffaloes, fibroma among mesenchymal andsquamous cell carcinomaamong epithelial tumours were most common . Regarding species-wise incidence, it was more in buffaloes as compared to cattle and mostly encountered in females of both the species. Regarding location of the tumours, maximum cases were of oral tumours followed by ocular, head/face region, udder and teat, cutaneous and visceral origin. Squamous cell carcinoma (SCC) of eye and horn cancer was more prominent in epithelial tumours and fibroma of oral cavity was prominent in mesenchymal tumours. These data indicate increase in number of tumour cases over the years. These data may also be used to compare the prevalence of bovine tumours occurring in this area (Haryana state) with that of other states.

Key words: Buffalo, Cattle, Incidence, Neoplasm

Malignant neoplasm is one of fatal disorders affecting human beings, which is considered as the second most common disease in India responsible for about 0.3 million deaths per year (Ali *et al.,* 2011). In veterinary oncology, the literature on canine mammary tumours is voluminous and the tumour has been reported to cause heavy mortality in female dogs (Bronden *et al*., 2010). However, systematic study at regional or national level to find out the specific pattern of tumour occurrence in bovines is sparse, particularly in India. Marosfoi *et al.*(2009) reported that the frequency of occurrence of tumours in bovines has been found to be in ascending tendency.

The studies on bovine tumours are of clinical concern as they may cause economic losses due to negative impact on productivity, animal health, and thus may reduce profits to individual farmers and dairy industry. The retrospective epidemiological studies on neoplastic disorders can be used as an important source of information for analyzing neoplastic disease behaviour over time and for suggesting approaches for their control. Therefore, the retrospective study was undertaken to know incidence and pattern of various tumours in bovines over the period between the years 2005-2014.

The study was conducted on the record of 111 biopsy reports of last ten years i.e. from 2005 to 2014 available in the department of Veterinary Pathology for evaluating occurrence of tumours in cattle and buffaloes. Details regarding species, sex and anatomical location were recorded from the clinical history of the cases. The method of histopathology was as per the procedure of Luna (1968). Tissues sections, wherever required were stained with special staining procedures such as Masson's trichrome stain to differentiate fibroma with leiomyoma and Toulidine blue staining to rule out mastocytoma (Luna ,1968).

Results of retrospective study of 111 tumours recorded over a period of last 10 years revealed different types of tumours as described under:

Tumour type: Various types of tumours diagnosed on the basis of histopathological examination in bovines from the year 2005 to 2014 are illustrated in Fig. 1. The various tumours diagnosed of epithelial origininclude squamous cell carcinoma (19 cases), papilloma (9 cases) (Fig. 2), adenoma (8 cases), ameloblastoma (2 cases) and one case each of basal cell carcinoma and mammary gland adenocarcinoma (Fig. 3). Among mesenchymal tumours fibroma (22 cases), myxoma (11 cases) (Fig. 4), leiomyoma (8 cases), epulis (4 cases), lipoma (3 cases), haemangiopericytoma (3 cases), leiomyosarcoma (2 cases), rhabdomyoma (2 cases) and one case each of osteosarcoma, mesothelioma (Fig. 5), chondroma, chondrosarcoma, haemangioma (Fig. 6) were observed. The tumour conditions of uncertain origin affecting bovines include histiocytoma (3 cases), mastocytoma (2 cases) and sertoli cell tumour (2 cases).

Results of retrospective study of 111 tumours recorded over a period of last 10 years revealed that different types of epithelial and mesenchymal origin tumours were identified in cattle and buffaloes. In mesenchymal tumours, fibroma was more prominent and in epithelial tumours it was squamous cell carcinoma. Regarding species wise incidence, it was more in buffaloes as compared to cattle and mostly encountered in females of both the species. Regarding location of the tumours, only biopsies received were from skin, oral cavity, eyes or locations which can be observed easily by the owner. So,

*Corresponding author: deepikalather@yahoo.co.in

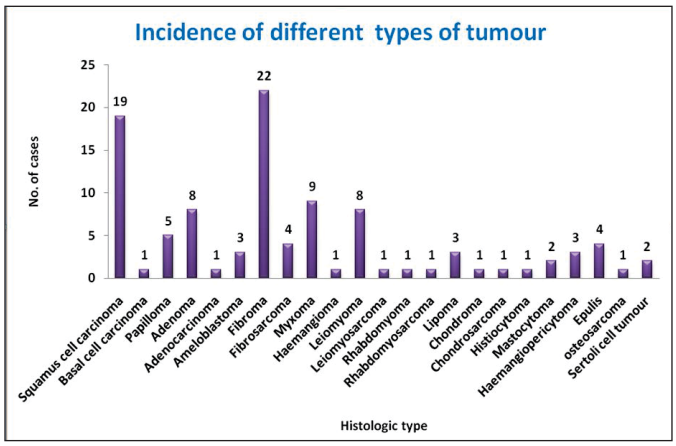

Fig. 1: Incidence of different types of tumours in bovine from year 2005-2014

incidence of tumour involving internal organs could not be assessed except two cases each of postmortem and caesarian operation. Maximum cases were of oral tumours followed by in decreasing order were ocular, head/face region, udder and teat, cutaneous and visceral origin. SCC in eye and horn cancer was more prominent in epithelial tumours and fibroma of oral cavity was prominent in mesenchymal tumours. These data are useful to find out whether the incidence of tumours is on increasing trend. It is apparent from the study that there was tremendous increase in number of cases in the year 2014 otherwise, it was almost static. Prompt and regular attempts are required for the collection and dispatch of the samples to laboratories for diagnosis hence can increase the number of cases and can provide true picture about incidence of tumour cases.

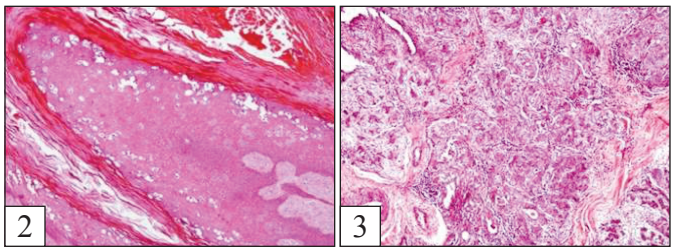

Fig.2: Papilloma tumour characterized papillary projections consisted of different layers of stratified epithelium having keratinized layer on periphery and connective tissue in centre; 3: Mammary adenocarcinoma in a Heifer characterized by irregular shaped glandular alveoli lined by pleomorphic luminal epithelial cells forming multiple layers and filling the alveolar spaces.

Similar to our findings other retrospective studies suggest that the most common forms of neoplasia affecting cattle are ocular and periorbital SCC (Priester and Mantel,1971; Naghshineh *et al.,* 1991), lymphoma (Shortridge and Cordes, 1971), neurofibromatosis (Misdorp, 1967) and skin tumours (Bastianello, 1982). Kohli *et al*. 2007 also showed that squamous cell carcinomas were the most common tumour (62%) followed by papillomas (26%) in bovine. Lucena *et al.* (2011) reported retrospective study of 586 tumours in Brazilian cattle and found high incidence of squamous cell carcinoma of upper alimentary tract due to chronic ingestion of bracken fern. In the present study, incidence of squamous cell carcinoma was also high in eyes which might be associated with solar radiation as reported by many workers (Goldschmidt and Hendrick, 2002; Anderson and Badzioch, 1991). The aetiology of this lesion is probably multifactorial, with genetic, environmental and possibly viral factors (Heeney and Valli, 1985).

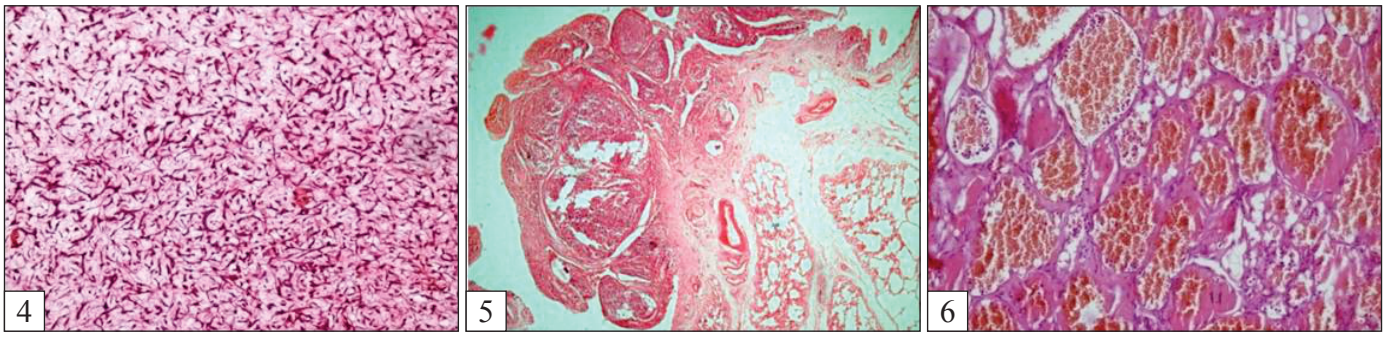

Fig. 4: Myxoma tumour exhibiting large pleomorphic stellate, triangular and rounded fibroblast cells having prominent cytoplasmic processes, forming a meshwork; 5: Mesothelioma in an adult buffalo characterized by nodular growths on pleural surface with acidophilic granular cytoplasm and a large prominent vesicular nucleus; 6: Haemangioma tumour characterized by irregular shaped blood vascular spaces filled with blood and lined by single layer of endothelial linings.

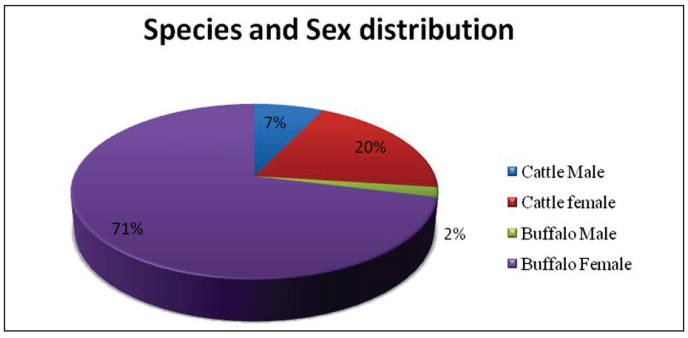

Fig. 7: Species and sex wise distribution of tumours in bovine from year 2005-2014

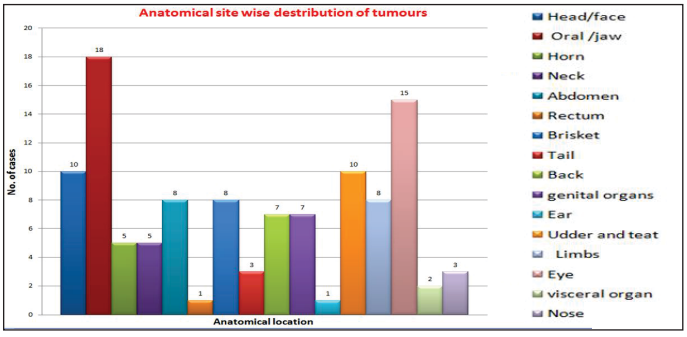

Fig. 8: Anatomical site wise distribution of bovine tumours from year 2005-2014

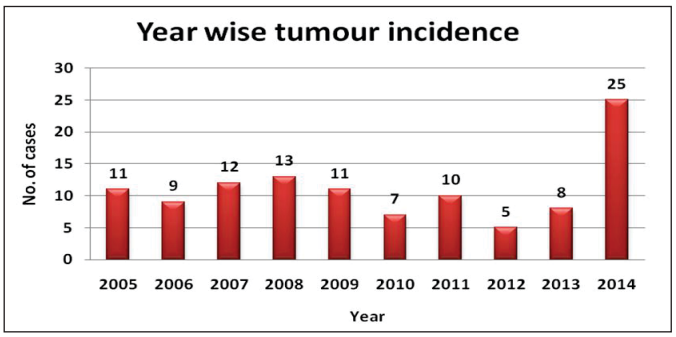

Fig.9: Year wise incidence of bovine tumours from year 2005-2014

Various researchers suggested that a cause of greater frequency of ocular squamous cell carcinoma is the U.V. radiation which is believed to be the primary carcinogen (Chahory *et al.,* 2002). However, other factors like the over expression of the tumour suppressor gene p53 which is targeted by U.V radiation has been reported in squamous cell carcinoma (Leapis *et al.,* 2004). In addition to sunlight, environmental carcinogens present in tobacco, coal tar and soot and industrial pollutants as heavy metals such as lead, arsenic, mercury, chromium have been shown experimentally or by epidemiologic inference to cause squamous cell carcinoma of skin and other tissues (Ginn *et al.,* 2007; Gharagozlou *et al.,* 2007). Genetic factors and papilloma viruses also influence the occurrence of papilloma, squamous cell carcinoma and sarcoid tumours. Differences in the incidence of a particular type of tumour among different regions may suggest that different environmental factors are associated with the development of the neoplasm. These data may also serve to compare the prevalence of tumours in bovine occurring in this area (Haryana state) with incidence of tumours in other states. Therefore, such studies are of clinical significance to plan further research programmes.

REFERENCES

Ali, I., Wani W. A. and Saleem, K. (2011). Cancer scenario in India with future perspectives. *Cancer Therapy.* **8**: 56-70.

Anderson, D.E. and Badzioch, M. (1991). Association between solar radiation and ocular squamous cell carcinoma in cattle. *American J. Vet. Res.* **52**: 784-788.

Bastianello, S.S. (1982). A survey on neoplasia in domestic species over a 40-year period from 1935 to 1974 in the Republic of South Africa. 1. Tumours occurring in cattle. *Onderstepoort J. Vet. Res.* **49**: 195-204.

Bronden, L.B., Nielsen, S.S., Toft, N. and Kristensen, A.T. (2010). Data from the Danish veterinary cancer registry on the occurrence and distribution of neoplasms in dogs in Denmark. *Vet. Rec.* **166**: 586-590.

Chahory, S., Clerc, B., Devauchelle. P. and Tnibar. A. (2002). Treatment of a recurrent ocular squamous cell carcinoma in a horse with Iridium 192 Implantation. *J. Equine Vet. Sci.* **22:** 503-506.

Gharagozlou, M.J., Hekmati, P. and Ashrafihelan, J. (2007). A clinical and histopathological study of ocular neoplasms in dairy cattle. *Vet. Arch.* **77:** 409-426.

Ginn, P.E., Mansell, J.E.K.L. and Rakich, P.M. (2007). Skin and appendages. In: Pathology of the Domestic Animals. 5th edn., Jubb, K.V.F., P.C., Kennedy, N.C. Palmer, (edts.), Vol. 1,W.B. Saunders Co., Philadelphia. pp. 751-753.

Goldschmidt, M.H. and Hendrick. M. J. (2002). Tumours of the Skin and Soft Tissues In: Tumours in Domestic Animals, 4thedn. Meuten, D.J. (edt.), Iowa State University Press, Ames, IA. pp. 518-521.

Heney, J.L. and Valli, V.E.O. (1985). Bovine ocular squamous cell carcinoma: an epidemiological perspective. *Canadian J. Comp. Med.* **49**: 21-27.

Kohli, R.N., Mohammadian, B. and Saiyari, M. (2007). A retrospective study on the incidence of bovine external neoplasms in south-western Iran. *Indian J. Anim. Sci*. **77:** 991-993.

Leapis, L. K. and Genovese, L. (2004). Haemangiosarcoma of the third eyelid in a dog. *Vet. Opthal.* **7:** 279-282

Lucena, R.B., Rissi, D.R., Kommers, G.D., Pierezan, F., Oliveira-Filho, J.C., Macedo, J.T.S.A., Flores, M. M. and Barros, C. S. L. (2011). A retrospective study of 586 tumours in Brazilian cattle. *J. Comp. Path.* **145**: 20-24.

Luna, L.G. (1968). Manual of histologic staining methods of Armed Forces Institute of Pathology, 3rd edn. Mc Graw Hill Book Co. New York.

Marosfoi, L., Baba, A.I. and Catoi, C. (2009). Morphological study of bovine tumours. *Bulletin UASVM Vet. Med.* **66:** 147-151**.**

Misdorp, W. (1967). Tumours in large domestic animals in the Netherlands. *J. Comp. Path.* **77:** 211-216.

Naghshineh, R., Hagdoost, S.I. and Mokhber-Dezfuli, M.R. (1991). A retrospective study of the incidence of bovine neoplasm in Iran. *J. Comp. Path.***105**: 232-239.

Priester, W.A. and Mantel, N. (1971). Occurrence of tumours in domestic animals. Data from 12 United States and Canadian colleges of Veterinary Medicine. *J. National Cancer Institute.* **47:**1333-1344.

Shortridge, E.H. and Cordes, D.O. (1971). Neoplasms in cattle: a survey of 372 neoplasms examined at the Ruakura Veterinary Diagnostic Station. *New Zealand Vet. J.* **19**: 5-11.