Research Article

Haryana Vet. (Dec., 2018) **57 (2)**, 143-146

ULTRASONOGRAPHIC, RADIOLOGICAL AND SURGICAL FINDINGS OF TRAUMATIC RETICULOPERITONITIS IN BUFFALOES

MADAN PAL[1*], RISHI TAYAL[2], R.N. CHAUDHARY[2] and DINESH[2]

[1*]Veterinary Surgeon, Animal Husbandry and Dairying Department, Haryana, [2]Department of Veterinary Surgery and Radiology, Lala Lajpat Rai University of Veterinary and Animal Sciences, Hisar-125004, India

Received: 05.10.2017; Accepted: 23.08.2018

ABSTRACT

The present study was conducted to compare the ultrasonographic, radiologic and surgical findings of traumatic reticuloperitonitis in buffaloes. Out of 35 clinical cases, 8 could be compared with radiologic findings and confirmed by laparorumenotomy. Ultrasonographically, echogenic bands of fibrin were seen freely floating in anechoic fluid between abdominal wall and the reticular wall (n=4). In majority of cases, corrugated appearance of the reticular wall with anechoic fluid, hyperechoic fibrin deposits between abdominal wall and reticulum was suggestive of the reticuloperitonitis and adhesions. Reduction or absence of reticular contractility was considered to be characteristic ultrasonographic findings in cases of reticuloperitonitis and adhesions. On the basis of radiological findings, only 1 case was diagnosed for reticulophrenic adhesions (radiolucent density/spots on mid ventral area on the diaphragmatic line). Exploratory laparorumenotomy was performed in 8 cases and all these were found positive for traumatic reticuloperitonitis and adhesions. The results of present study described the significance of ultrasonography as more accurate than radiography in diagnosis of reticuloperitonitis/adhesions in buffaloes.

Key words: Buffalo, Radiography, Reticuloperitonitis, Ultrasonography

Traumatic reticuloperitonitis is one of the most common problem of gastrointestinal tract in buffaloes which is caused by ingestion and subsequent penetration of the reticulum by sharp foreign bodies. Sometimes, the foreign bodies penetrate neighbouring tissues of the reticulum like spleen and liver (Radostits *et al*., 2007; Orpin and Harwood, 2008). Abdominal pain, extended neck, arched back, grunting, sometimes muffled heart sound, abnormal lung sound, variable heart rate, respiratory rate and rectal temperature are important clinical signs of traumatic reticuloperitonitis (Jeffrey and Ducharme, 1994). However, it is also not uncommon for foreign bodies to penetrate and cause infection and then be removed by reticular movements. The foreign body may penetrate beyond the peritoneal cavity leading to different complications like traumatic pericarditis, vagus indigestion, diaphragmatic hernia, traumatic abscesses of spleen and liver, rupture of the gastro-epiploic artery causing sudden death, diaphragmatic abscess and formation of abscess on lateral or ventral wall of abdomen in which foreign bodies are located (Krishnamurthy *et al*., 1985; Sobti *et al.,* 1987). However, very rarely a foreign body may get lodged into the omasum or intestine (Singh *et al*., 1993).

Ultrasonography is the method of choice for detecting characteristics of reticular motility, fibrinous deposits and abscessation which cannot be evaluated using radiography (Braun *et al*., 1994). Numerous ultrasonograhic studies have been performed for diagnosis of such affections in cows (Braun *et al*., 1993b; Braun *et al*., 1998; Saini *et al*., 2007). However, only few reports are available on comparison of ultrasonography, radiologic and surgical findings in cases of traumatic reticuloperitonitis in bovines. Therefore, the present study was undertaken to compare ultrasonographic, radiological and surgical findings in cases of reticuloperitonitis/ adhesions in buffaloes.

*Corresponding author: drmadanlega@gmail.com

MATERIALS AND METHODS

Animals and clinical examination

The study was conducted on 35 buffaloes presented to Veterinary Clinical Complex, Lala Lajpat Rai University of Veterinary and Animal Sciences, Hisar. For diagnosis of reticuloperitonitis, complete history of animals including age, duration of illness, feed intake, pregnancy status, milk yield, coughing, nasal discharge and presence/absence of tympany were recorded. Rectal temperature and ruminal motility was also recorded for all these animals.

Ultrasonographic examination

Ultrasonographic examination was performed on the standing animal restrained in a crush without any sedation. Then right lateral side of the animal at the level of the elbow from 3rd to 8th intercostal spaces was shaved and washed thoroughly with water. Ultrasonography was carried out using Famio 8 (Toshiba, Japan) ultrasound machine in real time B-mode and B+M mode using a curvilinear 3.7 MHz transducer. Scanning was done on right side of the abdomen at the level of sixth and seventh intercostal spaces. Transducer was placed parallel to ribs at the level of elbow. Foremost, the reticulum was observed using real time B-mode. Transducer was placed at the level of right elbow and moving towards the midline. The reticulum was located, observed for three minutes without moving the transducer. The anechoic shadow of fluid and hyperechoic shadow of fibrin deposits between the reticulum and abdominal wall was observed for presence of reticuloperitonitis. The reticular motility was observed in real time B+M mode at each intercostal space without movement of the transducer for three minutes.

Radiological examination

Siemens large animal X-ray machine having maximum mA of 600 and KVP of 150 was used for

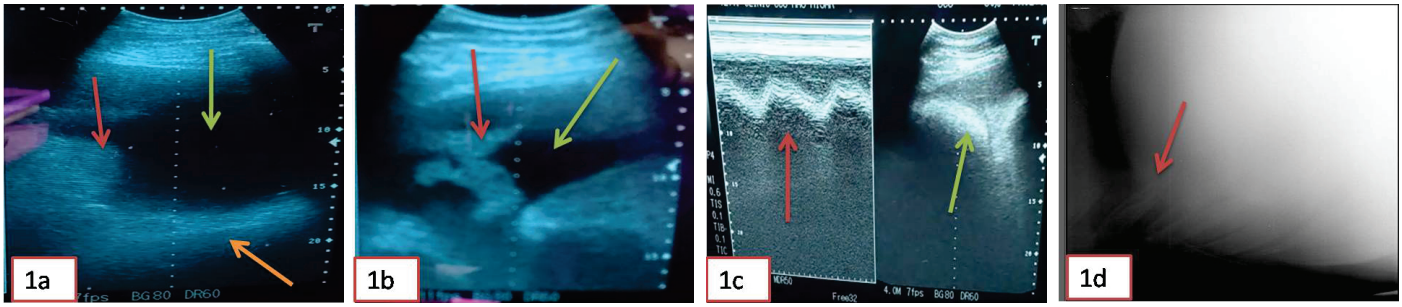

Fig. 1a: Ultrasonogram showing anechoic fluid (green arrow) with fibrin deposition (red arrow) between reticulum and abdominal wall. Orange arrow showing the hyperechoic reticular wall; 1b: Ultrasonogram showing hyperechoic fibrin particle (red arrows) floating in anechoic fluid (green arrow) with displaced reticular wall; 1c: B-mode ultrasonogram showing continuous crest and trough formation (red arrow) with respiration of animal in B+M mode ultrasonogram suggestive of reticulophrenic adhesions. Green arrow showing the hyperechoic half moon shape reticular wall; 1d: Radiograph showing discontinued diaphragmatic line and shadow of adhesions in mid ventral region (red arrow) with reticulum at its normal anatomical position in a suspected case of traumatic reticuloperitonitis/ adhesion.

radiography. The radiologic examination was performed in standing position after restraining in cattle crush. Exposure factors used for the present study were 150-160 mAs and 85- 90 KVP at a film focal distance of 90–100 cm. The radiographs were processed in the computed radiography system. The findings recorded upon the radiological examination included nature and location of foreign body (metallic or non-metallic), status of the diaphragm (clearly visible or hazy in appearance), abnormal gas shadow in the reticulum, adhesions and fluid bed on radiographs.

Laparorumentomy examination

Laparorumenotomy was performed under local analgesia using paravertebral block technique. Various findings of laparorumenotomy in cases of reticuloperitonitis/ adhesions recorded were ruminal contents (frothy, semisolid etc.), foreign bodies (penetrating and non-penetrating), peritoneal fluid or flakes, adhesions of the reticulum with the diaphragm and abdominal wall and adhesion of the rumen with the abdominal wall.

RESULTS AND DISCUSSION

In the present study, 35 cases were diagnosed by ultrasonography for presence of reticuloperitonitis and adhesions. Only 8 cases could be compared with radiological findings and confirmed by the laparorumenotomy because of unwillingness of the owners for surgery. Traumatic reticuloperitonitis was diagnosed in 35 animals (19 pregnant and 16 non-pregnant buffaloes) ageing 4-10 years. All the animals in the present study had reduced appetite, decreased milk production, ruminal atony or hypermotility and most of them had black hard faeces and recurrent tympany. The present study findings are in agreement with Radostitis *et al.* (2007) who stated that presence of such symptoms were considered as a general sign for indigestion. Misk *et al*. (1984) suggested that ingestion of foreign bodies, either sharp or blunt is commonly seen in bovine due to unselective feeding habits and this syndrome resulted in several clinical signs including various degrees of inappetance, recurrent tympany and decrease in milk yield. Singh *et al.* (2007) observed that formation of adhesions or purulent materials and compression on vagus nerve would cause interference with functioning of the reticulum and rumen and animal would show signs of chronic tympany, indigestion, coughing and improper passing of the faeces in cases of extra reticular pathology in buffaloes. In the present study, pregnant animals were affected more than non-pregnant. The gravid uterus propels the foreign body forwards towards the reticulum leading to traumatic reticuloperitonitis (Abdelaal *et al*., 2009).

In the present study, ultrasonographically, echogenic bands of fibrin were seen freely floating in anechoic fluid between abdominal wall and the reticular wall in 4 cases (Fig. 1a and 1b). The reticular wall was displaced due to excess amount of anechoic fluid present between abdominal wall and reticular wall (Fig. 1b). These cases were diagnosed for diffuse peritonitis. Athar *et al.* (2010) observed displaced reticular wall away from abdominal wall with an anechoic fluid without margin and which was not restricted around reticular area in cases of diffuse peritonitis in nine animals (2 cows and 7 buffaloes). In an earlier study, Mostafa *et al.* (2015) found that reticulum moved beyond the penetration depth of ultrasound waves due to accumulation of copious amount of inflammatory exudates in cases of diffuse peritonitis in buffaloes.

In majority of cases (n=4) in this study, corrugated appearance of the reticular wall with anechoic fluid, hyperechoic fibrin deposits between abdominal wall and reticulum was suggestive of the reticuloperitonitis and adhesions. Tharwat *et al.* (2012) recorded ultrasonographic

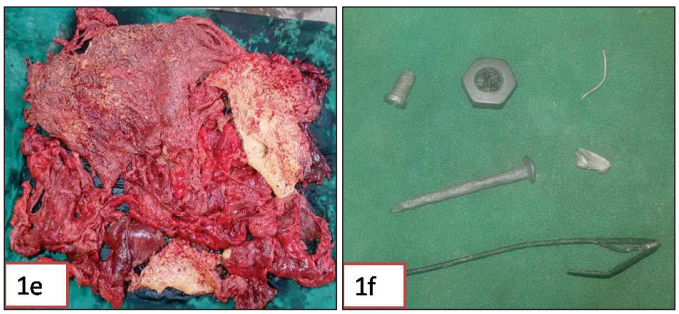

Fig. 1e: Fibrin removed from the peritoneal cavity; 1f: Foreign bodies removed from the reticulum.

features of traumatic reticuloperitonitis in buffaloes and revealed thick corrugated reticular wall with echogenic deposits between reticulum and abdominal wall and anechoic fluid compartment with hyperechoic fibrin strands. Ghanem *et al.* (2010) observed ultrasonographic features of traumatic reticuloperitonitis in cows and found echogenic deposits between ventral abdominal wall and reticular wall. Abdelaal *et al*. (2009) noted echogenic fibrinous strands between rumen, reticulum and abdominal wall in cases of chronic local peritonitis and hypoechoic exudates interspersed with echogenic fibrinous strands in acute diffuse peritonitis in buffaloes.

In the present study, reduction or absence of reticular contractility (n=6) was considered to be characteristic ultrasonographic findings in cases of reticuloperitonitis and adhesions. Adhesions in animals of the present study, possibly, a sequele of traumatic reticuloperitonitis, could be attributed to decreased reticular motility. Due to moderate or severe adhesions of the reticulum with the diaphragm and ventral abdominal wall, reduction or absence of reticular contractility was observed. Gouda (2015) stated that corrugated reticulum with reduction or absence of reticular contractibility was considered to be the characteristic ultrasonographic findings of different sequelae of traumatic reticuloperitonitis in buffaloes. Mostafa *et al.* (2015) observed that reduced frequency of reticular contraction in buffaloes with local peritonitis, abdominal and thoracic abscesses, traumatic pericarditis and pleuropneumonia might be attributed to inappetance, pain and adhesions between reticulum and surrounding organs.

In two animals, the reticular wall was seen partially contracted away from the transducer and appeared as continuous wave like pattern with respiration on B+M mode at the 6th and 7th intercostal spaces (Fig. 1c). These ultrasonographic findings were indicative of reticulophrenic adhesions. Kumar *et al.* (2007) also observed reticular movement with each respiration in cases of reticulophrenic adhesions. They also observed that the reticular wall slides along skin and muscle layer and at no time reticulum contracted away from the transducer in B-mode ultrasonography in cases of reticulophrenic adhesions. Singh *et al*. (2013) also recorded ultrasonographic features of reticulophrenic adhesions in 10 animals (1 cow and 9 buffaloes). Diagnosis was made for reticulophrenic adhesions on the basis of continuous wave like pattern (n=7) and small isolated wave of contraction (n=3) on B+M mode ultrasonogram at the 6th and 7th intercostal spaces.

Eight animals were compared radiologically, for reticuloperitonitis/adhesions after ultrasonographic examination. In the present study, radiographs were taken in standing position. On the basis of radiological findings, only 1 case was diagnosed for reticulophrenic adhesions (radiolucent density/spots on mid ventral area on the diaphragmatic line, Fig. 1d). In rest of 7 cases radiography failed to diagnose reticuloperitonitis/adhesions and these cases were suspected for diaphragmatic hernia, hydrothorax or traumatic pericarditis. Ducharme *et al*. (1983) suggested that radiograph taken in the standing position might be inaccurate in cases of traumatic reticuloperitonitis. Braun *et al*. (1993b) made diagnosis in 12 cows on the basis of radiological findings and observed penetrating foreign bodies outside of and cranial to reticulum. They suspected 9 cows for traumatic reticuloperitonitis because the reticulum was pushed away from diaphragm or ventral abdomen and reticular contour was indented (n=5). Singh *et al.* (2007) found that reticular abscess, reticular adhesions and septic peritonitis could be diagnosed by plain or contrast radiography. These lesions were divided on basis of the radiological examination into septic peritonitis showing contracted and lifted reticulum with radiolucent zone, extra-reticular abscess with distinct radiolucent area at the site of reticulum with irregular diaphragmatic line towards the ventral side and reticular adhesions showing radiopaque bands between reticulum and the diaphragmatic line. Braun *et al.* (1993b) suggested that a plain radiograph was the best tool to diagnose traumatic reticuloperitonitis and observed atypical position of foreign bodies, abnormal gas density in reticulum and depression in cranio-ventral margin of reticulum on radiographs in cases of traumatic reticuloperitonitis. Samad *et al*. (1994) observed radiological examination or exploratory rumenotomy as the 'gold-standard' test to diagnose traumatic reticuloperitonitis. Braun *et al.* (1994) revealed that radiography was best suited for the visualization of position of metallic foreign bodies in and outside the reticulum and observed radiography was the best reliable indicator for diagnosing traumatic reticuloperitonitis

Exploratory laparorumenotomy was performed in 8 cases and all these cases were found positive for traumatic reticuloperitonitis and adhesions. In the present study, peritoneal fluid increased in 6 cases. Fibrotic material was also removed on laparorumenotomy in 6 cases. In 1 case, large amount of fibrotic contents was removed from the peritoneal cavity (Fig. 1e). In addition to it, diffused nodular growths were also observed on the serosal surface of rumen. It was evident for diffused form of peritonitis. In another case, rumen was seen adhered with the left abdominal wall and some fibrin flakes were also removed from the peritoneal cavity. Six animals (75%) were having potentially penetrating foreign bodies in the reticulum (Fig. 1f) while in 2 cases (25%) no foreign body was retrieved from the reticulum. Ghanem (2010) suggested that honeycomb like structure of the reticulum provided many sites for fixation of a foreign body and contractions of reticulum and pressure of calf during late pregnancy might be sufficient to push a sharp foreign body through the wall, inducing traumatic reticuloperitonitis in animals. Perforation of the reticular wall by a sharp foreign body initially produces an acute local peritonitis which may recover, spread to cause acute diffuse peritonitis,

become persistent to cause chronic peritonitis or may extend beyond the peritoneum and cause involvement of other organs like pericardium to cause acute pericarditis (Radostits *et al*., 2007). In addition to it, a fibrous cord of approximately 4-5mm long was also present at the caudal aspect of the reticulum in 1 subject. A metallic wire was located deeply embedded in the mucosa of reticulum. Reticular adhesions with abdominal wall were also recorded. Singh *et al.* (2007) also noted extra reticular adhesions in 10 buffaloes and found reticulum to be adhered with surrounding structures confirming these cases to be of extra reticular adhesions. The normal peritoneal layer and few tracts present on both sides cranially and laterally of the reticulum were also observed.

Braun *et al*. (1993a) suggested that pain, fever, adhesions and obstruction were the protective measures in cases of traumatic reticuloperitonitis and affected the gastric centre in medulla oblongata. It resulted in hypomotility or atony of reticular or ruminal motility thus possibly to keep the infection localised and prevented it being disseminated. Varying degrees of reticular adhesions with the diaphragm and abdominal wall were observed. Imran *et al*. (2012) also recorded reticulophrenic adhesions on laparorumenotomy in cows affected with traumatic reticuloperitonitis. In the present study, ultrasonography proved to be a safe and valuable tool for diagnosis of traumatic reticuloperitonitis. This technique proved to be superior to radiography in comprehensive evaluation of the reticular contour, reticular contraction, fibrinous depositions/adhesions and abnormal fluid accumulation in cases of traumatic reticuloperitonitis in buffaloes.

REFERENCES

Abdelaal, A.M., Floeck, M., Maghawry, S.E. and Baumgartner, W. (2009). Clinical and ultrasonographic differences between cattle and buffaloes with various sequelae of traumatic reticuloperitonitis. *Vet. Med.* **54(9):** 399-406.

Athar, H., Mohindroo, J., Singh, K., Kumar, A. and Randhawa, C.S. (2010). Clinical, haemato-biochemical, radiographic and ultrasonographic features of traumatic reticuloperitonitis in bovines. *Indian J. Anim. Sci.* **80(7):** 608-612.

Braun, U., Fluckiger, M. and Gotz, M. (1994). Comparison of ultrasonographic and radiographic findings in cows with traumatic reticulo-peritonitis. *Vet. Rec*. **135:** 470-478.

Braun, U., Gotz, M. and Marmier, O. (1993a). Ultrasonographic findings in cows with traumatic reticuloperitonitis. *Vet. Rec.* **133:** 416-422.

Braun, U., Fluckiger, M. and Nageli, F. (1993b). Radiography as an aid in the diagnosis of traumatic reticuloperitonitis in cattle. *Vet. Rec*. **132:** 103-109.

Braun, U., Iselin, U., Lischer, C. and Fluri, E. (1998). Ultrasonographic findings in five cows before and after treatment of reticular abscesses. *Vet Rec*. **142:** 184-189.

Ducharme, N.G., Dill, S.G. and Rendano, V.T. (1983). Reticulography of the cow in dorsal recumbency: An aid in the diagnosis and treatment of traumatic reticuloperitonitis. *J. Am. Vet. Med. Assoc.* **182(6):** 585-588.

Ghanem, M.M. (2010). A comparative study on traumatic reticuloperitonitis and traumatic pericarditis in Egyptian cattle. *Turkish. J. Vet. Anim. Sci*. **34(2):** 143-153.

Gouda, S.M. (2015).Ultrasonographic identification of abdominal and thoracic lesions resulting from foreign body syndrome in buffaloes. *Res. J. Vet. Pract*. **3(2):** 41-46.

Imran, S., Sharma, S. and Bhat, A. (2012). Ultrasonographic imaging of normal reticulum and traumatic reticuloperitonitis in crossbred cows. *Eurasian J. Vet. Sci*. **28(4):** 214-221.

Jeffery, L.W. and Ducharme, N.G. (1994). Traumatic reticuloperitonitis in dairy cows. *J. Am. Vet. Med. Assoc.* **204:** 874-877.

Krishnamurthy, D., Nigam J.M., Peshin, P.K., Sharma D.N. and Tyagi, R.P.S. (1985). Monograph of diaphragmatic hernia in bovine. Directorate of Publications, Haryana Agriculture University, Hisar-125004, India.

Kumar, M., Mohindroo, J., Kumar, A. and Singh, S.S. (2007). Ultrasonographic study of reticulophrenic adhesions in bovines. A report on 15 clinical cases. *Indian J. Vet. Surg.* **28(2):** 117–119.

Misk, N.A., Nigam, J.M. and Rafat, J.F. (1984). Management of foreign body syndrome in Iraqi cattle. *Agri. Pract*ice. **5:** 19-21.

Mostafa, M.B., Abu-Seida, A.M., Abdelaal, A.M., Al-Abbadi, O.S. and Abbas, S.F. (2015). Ultrasonographic features of the reticulum in normal and hardware diseased buffaloes. *Res. Opin. Anim. Vet. Sci.* **5:** 165-171.

Orpin, P. and Harwood, D. (2008). Clinical management of traumatic reticuloperitonitis in cattle. *In. Practice*. **30:** 544-551.

Radostits, O.M., Gay, C.C., Hinchcliff, K.W. and Constable, P.D. (2007). In: Veterinary medicine. A textbook of the diseases of cattle, horses, sheep, pigs and goats. 10th edn. Saunders Elsevier, Philadelphia. pp. 189-382.

Saini, N.S., Kumar, A., Mahajan, S.K. and Sood, A.C. (2007). The use of ultrasonography, radiography, and surgery in the successful recovery from diaphragmatic hernia in a cow. *Canadian Vet. J.* **48(7):** 757-759.

Samad, A., Awaz, K.B. and Sarkate, L.B. (1994). Diagnosis of bovine traumatic reticuloperitonitis 1: Strength of clinical signs in predicting correct diagnosis. *J. Appl. Anim. Res*. **6:** 13-18.

Singh, J., Singh, A.P. and Patil, D.B. (1993). In: Ruminant Surgery. CBS Publishers and Distributors, New Delhi, India. pp. 175-182.

Singh, P., Chander, S. and Singh, A.P. (2007). Extra reticular pathology in buffaloes: report of fifty clinical cases. *Haryana Vet.* **46:** 107-109.

Singh, S., Mohindroo, J., Kumar, A. and Sangwan, V. (2013). B+M mode ultrasonography in evaluating reticular health in cows and buffaloes. *Indian J. Vet. Res*. **22(2):** 52-58.

Sobti, V.K., Singh, S., Sharma, S.N. and Sharifi, D. (1987). Surgical management of extra reticular fibrous nodules in a buffalo. *Indian Vet. J.* **64:** 419-421.

Tharwat, M., Ahmed, A.F. and El-Thooky. (2012). Chronic peritonitis in buffaloes and cattle: Clinical, haematological, ultrasonographic findings and treatment. *J. Ani. Vet. Adv.* **11(15):** 2775-2778.