*Haryana Vet.* (Dec., 2019) **58(2),** 201-204

**Research Article**

# MORPHOLOGICAL VARIATION IN CELLULAR AND FIBROUS COMPONENTS IN BUFFALO TESTIS DURING DIFFERENT SEASONS

BEENISH ASLAM, NEELAM BANSAL*, VARINDER UPPAL and ANURADHA GUPTA
Department of Veterinary Anatomy, College of Veterinary Sciences,
Guru Angad Dev Veterinary and Animal Sciences University, Ludhiana-141 004, India

Received: 10.11.2018; Accepted: 11.07.2019

## ABSTRACT

The present study was conducted on testes of 24 buffaloes during summer, autumn, winter and spring seasons. The tissue samples were fixed in 10% neutral buffered formalin (NBF) and processed as per acetone benzene schedule. The present study revealed moderate morphological alterations in the spermatogenic cells during different seasons. In summer season, there was decrease in the spermatogenesis with few Leydig cells in the interstitial tissue. The elongated spermatids were deeply stained and remained attached to the Sertoli cells during summer and showed morphological deformities. During autumn and spring season, the seminiferous tubules showed moderate proliferation in the process of spermatogenesis, whereas in winter, the seminiferous tubules were larger in size and contained all types of spermatogenic cells and deeply stained spermatids in their lumen. All the stages of seminiferous epithelial cycle were differentiated and different cell types were seen during winter season but there was reduction in different spermatogenic cells in other seasons. The difference in the morphological status of active spermatogenesis during different seasons may be correlated with the production of spermatozoa, semen plasma and testosterone during different seasons.

**Keywords:** Buffalo testis, Morphology, Seasons

Testis is the main organ responsible for production of testosterone and spermatozoa, hence performing both endocrine and exocrine functions. The testicular parenchyma is composed of seminiferous tubules from which spermatozoa are produced to maintain spermatogenesis and Leydig cells for production of testosterone required for male sexuality (Hafez and Hafez, 2000). In available literature, most of the studies have been made on the histomorphology and histochemistry of testis in buffalo (Singh, 1996) and in cattle bull (Gofur *et al.*, 2008), the earlier studies indicated that the testicular morphology changed with respect to the season of the year in Ram (Colas *et al.*, 1986), Buck (Bitto and Egbunike, 2006), Gaddi goat and Gaddi sheep (Sudhakar *et al.*, 2010) and Brahman and Hereford bull (Godfrey *et al.*, 1990). But scanty information is available on the seasonal effect on the morphological and histomorphometric aspects on testis of buffalo bull (Arrighi *et al.*, 2010). So the present study was conducted to study the effect of season on testicular morphology in buffalo bulls to improve the male fertility.

## MATERIALS AND METHODS

The present study was conducted on right and left testes from 24 buffaloes slaughtered at slaughter house Dera Bassi. Depending upon the season of the year, the animals were divided into four groups with six animals in each group *viz*. Group I: Spring season (from March to May), Group II: Summer seasons (from June to August), Group III: Autumn season (from September to November) and Group IV: Winter (from December to February). Immediately after collection, the samples were fixed in 10% neutral buffered formalin (10% NBF) and were processed for paraffin blocks preparation by acetone benzene schedule (Luna, 1968). The paraffin sections of 5-6 µm were obtained on glass slides with the help of rotary microtome and were stained with Hematoxylin and eosin to observe the routine histomorphology, Masson's Trichrome for collagen fibres, Gridley's for reticular fibres, Verhoeff's for elastic fibres and Holmes's for neuronal elements. Micrometrical parameters were recorded on Hematoxylin and eosin stained sections by means of standard method of micrometry using Nikon 80i camera mounted microscope with the help of image J software

*Corresponding author: bansal.neelam@rediffmail.com

## RESULTS AND DISCUSSION

Seminiferous tubules were lined by stratified germinal epithelium surrounded by lamina propria. The seminiferous tubules consisted of two types of cells: (i) Sustentacular cells/Sertoli cells (ii) Spermatogenic cells

**Sustentacular cells:** The sustentacular cells were irregularly columnar cells that extended from the basal lamina to the lumen of tubules. The oval or spherical nucleus was located near the base. The recesses on their cell membrane were occupied with the spermatogenic cells of different shapes. At the apical region of their cytoplasm many sperms were embedded as recorded by Banks (1993) in domestic animals, while Bacha and Bacha (2000) mentioned that the nucleus of the Sertoli cells was triangular or oval with prominent nucleolus. Kishore *et al.* (2007) in ram reported that the Sertoli cells were elongated with ellipsoidal shaped nuclei. The number and size of

Sertoli cells was more during spring (Fig. 1), autumn (Fig. 3) and winter (Fig. 4) than summer season (Fig. 2).

**Spermatogenic cells:** The spermatogenic cells were situated between the Sertoli cells in an orderly manner with four to eight layers occupying the space between the basal lamina and lumen of seminiferous tubules. These findings are similar to the observation of Gofur *et al.* (2008) in bull and Archana *et al.* (2014) in goat testis. The primitive germ cells or spermatogonia, from which all of the spermatozoa were ultimately derived, were located directly inside the basement membrane. They were spherical or cuboidal in shape and had spherical nuclei. The primary spermatocytes were next to the spermatogonia on their inner side. These were large cells with round or spherical nuclei. They had the biggest nuclei than the nuclei of other spermatogenic cells. The meiotic phase of primary spermatocytes was well recognized in different stages of the tubules. The secondary spermatocytes were internal to the primary spermatocytes and smaller than the primary spermatocytes but larger than the round spermatids. They were rounded in shape and their nuclei were spherical with centrally located small dot like of chromatin. The cytoplasm was scanty and eosinophillic. The spermatids adjoined the lumen of the tubules were easily recognized by their small size which were of round and elongated type. The round spermatids were smallest cells of the spermatogenic series. Which was in agreement with the findings reported by Bordalai (1979) in goat, Kaur (2006) in buffalo fetus, Kishore (2006) in sheep and Lambate (2012) in pigs. The location of spermatozoa was found in the lumen of the tubules. These findings were similar to the observations of Hafez and Hafez (2000) in domestic animals and Gofur *et al.* (2008) in bull.

The present study revealed moderate morphological alterations in the spermatogenic cells during different seasons. In summer season there was decline in the spermatogenesis with few Leydig cells in the interstitial tissue (Fig. 2). The elongated spermatids were deeply stained and remained attached to the Sertoli cells during summer and showed morphological deformities. During autumn and spring season the seminiferous tubules showed moderate proliferation in the process of spermatogenesis (Figs. 1 and 3) whereas in winter season normal spermatogenesis was observed (Fig. 4). The seminiferous tubules were larger in size and contained all types of spermatogenic cells and deeply stained spermatids in their lumen during this season as reported in Iraqi buffalo bull (Ibrahim *et al.*, 2013).

**Seminiferous epithelial cycle:** The stages of seminiferous epithelial cycle in different seasons were recognized based on their morphology. The primitive germ cells or spermatogonia, from which all of the spermatozoa were ultimately derived, were located directly inside the basement membrane. They were spherical or cuboidal in shape and had spherical nuclei. The primary spermatocytes were next to the spermatogonia on their inner side. They were large cells and their nuclei were round or spherical. They had the biggest nuclei than the nuclei of other spermatogenic cells. The meiotic phase of primary spermatocytes was well recognized in different stages of the tubules. The leptotene primary spermatocytes were uniformly rounded cells with spherical nuclei. The cytoplasm was lightly stained and formed a thin periphery around the nucleus. The zygotene primary spermatocytes were marked by darkly stained nuclei and cytoplasm was pale stained. The pachytene primary spermatocytes were characterized by large spherical cells and their nuclei were uniformly spheroids. The nuclear envelope was indistinct and nucleoli were small and faintly stained. The diplotene primary spermatocytes were characterized by their largest size of the spermatogenic series. They were lightly stained than pachytene nuclei. The secondary spermatocytes were internal to the primary spermatocytes and smaller than the primary spermatocytes but larger than the round spermatids. They were rounded in shape and their nuclei were spherical with centrally located small dot like of chromatin. The cytoplasm was scanty and eosinophillic. The round and elongated type spermatids adjoined the lumen of the tubules were easily recognized by their small size. The round spermatids were smallest cells of the spermatogenic series with spherical nuclei and thin peripheral cytoplasm rim. The aggregated chromatin particles were stained much more intensely than the surrounding nuclear matter. The nuclear membrane was thin and prominent. The elongating spermatids were characterized by their elongating nuclei and the elongated spermatids were characterized by elongated nuclei with condensed chromatin. They stained more deeply and usually remain attached to the Sertoli cells. Thereafter, they migrated centripetally towards the lumen of the tubules. Before release as mature spermatozoa, they were seen in the lumen with detached acidophillic cytoplasmic masses. All the stages of seminiferous epithelial cycle were differentiated and different cell types were seen during winter season but there was reduction in different spermatogenic cells in other seasons (Figs 1, 2, 3 and 4). The lumen of seminiferous tubules showed less number of elongated spermatids during spring and autumn season. The difference in the morphological status of active

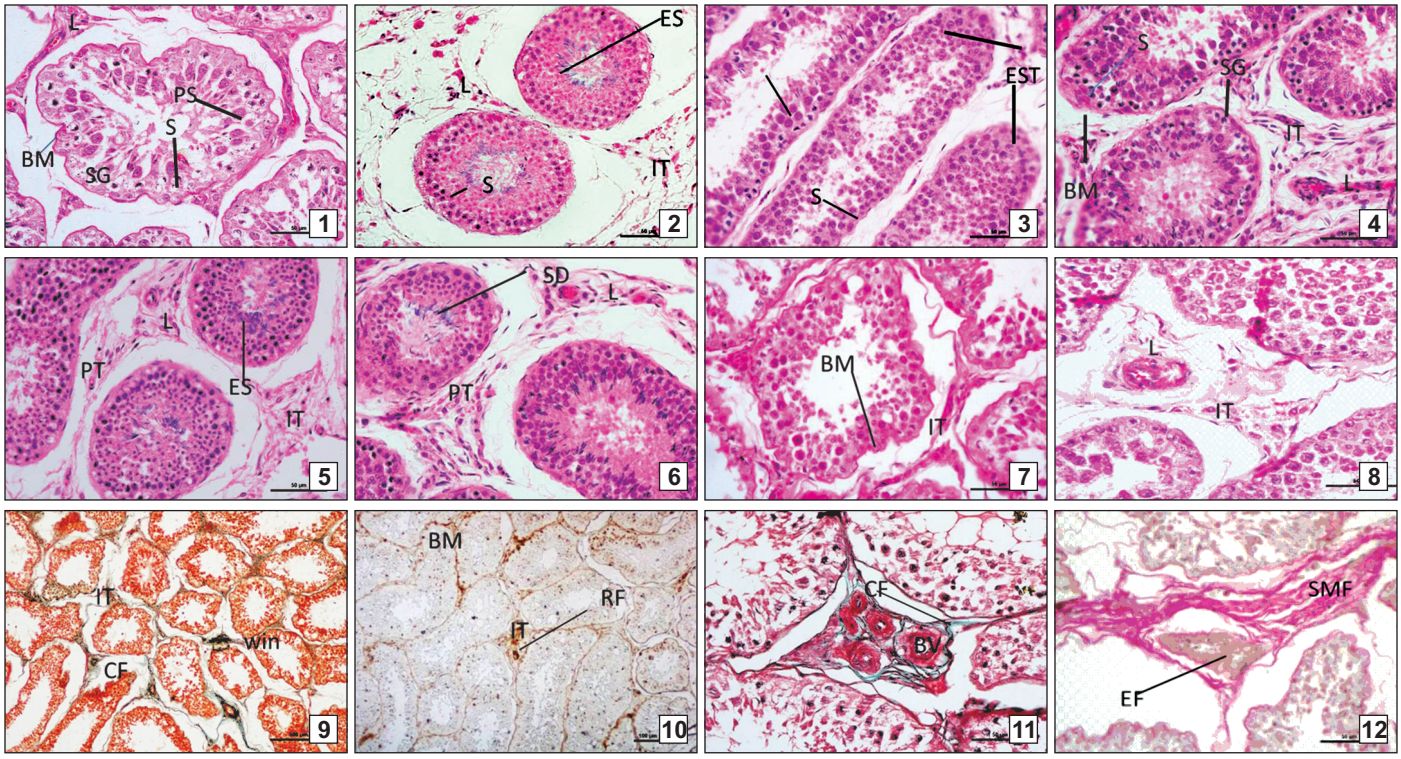


Figs. **1.** Folding of basement membrane (BM), moderate number of spermatogenic cells with primary spermatocytes (PS), round spermatids, Sertoli cells (S) and Leydig cells (L) during spring season. Hematoxylin and Eosin stain x 400; **2.** Decrease in the spermatogenic cells with few deeply stained elongated spermatids (ES) in the seminiferous tubules and with few Leydig cells (L) in the interstitial tissue (IT) and Sertoli cells (S) during summer season. Hematoxylin and Eosin stain x 400; **3.** Elongated seminiferous tubules (EST) with moderate proliferation of spermatogenic cells and sertoli cells (S) during autumn season. Hematoxylin and Eosin stain x 400; **4.** Increase in the dividing stages of spermatogenic cells, deeply stained spermatozoa in lumen and spermatogonia (SG) resting on smooth basement membrane (BM), more number of Leydig cells (L) in interstitial tissue (IT) and Sertoli cells (S) during winter season. Hematoxylin and Eosin stain x 400; **5.** Leydig cells (L) present in small groups light or dark stained in the interstitial tissue (IT), 1-2 layers of peri-tubular cells (PT) and elongated spermatids (ES) during autumn season. Hematoxylin and Eosin stain x 400; **6.** Increase in the number of Leydig cells (L), 2-3 layers of peri-tubular cells (PT) and deeply stained spermatids (SD) in seminiferous tubules during winter season. Hematoxylin and Eosin stain x 400; **7.** Increase in amount of interstitial tissue (IT) and folding of basement membrane (BM) during spring season. Hematoxylin and Eosin stain x 400; **8.** Decrease in number of Leydig cells (L) in interstitial tissue (IT) during summer season. Hematoxylin and Eosin stain x 400; **9.** Presence of collagen fibres (CF) in the basement membrane of seminiferous tubules and interstitial tissue (IT) during winter season. Masson's Trichrome stain x 100; **10.** Reticular fibres (RF) surrounding the basement membrane (BM) of seminiferous tubules and in the interstitial tissue (IT) during spring season. Gridley's stain x 100; **11.** More amount of collagen fibres (CF) observed near blood vessels (BV) in the interstitial tissue during winter season. Masson's Trichrome stain x 100; **12.** Interstitial tissue comprised of smooth muscle fibres (SMF) and few elastic fibres (EF) in the tunica intima of blood vessels during spring season. Verhoeff's stain x 400

spermatogenesis during different seasons may be correlated with the production of spermatozoa, semen plasma and testosterone during different seasons.

**Basement membrane:** The seminiferous tubules were surrounded by peritubular tissue which was made up of basal lamella and cellular layer. Basal lamella was composed of mainly collagen and elastic fibres with few reticular and nerve fibres. These findings are in accordance with the reports of Hafez and Hafez (2000), Eurell and Frappier (2006) in domestic animals and Lambate (2012) in pigs.

The amount of collagen and elastic fibres were more in basal lamina of winter, spring and autumn season (Fig. 9), whereas the reticular fibres were comparatively more in summer and winter than other season (Fig. 10). Amount of nerve fibres were more in basal lamina of seminiferous tubules during spring than summer season. Skinner *et al.* (1985) suggested that basal lamina underlying seminiferous tubular epithelium was a shared product of Sertoli cells and peritubular cells in post natal life. The basement membrane showed folding separating each of the tubules from adjacent tissue in spring season, however no such folding was observed during any other seasons.

**Peritubular tissue:** Peritubular tissue consisted of inner non-cellular layer and outer layer of myoid and fibroblast cells. The myoid cells were elongated and situated as a single layer external to the seminiferous tubules during summer season (Fig. 2) but in other seasons double layer of myoid cells was observed (Figs. 3, 4 and 5). Peritubular tissue was more in autumn and winter than spring and summer. Similar findings have been reported by Kishore (2006) in sheep. According to Kaur (2006) peritubular cells may be responsible for maintaining the structural integrity of seminiferous tubules.

**Interstitial tissue:** The interstitial tissue was observed in space present between the seminiferous tubules, which consisted of cellular and fibrous components and blood and lymph vessels in loose connective tissue. The cellular component consisted mainly of mesenchymal cells, fibroblasts and the interstitial cells or the Leydig cells. The Leydig cells of different shapes and size were either seen as clusters or randomly scattered. These cells were polymorphous with light or dark stained spherical and eccentric nuclei and granular cytoplasm located in small groups around the blood vessels in the interstitial space (Figs. 5, 6, 7 and 8). Similar findings were recorded by Banks (1993) in domestic animals, Bacha and Bacha (2000) and Eurell and Frappier (2006) in domestic animals. The presence of these cells in close proximity of blood vessels indicated their endocrine nature as described by Kaur (2006) in buffalo fetal testis. It was also observed that these Leydig cells were more in number and size in autumn and winter season than summer and spring season. As the Leydig cells were androgen producing cells so their number was increased in winter indicating more sexual activity in this season. The fibrous component consisted mainly of collagen fibres and a few elastic (Figs. 11 and 12) and reticular fibres. The collagen fibres predominate over the reticular fibre in this network. The amount of collagen fibres were more in winter and spring but relatively less in autumn season. However, collagen fibres were not demonstrable in interstitial tissue during summer season. The elastic fibres were seen in abundance in tunica intima and tunica media of blood vessels during autumn and winter season than spring and summer. Blood vessels and lymphatics were also seen in the loose connective tissue. Similar findings have been reported by Kishore *et al.* (2007) in sheep that the intertubular area decreased as the age advances.

## REFERENCES


Archana, P., Katiyar, R.S., Sharma, D.N., Farooqui, M.M. and Prakash, A. (2014). Postnatal development of testis in Gaddi goat (*Capra hircus*). *Int. J. Morphol.* **32**: 166-176.

Arrighi, S., Bosi, G., Groppetti, D. and Cremonesi, F. (2010). Morphological and histometric evaluations on the testis and epididymis in buffalo bulls during the different reproductive seasons. *Open Anat. J.* **2**: 29-33.

Bacha, W.J. and Bacha, C.M. (2000). Colour Atlas of Veterinary Histology (2nd Edn.). Lippincottt, Williams and Wilkins, Baltimore. pp. 203-204.

Banks, W.J. (1993). Male Reproductive System in Applied Veterinary Histology (3rd Edn.). Mosby Year Book, St. Louis, Baltimore. pp. 429–438.

Bitto, I. and Egbunik, G.N. (2006). Seasonal variations in morphometric characteristics of African dwarf buck in its native tropical environment. *Int. J. Morph.* **24**: 637-642.

Bordalai, C.C. (1979). Seasonal variations on the cytomorphological and cytochemical architecture of the testis in sexually mature male goats. Ph.D. thesis submitted to Haryana Agricultural University, Hisar, Haryana.

Colas, G., Guerin, Y., Lemaire, Y., Montassier, Y. and Despierres, J. (1986). Seasonal variation in the testis diameter and sperm morphology in the vendean ram and texel ram. *Repro. Nutr. Devel.* **26**: 863-875.

Eurell, J.A. and Frappier, B.L. (2006). Dellmann's Textbook of Veterinary Histology (6th Edn.). Blackwell Publishing Ltd., UK. pp. 233–245.

Godfrey, R.W., Lunstra, D.D., Jenkins, T.G. and Randel, R.D. (1990). Effect of location and season on body and testicular growth in Brahman and Hereford bull. *J. Anim. Sci.* **68**: 1520-1529.

Gofur, M.R., Khan, M.Z.I., Karim, M.R. and Islam, M.N. (2008). Biometry of testis of indigenous bull (*Bos indicus*) of Bangladesh in relation to body weight and scrotal circumference. *J. Bangla. Soc. Agri. Sci. Tech.* **4**: 205-208.

Hafez, B. and Hafez, E.S.E. (2000). Reproduction in Farm Animals (7th Edn.). Lippincott, Williams and Wilkins, Philadelphia. p. 7.

Ibrahim, N.S., Al-sahaf, M.M.H. and Alwan, A.F. (2013). Reproductive activity of mature Iraqi bull buffaloes: Testes dimensions and histological picture. *Int. J. Ani. Vet. Adv.* **5**: 34-37.

Kaur, M. (2006). Studies on histogenesis and organogenesis of the testis in buffalo (*Bubalus bubalis*). M.V.Sc. thesis submitted to Guru Angad Dev Veterinary and Animal Sciences University, Ludiana, Punjab.

Kishore, P.V.S. (2006). Histological and histochemical studies on the testis and its duct system in sheep (*Ovis aries*). M.V.Sc. thesis submitted to Tamil Nadu Veterinary and Animal Science University, Chennai.

Kishore, P.V.S., Ramesh, G. and Basha, S.H. (2007). Intertubular tissue in the testes of ram: a postnatal histological study. *Indian J. Vet. Anat.* **19**: 7-10.

Lambate, S.B. (2012). Gross anatomical, histomorphological and ultrastructural studies of testis during postnatal development in pig (*Sus domesticus*). Ph.D. thesis submitted to Maharashtra Animal and Fishery Sciences University, Nagpur.

Luna, L.G. (1968). Manual of Histological Staining Methods of Armed Forces Institute of Pathology (3rd Edn.). McGraw Hill Book Company, New York, USA. pp. 38-196.

Singh, P. (1996). Histological, histochemical and histoenzymic studies on the post natal development and differentiation of seminiferous epithelium and Leydig cells in buffalo testis. M.V.Sc. thesis submitted to Punjab Agricultural University, Ludhiana, India.

Skinner, M.K., Tung, P.S. and Fritz, I.B. (1985). Cooperativity between sertoli cells and testicular peritubular cells in the production and desposition of extracellular matrix components. *J. Cell. Biol.* **100**: 1941-1947.

Sudhakar, L.S., Bhardwaj, R.L. and Pathak, V. (2010). Effect of season on the histology and histochemistry of the male genital organs of Gaddi goat and Gaddi sheep. ICAR Project. Indian Council of Agricultural Research, New Delhi. pp. 1-59.