Haryana Vet. (Dec., 2019) **58(2),** 248-250

Research Article

HISTOLOGICAL AND HISTOCHEMICAL STUDIES ON THE LACRIMAL GLAND OF THE GOATS

TEJ PARKASH*, PAWAN KUMAR, PARVEEN KUMAR GAHLOT and AMANDEEP SINGH
Department of Veterinary Anatomy, College of Veterinary Sciences
Lala Lajpat Rai University of Veterinary and Animal Sciences, Hisar-125 004, India

Received: 29.06.2019; Accepted: 26.08.2019

ABSTRACT

The present study was planned to study the histology and histochemistry of the lacrimal gland of six healthy young goats of local mixed breed. The gland was located at the dorsolateral aspect of the eyeball. The lacrimal gland of goat characterized as compound tubulo-acinar type was surrounded by a thin layer of connective tissue which penetrated into the gland and divided the parenchyma into lobes and lobules. The glandular parenchyma was comprised of serous, mucous and mixed type of acinar cells. Few plasma cells, nerve fibers and lymphocytes were observed in the glandular parenchyma. Glandular acini were surrounded by myoepithelial cells. Histochemical studies showed mixed distribution of acidic and neutral mucopolysaccharides as demonstrated by PAS-Alcian blue method. Mayer's mucicarmine, colloidal iron and Alcian blue showed positive activity for acidic mucopolysaccharides in only few acini. The mucous acini showed positive reaction for glycogen.

Key words: Histochemistry, Histology, Goat, Lacrimal gland

In all mammals, the surface of the eye is protected, nourished and lubricated by the aqueous tears that are synthesized and secreted by the lacrimal gland. The lacrimal apparatus comprised of the lacrimal gland, canaliculi, lacrimal sac and naso-lacrimal duct. The lacrimal glands have unique structures of possessing both epithelial and lymphoid tissue. So it plays an important part in eye health as the warm and wet area of the eye is an ideal site of pathogens' growth and invades into the body system. The research has been carried out on the histology of lacrimal glands in canine (Martin *et al.*, 1988), pig (Kuhnel and Scheele, 1979), ruminants (Triveni *et al.*, 2018) and sheep (Singh *et al.*, 2018). However, there is a paucity of literature on the light microscopic details of the lacrimal gland in young goat that led us to pursue the present study keeping in view the importance of lacrimal gland in young goat.

MATERIALS AND METHODS

The present study was conducted on 06 healthy young goats of either sex, of local mixed breed. The heads were procured from local slaughter house immediately after decapitation and fixed in 10% neutral buffered formalin solution for 48 h. The tissues were collected and processed for routine paraffin technique of light microscopy. The paraffin sections of 5-6 μ were cut through the entire gland and stained by routine Harris' haematoxylin and eosin method for general histomorphological examination, Gomori's method for reticular fibres, Weigert's method for elastic fibres, Alcian blue method for muco-substances (pH 2.5), McManus' method for glycogen (PAS), PAS-Alcian blue method for acidic and neutral mucosubstances (pH 2.5), Meyer's mucicarmine method for mucin, colloidal iron method for acid mucopolysaccharides (Luna, 1968) and Crossman's trichrome stain for collagen fibres (Crossman, 1937).

RESULTS AND DISCUSSION

The lacrimal gland was situated on the dorsolateral aspect of the eyeball lying under the periosteum of the supraorbital process of the frontal bone. It was a flattened, oval in shape and light brown in colour. It was surrounded with a periorbital tissue. Histologically, the lacrimal gland of goat characterized as compound tubulo-acinar type as reported earlier in the small ruminants (Daryuos and Ahmed, 2012), cattle and bison (Pinard *et al.*, 2003) and buffalo (Girgiri and Kumar, 2018). Whereas it was compound tubule-alveolar in camel (Mohammadpour, 2011). It was surrounded by a thin layer of connective tissue which penetrated into the gland and divided the parenchyma into lobes and lobules (Fig. 1), which was in agreement with findings in buffalo (Girgiri and Kumar, 2018). The lobules were of different dimensions. The glandular acini were separated from each other by connective tissue especially collagen and elastic fibers along with blood vessels of different dimensions and also possessed excretory ducts as reported by Abbasi *et al.* (2014) in Lori sheep and Singh *et al.* (2018) in sheep. Few plasma cells, nerve fibers and lymphocytes were observed in the glandular parenchyma (Fig. 2).

The glandular parenchyma was comprised of serous, mucous and mixed type of acinar cells (Fig. 2) as observed earlier in small ruminants (Daryuos and Ahmed, 2012) and sheep (Singh *et al.*, 2018). In contrast, canine lacrimal glands were reported as being purely mucus-secreting glands (Martin *et al.*, 1988). The cells in serous acini were cuboidal to low columnar and nuclei were round

*Correspondence author: yadavdrtp@gmail.com

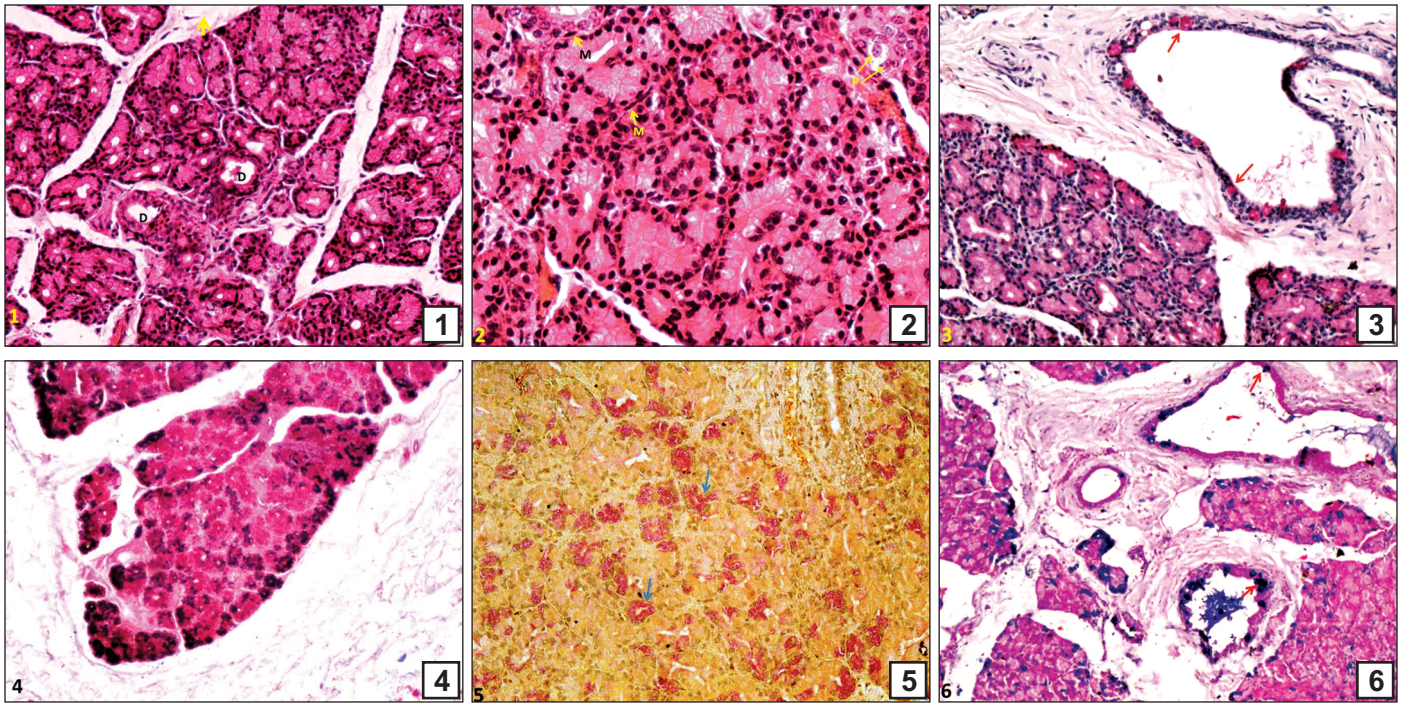

Fig 1. Photomicrograph showing the interstitial tissue (arrow) present between adjacent secretory units contains numerous small blood vessels and intralobular ducts (D) in the lacrimal gland of goat. H. & E. × 100.

Fig 2. Photomicrograph of lacrimal gland of goat at higher magnification showing glandular parenchyma comprised of mixed type of acinar cells with myoepithelial cell. Scattered plasma cells (P) were also observed. H. & E. × 400.

Fig 3. Photomicrograph of lacrimal gland of goat showing a moderate positive reaction of periodic acid-Schiff (PAS) in the secretory units and goblet cells (arrow) present in ducts. PAS x 100.

Fig 4. Photomicrograph showing positive reaction for both neutral as well as acid mucopolysaccharides in the secretory units, the peripheral part of lacrimal gland showed more positive reaction for PAS-Alcian blue method. PAS-AB x 100.

Fig 5. Photomicrograph of lacrimal gland of goat showing positive reaction for mucicarmine activity in the secretory units (arrow) Mayer's Mucicarmine x 100.

Fig 6. Photomicrograph of lacrimal gland of goat showing a moderate acidic sulfated mucosubstances, sialomucins and hyaluronic acid in the secretory units and ductal epithelium (arrow). Alcian blue x 100.

to oval in shape. The cytoplasm of all these cells was finely granular and eosinophilic in nature. The mucous glandular acini presented basophilic nuclei towards the basal portion and the cytoplasm was having the vacuolated appearance. Glandular acini were surrounded by myoepithelial cells. The nuclei of the myoepithelial cell were elongated oval, lied parallel and interposed between the basal surface and the basement membrane (Fig. 2). The serous and mucous parts were mixed together but in some areas the serous acini were dominant while at other places, the mucous ones were more dominant.

The histochemical studies showed positive reaction for the presence of glycogen mucous acini (Fig. 3). The mucous glands showed mixed distribution of acidic and neutral mucopolysaccharides as demonstrated by PAS-Alcian blue method. Only isolated mucous acini showed positive reaction indicating presence of acidic mucopolysaccharides. Peripheral part of lacrimal gland showed more positive reaction for PAS-Alcian blue method (Fig. 4). This finding is similar to the earlier reports in buffalo (Girgiri and Kumar, 2018). In the present study, a few acini and a few secretory cells in some acini showed moderate positive reaction for Mayer's mucicarmine (Fig. 5), colloidal iron and Alcian blue (pH 2.5) (Fig. 6) indicating the presence of acidic mucopolysaccharides. Similar findings were reported earlier in bison and cattle (Pinard *et al.*,2003), Philippine water buffalo (Maala *et al.*, 2007) and in camel (Mohammadpour, 2011). However a strong PAS-positive reaction in mucous cells and weak PAS-positive reaction in seromucous cells was reported in sheep (Gargiulo *et al.*, 1999). In the present study, a few acini and a few secretory cells in some acini showed moderate positive reaction for Alcian blue (pH 2.5) indicating the presence of weakly acidic sulfated mucosubstances, sialomucins and hyaluronic acid as reported in ruminants (Triveni *et al.*, 2018) and sheep (Singh *et al.*, 2018).

The duct system was comprised of intralobular and interlobular ducts. The intra-glandular ducts were lined by simple cuboidal epithelium which was having uniform

distribution of eosinophilic cytoplasm. These ducts were also surrounded by myo-epithelial cells which were having narrow elongated nuclei with the tapering end. A few inter-glandular ducts were lined by simple cuboidal to stratified cuboidal epithelium as revealed in buffalo (Girgiri and Kumar, 2018), Lori sheep (Abbasi *et al.*, 2014) and small ruminants (Daryuos and Ahmed, 2012). Whereas, in Iranian river buffalo, interlobular ducts were lined by pseudostratified epithelium (Shadkhast and Bigham, 2010)

Goblet cells present in the inter-glandular ducts also showed positive reaction for acidic mucopolysaccharides as reported in ruminants (Triveni *et al.*, 2018) and sheep (Singh *et al.*, 2018). Goblet cells showed positive reaction for presence of glycogen mucous acini (Fig. 3). Colloidal iron also showed moderate positive reaction in the goblet cells indicated the presence of acid mucopolysaccharides (Fig. 6).

REFERENCES

Abbasi, M., Karimi, H. and Gharzi, A. (2014). Preliminary anatomical and histological study of lacrimal gland in Lori sheep. *J.Vet. Sci. Technol.* **5**:154.

Crossman, G.A. (1937). A modification of Mallory's connective tissue stain with a discussion of principles involved. *Anat. Rec.* **69**: 33-38.

Daryuos, M.M. and Ahmed, N.S. (2012). Comparative histological and morphometrical study of lacrimal apparatus of Awasi sheep and native black goat. *Kufa J. Vet. Sci.* **3**: 41-56.

Gargiulo, A.M., Coliolo, P., Ceccarelli, P. and Pedini, V. (1999). Ultrastructural study of sheep lacrimal glands. *Vet. Res.* **30**: 345-351.

Girgiri, I.A. and Kumar, P. (2018) Histological and histochemical studies on the lacrimal gland of buffaloes (*Bubalus bubalis*). *Sch. J. Agric. Vet. Sci.* **5**: 283-289.

Kuhnel, W. and Scheele G. (1979). Ultrastructure of the lacrimal gland in pigs. *Ann. Anat.* **145**: 87-106.

Luna, L.G. (1968). Manual of Histologic Staining methods of Armed Forces Institute of Pathology. (3rd Edn.), McGraw Hill Book Co., New York.

Maala, C.P., Cartagena, R.A. and De Ocampo D.G. (2007). Macroscopic, histological and histochemical characterization of the lacrimal gland of the Philippine water buffalo (*Bubalus bubalis*). *Philipp. J. Vet. Med.* **44**: 69-75.

Martin, C.L.J., Munnel, J.F. and Kaswan, R. (1988). Normal ultrastructure and histochemical characteristics of canine lacrimal glands. *Am. J. Vet. Res.* **49**: 1566-1572.

Mohammadpour, A.A. (2011). Histochemistry of dorsal lacrimal gland in camel (*Camelus dromedarius*). *J. Camel Pract. Res.* **18**:131-133.

Pinard, C.L., Weiss, M.L., Brightman, A.H., Fenwick, B.W. and Davidson, H.J. (2003). Normal anatomical and histochemical characteristics of the lacrimal glands in the American bison and cattle. *Anat. Histol. Embryol.* **32**: 257-262.

Shadkhast, M. and Bigham, A.S. (2010). A Histo-anatomical study of dorsal lacrimal gland in Iranian river buffalo. *Vet. Scan.* **5**: 1-5.

Singh, A., Kumar, P., Gahlot, P.K. and Parkash, T. (2018). Histomorphochemical characterization of the lacrimal gland of sheep (*Ovis aries*). *Indian J. Vet. Anat.* **30**: 131-133.

Triveni, T., Pawar, A., Girish, M.H. and Kumar, D. (2018). Comparative histochemical studies of lacrimal gland in ruminants. *Indian J. Anim. Res.* **55**: 1667-69.