Haryana Vet. (Dec., 2019) **58(2),** 266-269

Research Article

HISTOMORPHOLOGICAL AND HISTOCHEMICAL CHARACTERIZATION OF ATRESIA OF PREANTRAL FOLLICLES OF WATER BUFFALOES

ADHIRAAJ SINGH, DEVENDRA PATHAK*, OPINDER SINGH and NEELAM BANSAL
Department of Veterinary Anatomy, College of Veterinary Science,
Guru Angad Dev Veterinary and Animal Sciences University, Ludhiana-141 004, India

Received: 22.03.2019; Accepted: 30.04.2019

ABSTRACT

Present study was aimed at histomorphological and histochemical characterization of atresia of pre-antral follicles in ovaries of water buffaloes. The primordial and primary follicles underwent degenerative changes and the changes observed were shrinkage of the follicular wall and disruptions of the lining basal lamina. The atretic follicles showed oocyte nucleus to become eccentric and the basal lamina to become disrupted and shrinked. Secondary atretic follicle showed pyknosis of follicular cells and creation of spaces in between the follicular cells. The percentage of atretic cells was significantly higher in the summer (61%) and rainy seasons (55.77%) than in the winter (29.44%) and spring seasons (28.24%). A distinct PAS positive reaction was observed in the basal lamina of primordial and primary follicles. The reaction was visible as continuous basal lamina in healthy follicles and interrupted basal lamina was observed in the atretic follicles. Bromophenol blue positive reactions were observed in the cytoplasm of healthy primordial and primary follicle. In the atretic follicle, the cytoplasm of the oocyte was devoid of bromophenol blue positive proteins. In the secondary atretic follicle which was seen as collapsed structure, localization of protein was not distinguishable.

Keywords: Atresia, Buffalo, Histochemical, Histomorphological, Preantral Follicle

Water buffalo is reared for milk and meat production in Asian countries. In India, it contributes around 50 per cent of the total milk produced and thus plays prime role in Indian economy. Buffaloes exhibit seasonal variation in the reproductive efficiency and show higher reproductive efficiency during winter season in comparison to summer months due to environmental factors. Ovary is the primary dynamic organ of reproduction having dual function of gametogenesis and steroidogenesis. Folliculogenesis is a dynamic event which finally leads to ovulation or atresia. Process of ovarian follicular development and atresia is closely regulated by the interaction between cell death and cell survival signals. In mammals, the basic mechanism of follicular atresia is apoptosis (Depalo *et al.*, 2003). An increased rate of follicular atresia has been implicated as one of the major factors for reproductive failure in buffalo (Rajesha *et al.*, 2001). The aim of this study was the histological and histochemical characterization of the atretic process of preantral follicles in buffalo ovary.

MATERIALS AND METHODS

The ovaries of buffaloes (n =48) were collected from M K Overseas, Dera Basi, local abattoir at Bareilly and Teaching Veterinary Clinical Complex, GADVASU, Ludhiana and were utilized for the histomorphological and histochemical studies. The samples were fixed in 10% neutral buffered formalin and processed for paraffin sectioning by dehydrating in ascending grades of alcohols and acetone and were cleared in benzene and infiltrated and embedded in paraffin (Pathak and Bansal, 2012). Sections were cut at 4-5 µm thickness for histological study and were subjected to different stains *viz.*, Haematoxylin and Eosin for Morphological studies, Masson's trichrome for Collagen fibers (Luna, 1968) and Gridley's for Reticular fibers (Sheehan and Hrapchak, 1973).

*Correspondence author: drdevendra@gmail.com

Picrosirius Red Staining for Collagen fibres: Paraffin sections were stained with Picrosirius red (PSR) stain for collagen fiber. The sections were observed in light microscope and fluorescent microscope [in Tetramethylrhodamine (TRITC) filter]. PSR stained collagen appears red in light microscopy and showed a red fluorescence in TRITC filter.

Histochemical Studies: Histochemical demonstration of carbohydrates (neutral mucopolysaccharides) and basic proteins was carried out on the paraffin sections using Per iodic acid Schiff (PAS) (Sheehan and Hrapchak, 1973) and Bromphenol blue (Chayen *et al.*, 1969) stains, respectively.

RESULTS AND DISCUSSION

Histomorphology: Histological picture of ovary at different reproductive stages revealed healthy as well as degenerative follicles. Follicular atresia was a degenerative process by which the follicles lost their healthy morphology. In the present study, atretic follicles were observed in all the types of follicles from primordial to the tertiary follicles. Clear histological and histochemical changes were observed in different components of the preantral follicles during atresia. Greenwald and Terranova (1988) described that the follicular atresia occurred both during prepubertal and pubertal life of mammalian females and reported that follicles might become atretic at any stage of its growth and development.

The primordial and primary follicles underwent degenerative changes. The changes observed were shrinkage of the follicular wall and disruptions of the

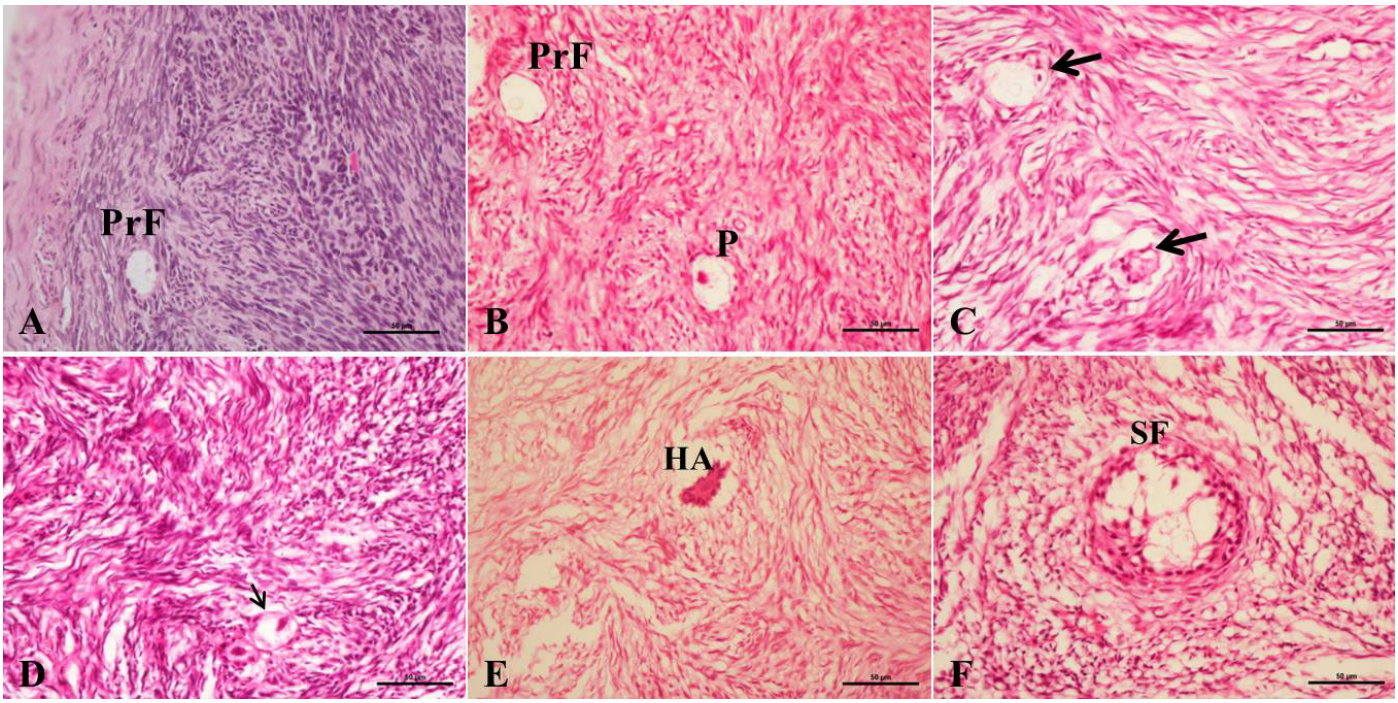

Fig. 1. Paraffin section of Buffalo ovary showing; **A.** Healthy primordial follicle (PrF). **B.** Healthy primordial follicles (PrF) and primary follicle (P). **C.** Two atretic primary follicles became atretic (arrows). **D.** Atretic follicles (Arrow) at the initial stages of atresia. **E.** Preantral follicle undergone through hyalinization and atresia (HA). **F.** Secondary follicle (SF) which became atretic. Haematoxylin & Eosin × 400.

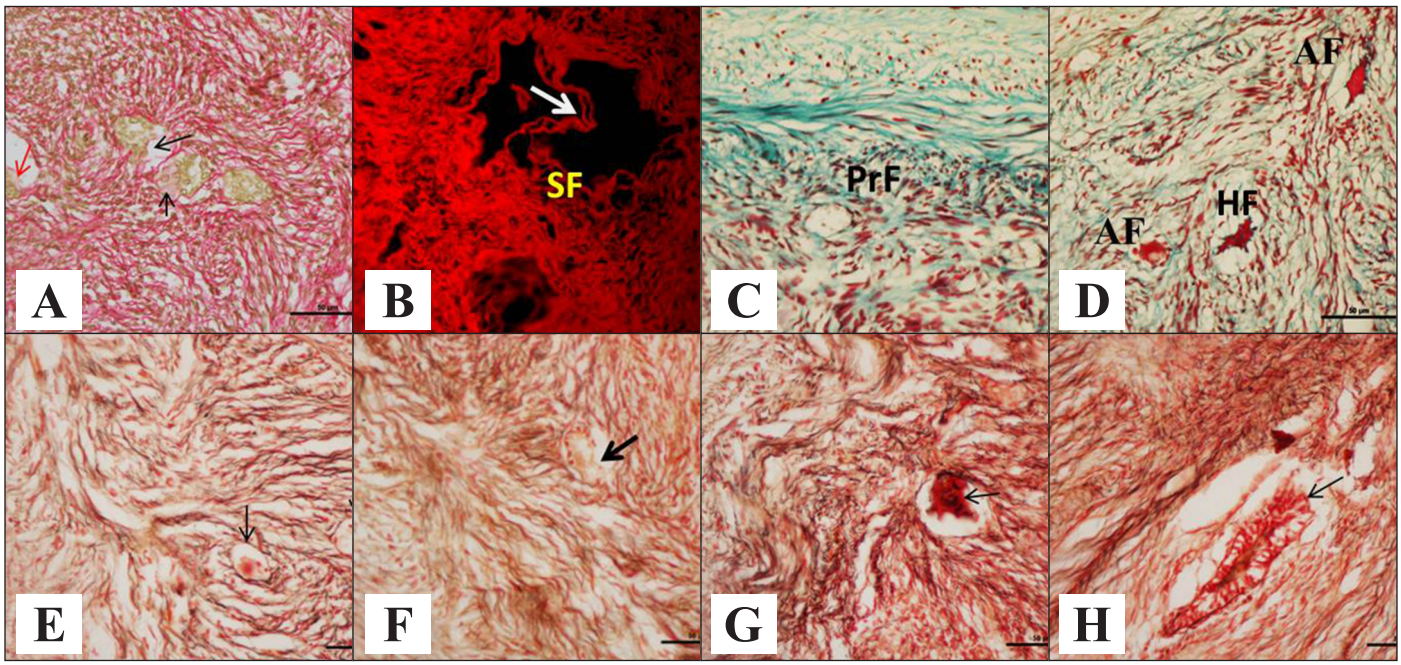

Fig. 2. Paraffin section of Buffalo ovary (×400) showing; **A.** Atretic primary and secondary follicles (arrows). Picrosirius red stain, **B.** Atretic secondary follicles (SF) with collapsed basal lamina (arrow) with fluorescence microscope. Picrosirius red stain, **C.** Healthy primordial follicle (PrF) with no atresia. Masson's trichrome stain, **D.** Atretic follicles (AF) with preantral atresia showing hyalinised follicle (HF). Masson's trichrome stain, **E.** Normal healthy primary follicle (arrows). Gridley's reticular stain, **F.** Atretic primary follicle (arrow). Gridley's reticular stain. **G.** Collapsed follicle (arrow) with intermediate atresia. Gridley's reticular stain. **H.** Atresia with collapse of the basement membrane (arrow) in the secondary follicle. Gridley's reticular stain.

lining basal lamina, while morphologically healthy primordial and primary follicles revealed intact basal lamina, round or oval oocyte, presented a well-delimited nucleus with uncondensed euchromatin, surrounded by healthy granulosa cells (Fig. 1A and 1B). Guraya (1985) described the main characteristic features of atretic primordial follicles to be shrinkage and crinkled appearance of the nuclear envelope. Changes observed in the present study with regards to atresia of primordial and primary follicles were more distinct in the cytoplasm of the

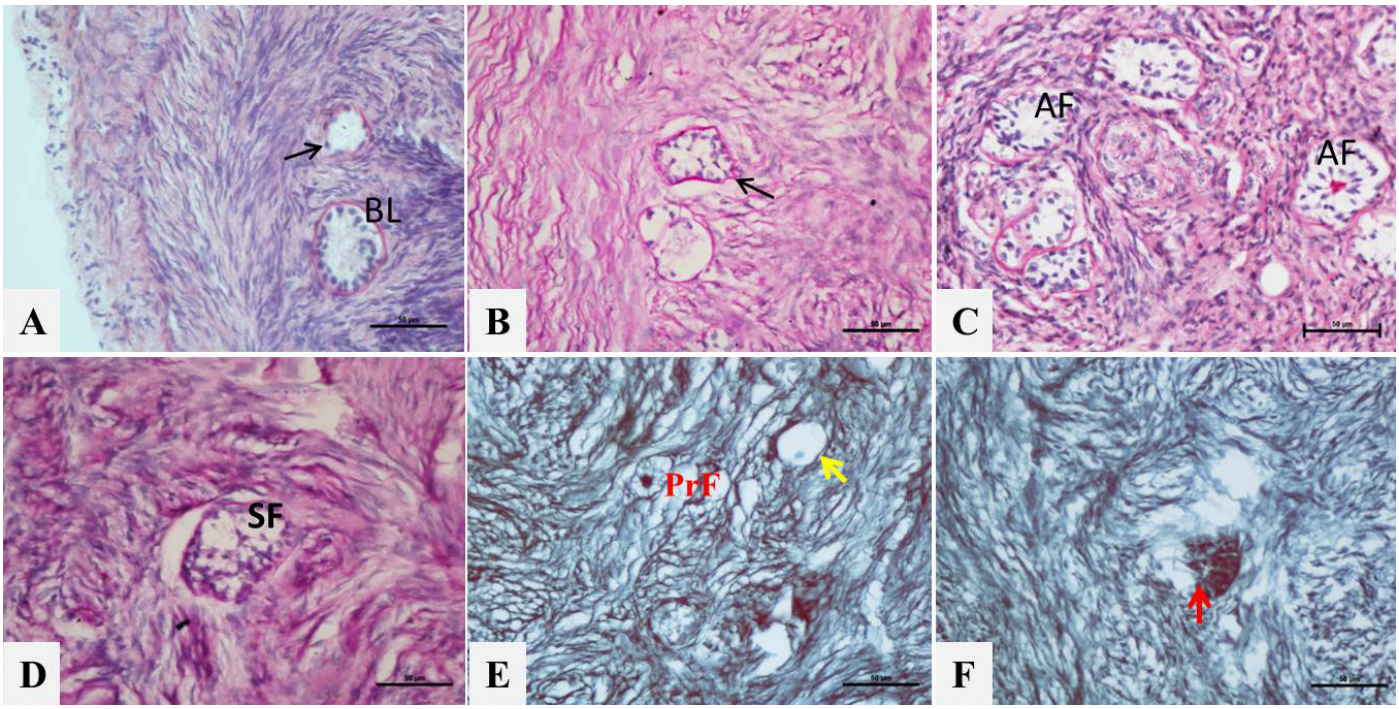

Fig. 3. Paraffin section of Buffalo ovary (×400) showing; **A.** Atretic primordial follicle with discontinuity in the basal lamina (arrow) and normal healthy secondary follicle with continuity in the basal lamina (BL). PAS, **B.** Atretic primary and secondary follicle with discontinuity in the basal lamina (arrow). PAS, **C.** Atretic primordial, primary and secondary follicles (AF) with discontinuity in the basal lamina, PAS, **D.** Atretic secondary (SF) follicle. PAS, **E.** Normal healthy primordial follicle (PrF) and one chromatolysed follicle (arrow). Bromophenol blue, **F.** Atretic secondary follicle (arrow) with protein reaction. Bromophenol blue.

oocyte as compared to the follicular cells. In contrast, Guraya *et al.* (1994) observed that in small preantral follicles, atresia occurred both in oocyte and granulosa in sheep and goat ovaries, simultaneously.

Changes in the basal lamina were also distinct. The atretic follicles showed that oocyte nucleus became eccentric and the basal lamina became disrupted and shrinked (Fig. 1C). In some follicles, atretic changes in the nucleus of oocyte as well as atretic changes in the follicular cells were observed together (Fig. 1D). Cran *et al.* (1983), in sheep and pig ovaries, reported atresia in small preantral follicles and observed that the atretic changes occurred simultaneously both in the oocyte and granulosa. Some of the atretic follicles showed chromatolysis of the ooplasm, nucleus and the follicular cells while the other atretic follicles revealed the hyalinization of the ooplasm and follicular cells (Fig. 1E).

Secondary atretic follicle showed pyknosis of follicular cells and creation of spaces in between the follicular cells (Fig. 1F). The spaces might be formed due to degeneration of the follicular cells. The vacuolization and lipid droplets distribution is a sign of degeneration and shrinkage of oocyte after vitrifying/ thawing of ovarian tissue (Oktay *et al.*, 1997). In goat ovary, this loosening is confined only to one region of the follicle, whereas in sheep ovary, it occurs in entire granulosa. Spaces are developed between the granulosa and theca layers, possibly due to shrinkage of granulosa. These changes increased with the advancement of atresia (Guraya *et al.*, 1994).

The ovaries stained with PSR revealed that the basal lamina was continuous in apparently healthy primordial and primary follicles (Fig. 2A). The atretic follicles had basal lamina surrounding follicular cells that showed breakage at places (Fig. 2B). It can be concluded that the integrity of the basal lamina could be the most important factor in the maintenance of healthy follicles or it might be a primary sign of degeneration of these follicles. The extracellular matrix (ECM) provided structural support to the follicle and maintained cellular organization and connectivity and provided biochemical signals that promoted follicle development and maturation (Rodgers *et al.*, 2003).

Table 1
Percentage of atretic cells in primordial and primary follicles in different seasons (Mean ± S.E.)

Season/ Follicle	Winter	Spring	Summer	Rainy
Primordial	29.44±2.98	28.44±3.15	61.00±4.01	55.77±2.42
Primary	26.24±4.42	29.21±3.12	58.22±4.23	51.22±2.92

In Masson's trichrome stain sections of ovary, healthy pre-antral follicles were seen as round or oval follicles with distinct basal lamina stained with light green while, the ooplasm stained lightly (Fig. 2C). The atretic

primary and primordial follicles were seen as shrinked structure with disrupted basal lamina and hyalinized darkly red stained acidophilic cytoplasm (Fig. 2D).

The healthy preantral follicles were surrounded by the basal lamina consisted of reticular fibres as was revealed by the Gridley's stain. There was a thin layer of reticular fibres around the follicular cells of the healthy primordial and primary follicles. The atretic follicles showed disrupted layer of reticular fibers (Fig. 3E). The ooplasm was darkly stained and hyalinized (Fig. 3F). Degeneration of the follicular cells appears as chromatolysis, chromatorhexis, fatty, and hyaline degeneration of the ooplasm (Hsu and Hsueh, 2000). In the atretic secondary follicles also, disrupted reticular fibers were seen (Figs. 3G and 3H). Thus, it can be hypothesized that the disruption in the basal lamina could be an indicator of degenerative changes and it might finally lead to the atresia.

The seasonal variation in the percentage of atretic cells was observed (Table 1). The percentage of atretic cells was significantly higher in the summer (61%) and rainy seasons (55.77%) than in the winter (29.44%) and spring seasons (28.24%). The rate of atresia reported in primordial and primary follicles varies in the ovaries of different species and strains of mammals (Peters and McNatty, 1980).

The percentage of atretic cells in primary follicles was also was significantly higher in summer (58.22%) and rainy seasons (51.22%) than in the winter (26.24%) and spring seasons (29.21%). The rate of atresia reported in primordial and primary follicles varies in the ovaries of different species and strains of mammals (Guraya, 1985).

Histochemistry: A distinct PAS positive reaction was observed in the basal lamina of primordial and primary follicles. The reaction was visible as continuous basal lamina in healthy follicles and interrupted basal lamina was observed in the atretic follicles (Fig. 3A). In the winter season, healthy follicles with intact basal lamina in the form of distinct PAS positive reaction were observed in primordial and primary follicles. During summer season, groups of atretic follicles were observed which showed disruption in the basal lamina. In some of the primary follicles, there was distinct sign of atresia as follicular cells detached from periphery and loosely present in the central part of follicle (Fig. 3B). Similar patterns were observed in growing secondary follicle. In some atretic follicles, the basal lamina became hyalinised (Fig. 3C and 3D). Secondary atretic follicle showed continuous but folded basal lamina as revealed by PAS positive reaction. The thickness of basal lamina also increased and looked sheet-like in contrast to the sharp line. In the summer season, the secondary follicles showed hyalinization of spreading of basal lamina. Similar to our findings, PAS reactions have been reported in growing follicles in adult mice ovaries by Tadano and Yamada (1978).

Bromophenol blue positive reactions were observed in the cytoplasm of healthy primordial and primary follicle (Fig. 3E). In the atretic follicle, the cytoplasm of the oocyte was devoid of bromophenol blue positive proteins. In the secondary atretic follicle, seen as collapsed structure, the protein localisation was not distinguishable (Fig. 3F).

Thus, it could be concluded the protein is required for integrity of the healthy follicles and disruption of the same might lead to atresia.

REFERENCES

Chayen, J., Bitensky, L., Butcher, R.G. and Poulter, L.W. (1969). A guide to practical histochemistry. (1st Edn.), Oliver and Boyd, Edinburgh, England.

Cran, D.G, Osborn, J.C. and Rushton, D. (1983). Thecal vasculature and oocyte maturation during follicular atresia in the sheep and pig. *Reprod. Nutr. Dev.* **23(2A)**: 285-292.

Depalo, R., Nappi, L., Loverro, G., Bettocchi, S., Bettocchi, S., Caruso, M.L., Valentini, A.M. and Selvaggi, L. (2003). Evidence of apoptosis in human primordial and primary follicles. *Hum. Reprod.* **18(12)**: 2678-2682.

Greenwald, G.S. and Terranova, P.F. (1988). Follicular selection and its control. In: The Physiology of Reproduction. (1st Edn.), Knobil, E. and Neil, J.D. Raven Press, New York.

Guraya, S.S. (1985). Biology of ovarian follicles in mammals. (1st Edn.), Springer-Verlag, New York.

Guraya, S.S., Monga, S., Kaur, P. and Sangha, G.K. (1994). Comparative morphological and histochemical studies on the follicular atresia in the goat and sheep ovary. *Indian J. Anim. Sci.* **64**: 331-336.

Hsu, S.Y. and Hsueh, A.J. (2000). Tissue-specific Bcl-2 protein partners in apoptosis: an ovarian paradigm. *Physiol. Rev.* **80(2)**: 593-614.

Luna, L.G. (1968). Manual of histological staining methods of armed forces Institute of Pathology. (3rd Edn.), McGraw Hill Book Company, New York, USA.

Oktay, K., Nugent, D., Newton, H., Salha, O., Chatterjee, P. and Gosden, R.G. (1997). Isolation and characterization of primordial follicles from fresh and cryopreserved human ovarian tissue. *Fertil. Steril.* **67(3)**: 481-486.

Pathak, D. and Bansal, N. (2012). Histomorphology of the endometrial gland of Buffalo. *Indian Vet. J.* **89(9)**: 25-28.

Peters, H. and McNatty, K.P. (1980). The ovary: A correlation of structure and function in mammals. (1st Edn.), Univsity of California Press, California.

Rajesha, D., Ravindra, J.P. and Narayanaswamy, M. (2001). Ovarian antral follicular activity and serum estradiol-17β concentrations in buffaloes during different periods of the year. *Indian J. Anim. Sci.* **71**: 641-643.

Rodgers, R.J., Irving-Rodgers, H.F. and Russell, D.L. (2003). Extracellular matrix of the developing ovarian follicle. *Reproduction.* **126(4)**: 415-424.

Sheehan, D.C. and Hrapchak, B.B. (1973). Theory and practice of histotechnology. (1st Edn.), The CV Mosby Company, St Louis.

Tadano, Y. and Yamada, K. (1978). The histochemistry of complex carbohydrates in the ovarian follicles of adult mice. *Histochemistry.* **57(3)**: 203-215.