Haryana Vet. (June, 2019) **58(1),** 93-96

Research Article

EFFICACY OF ELECTROCHEMOTHERAPY FOR MANAGEMENT OF SUPERFICIAL MALIGNANT TUMOURS IN DOG

A.S. NEWARE, S.B. AKHARE*, P.T. JADHAO, S.V. UPADHYE, M.V. KAMBLE and N.V. KURKURE
Department of Surgery & Radiology, Nagpur Veterinary College, Nagpur-440006, India

Received: 23.08.2018; Accepted: 17.10.2018

ABSTRACT

Present study includes clinical cases of dogs with malignant superficial tumour irrespective of age, sex and breed. The dogs were divided in three equal groups and were subjected to three different treatment regimens. The dogs in group I and II were treated with doxorubicin hydrochloride @ 30 mg/m^2 by slow i.v. route along with 5% dextrose saline. Additionally, in group I, direct electric current of 8-12 V and 80-180 mA was passed into the tumour at different places for 30 minutes depending upon the size of the tumour. In group III, dogs were subjected to the radical surgery for excision of the tumour. The age, sex and breed wise prevalence, haemato-biochemical parameters, radiographical examination, histopathological examination and regression of tumour was studied. During the study, the haemato-biochemical parameters did not alter significantly. The systemic toxic symptoms like vomiting, diarrhoea, anorexia, alopecia and body weight loss were recorded in intravenous chemotherapy in all dogs. The reduction in mitotic figures and vessels and increased necrotic cells indicates favorable results of electrochemotherapy. Considering the regression, side effects and recurrence, it was observed that electrochemotherapy with doxorubicin proved to be superior therapy than chemotherapy alone. Surgical excision of tumours may result in recurrence. Electrochemotherapy had additive effect on immune response resulting in higher regression of the tumour as compared to chemotherapy which subsequently helped in improved quality of life of patient.

Key words: Dog, Electrochemotherapy, Malignant, Tumour

Canine cancer is a leading cause of morbidity and mortality among companion animals especially over the age of 10 years. Classical modalities for cancer therapy include surgery, radiation and chemotherapy. Cryosurgery, immunotherapy, hyperthermia and use of biological response modifiers have also been reported to be effective. However, the current focus in the development of cancer therapies is by providing the therapeutic concentrations of anticancer agents at the site of action and sparing the normal tissues (Sersa, 2006).

Electrochemotherapy (ECT) may be used as alternative/ adjuvant therapy to treat superficial tumour in humans and pets. This treatment option involves the use of small doses of systemic or intralesional chemotherapy followed by direct electric current applied to the tumour. The efficacy of adjuvant ECT for the local control of incompletely excised soft tissue sarcoma was assessed in a spontaneous canine model of sarcoma (Spugnini *et al.*, 2007). ECT is also safe and effective therapy for incompletely excised superficial tumours in companion animals. Its ease of administration, lack of toxicities and low cost makes it an attractive alternative to standard treatments and warrants further investigations (Spugnini *et al.*, 2006). The advantages of ECT are its simplicity, short duration of treatment sessions, low chemotherapeutic doses, and insignificant side effects, as well as the fact that it can be performed on outpatient basis (Sersa *et al.*, 2005). The present study was conducted to assess the efficacy of ECT by using Doxorubicin as a chemotherapeutic agent for superficial malignant tumours in dog.

Corresponding author:sandeepakhare@yahoo.co.in

MATERIALS AND METHODS

The present study was undertaken on eighteen clinical cases of superficial malignant tumours divided into 3 groups. The data on age, breed, sex, duration of illness, location, size of tumour and visual examination of lesion was recorded and reported in the study.

In group I, dogs with the tumour size less than 3 cm were subjected to the ECT; whereas, group II dogs with smaller tumour size were subjected to the chemotherapy and in group III, dogs with the tumour size more than 3 cm were subjected to radical surgery. All dogs were subjected to detailed general, clinical, haematological and serum biochemical examination. In group I, ECT with intravenous administration of Doxorubicin @ 30 mg/m^2 was given. In group II, Doxorubicin @ 30 mg/m^2 was administered intravenously and group III dogs were subjected to radical surgery for excision of tumour. The staging of tumour was done as per the system developed by the World Health Organization (Cullen *et al.*, 2014).

The electrochemotherapy was given by using direct electric current in the range of 8 - 12 V and 80-180 mA depending upon the size of tumour after 15 minutes of administration of Doxorubicin. The radical surgery was performed by following standard operative procedure under dissociative anaesthesia.

The clinical examination was carried out in all the dogs before start of the treatment. The data on location and size of tumour, visual examination of lesion, haemato-biochemical parameters, recurrence/metastasis and histomorphological examination at scheduled interval and

regression of growth was studied in all the dogs. The complications, if any were recorded during the study. The data was statistically analysed by using Two-way Factorial Completely Randomized Design (Snedecor and Cochran,1994).

RESULTS AND DISCUSSION

The prevalence of total cases of tumours during the study indicated that skin and soft tissue tumours accounted for 27.96 per cent. The age of dogs ranged from 8 months to 15 years. Dogs above 8 year of age were mostly affected with the mean average age of 9.5 years. The present observations are in accordance with the findings of Hire (2016), Kumar *et. al.* (2017) and Arya *et. al.* (2018). The highest incidence was observed in non-descript dogs (Table 1). The incidence was more in males. The skin over the tumour was found ulcerated in 66.66 percent cases, showed no tendency to heal, which might be due to the change in the condition of the skin over the tumour mass. Similar findings were also reported by Goldberg *et al.* (2001) and Hire (2016). The higher percent of the tumour was observed on anal/perianal region (33.33%) followed by thoracic region and caudal/ventral abdomen (22.22%), head region (11.11%), limb and cranial abdominal region (5.55%). The tumours with less than 3 cm size were observed more as compare to 3 to 8 cm (5.55%) or less than 3 cm (33.33%) (Table 1 & Fig. 1-12).

The haemato-biochemical studies conducted at scheduled intervals of day 0, 7, 14 and 21 indicated no significant changes in any of the haemato-biochemical parameters in any of the group when compared within the groups. However; significant changes were recorded in total erythrocyte count, total leucocyte count, neutrophil count and lymphocyte count when compared in between the groups. The increased haemoglobin value may be due to the systemic immunity induced in the body by electrochemotherapy as demonstrated by Li (2011), Jing-Hong and Yu Ling (2013) and Lowe *et al.* (2016). The decrease in total erythrocyte count in group II could be attributed to chemotherapy induced erythrocytopenia due to myelosuppression. Similar findings were reported by Ingle (2014) and Hire (2016) after chemotherapy in dog.

Radiography on day 0 and 21 revealed no metastasis in any of the dog during the study. The recurrence was not observed in group I and II; except in one case, wherein it was noted in one case in group III. In group I and II, wherein doxorubicin was administered, symptoms of vomiting, diarrhoea, anorexia, alopecia and body weight loss were observed in all dogs.

The electrochemotherapy resulted in drastic changes in the histopathological features. The biopsies taken on 21st day indicated reduction in mitotic figures and vessels and increased necrotic cells indicating favorable results of chemotherapy. The changes were less pronounced in dogs treated with chemotherapy (Fig. 13-16). Various tumours recorded were adenocarcinoma (6), fibrosarcoma (6), squamous cell carcinoma (2) and one each of cystic adenocarcinoma, schirruminous adenocarcinoma, tibulopapilary carcinoma and chondro-fibrosarcoma.

Table 1
Distribution of dogs with superficial tumours during the study

	History	Number	Per cent
Age	Up to 8 years	4	22.22
	8 and above	14	77.77
Breed	Non-descript	5	27.77
	Dachshund	3	16.66
	Pomeranian	2	11.11
	Boxer	2	11.11
	German shepherd	2	11.11
	Dalmatian	1	5.55
	Pug	1	5.55
	Spitz	1	5.55
	Labrador	1	5.55
Sex	Male	13	72.22
	Female	5	27.77
Duration of illness	Up to 3 months	3	16.66
	3 to 6 months	6	33.33
	6 months and above	9	50.00
Location	Head region	2	11.11
	Limbs	1	5.55
	Thoracic region	4	22.22
	Cranial/ventral abdominal region region	1	5.55
	Caudal/ ventral abdominal region	4	22.22
	Anal/perianal region	6	33.33
Size	Below 3 cm	11	61.11
	3 to 8 cm	1	5.55
	More than 8 cm	6	33.33
Visual examination of lesion	Ulcerative	12	66.66
	Non-ulcerative	6	33.33

Thus, considering the regression, side effects and recurrence, it was observed that electrochemotherapy with intravenous administration of doxorubicin proved to be superior therapy than chemotherapy alone (Table 2). Surgical excision of tumours may result in recurrence. Electrochemotherapy had additive effect on immune response resulting in higher regression of the tumour as compared to chemotherapy which subsequently helped in improved quality of life of patient.

REFERENCES

Arya, S.K. D., Kumar, K., Kumar, D., Kumar, S., Tiwary, R., Sinha, R., Kumar, A., Yadav, S., Armanullah, M., Kumar, A., Kumar, H. and Kumar, R.R. (2018). Incidence of Commonly Occurring

Different locations of the tumour

Fig.1. Forehead; 2. Lateral aspect of cheek; 3. Forelimb-lateral aspect of elbow; 4. Hindlimb- posterior to hock; 5. Lateral thoracic wall; 6. Lateral thoracic wall; 7. Cranio-ventral abdomen; 8. Cranio-ventrolateral abdomen; 9. Caudo-ventral abdomen region; 10. Caudo-lateral abdomen region; 11. Tip of Tail; 12. Perianal region

Effect of electrochemotherapy on histopathological appearance (Group I)

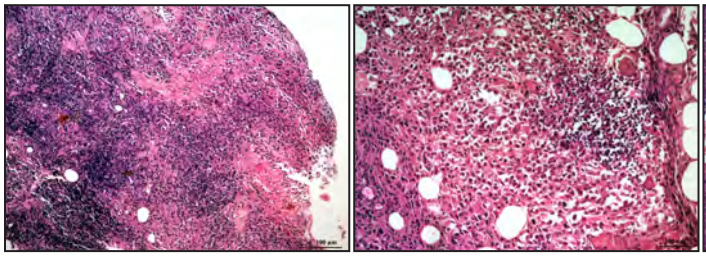

Fig. 13. Fibrosarcoma before treatment with inflammatory & necrotic cells. (H & E, 4X); 14. Fibrosarcoma 21 days after treatment reveals reduced necrotic cells & regeneration of healthy cells. (H & E, 10X)

Effect of chemotherapy on histopathological appearance (Group II)

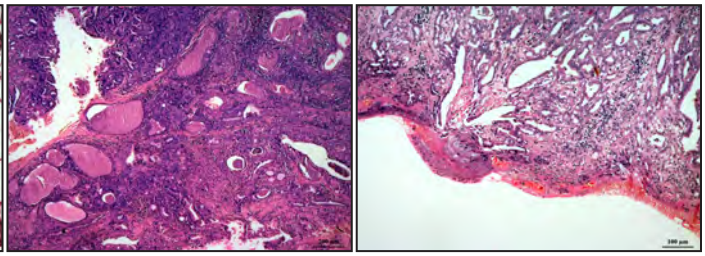

Fig. 15. Schiruminousadenocarcinoma before treatment with schirruminous exudates & necrotic cells. (H&E,10X); 16. Schiruminous adenocarcinoma 21 days after treatment reveals formation of blood vessels. (H&E, 10X)

Table 2
Regression of Growth / Response to Treatment

Animal No.	Group I			Group II			Group III
	Regression	Response as per WHO guidelines	Symptoms associated with toxicity	Regression	Response as per WHO guidelines	Symptoms associated with toxicity	Recur-rence/ Metas-tasis
1.	+++	CR	V	+++	CR	AL	-
2.	+++	CR	A	+++	CR	V	-
3.	+++	CR	A	+	NC	WL	-
4.	+++	CR	A	+	NC	A	-
5.	+++	CR	D	++	PR	F	-
6.	++	PR	A	++	PR	F	-

- - No regression/Progressive Disease (PD) - Tumour vol. enlarged more than 25%; + - Minimum regression/No Change (NC) - Tumour vol. reduction less than 50%
++ - Moderate regression/Partial Response (PR) -Tumour vol. reduction more than 50%; +++ - Complete regression/Complete Response (CR) - Absence of any trace of tumour
Objective Response (OR) = (CR) + (PR); V - Vomition; F – Fever; D – Diarrohea; WL – Weight lost; A – Anorexia; AL – Alopecia

Neoplasms amongst Canines in Patna. *Int. J. Curr. Microbiol. App. Sci.* **7**: 2817-2823.

Cullen, J. M., Page, R. and Misdrop, W. (2014). An overview of cancer pathogenesis, Diagnosis and Management. In: Textbook of Tumours in Domestic Animals. Meuten, D.J. (edt). 4th edn., Iowa State Press, Ames, Iowa, USA. pp: 35-36.

Goldberg, S.N., Saldinger, P.F., Gazelle, G.S., Huertas, J.C., Stuart, K.E., Jacobs, T. and Kruskal, J. B. (2001). Percutaneous tumor ablation: increased necrosis with combined radio-frequency ablation and intratumoral doxorubicin injection in a rat breast tumor model. *Radiol.* **220**: 420-427.

Hire, S. A. (2016). Studies on adjunct chemotherapeutic conbination for treatment of cutaneous tumours in dog. M.V.Sc. thesis submitted to Maharashtra Animal and Fishery Sciences University, Nagpur, Maharashtra, India.

Ingle, R.S. (2014). Studies on efficacy of nanoparticulate induced drug delivery system for chemotherapy of superficial tumors in dog. M.V.Sc. thesis submitted to Maharashtra Animal and Fishery Sciences University, Nagpur, Maharashtra, India.

Jing-Hong and Ling, Yu. (2013). Electrochemical Therapy of Tumors Conference Papers in Medicine Volume, Article ID 858319, 13 pages http://dx.doi.org/ 10.1155/ 2013/ 858319.

Kodre, V., Cemaza, M., Pecar, J., Sersa, G., Cor, A. and Tozon, N. (2009). Electrochemotherapy compared to surgery for treatment of canine mast cell tumours. *In vivo.* **23**: 155-162.

Kumar, V.A., Kumari, K.N., Kumar, K.S., Kumar,V.G. and Lakshman, M. (2017). Incidence of certain tumors in dogs. *The Pharma Innovation J.* **6**: 137-141.

Li Jing-Hong (2011). Electrochemical Therapy of Tumours. *Oncothermia J.* **3**: 12-33.

Lowe, R., Gavazza, A., Impellizeri, J. A., Soden, D. M. and Lubas, G. (2016). The treatment of canine mast cell tumours with electrochemotherapy with or without surgical excision. *Vet. Comp. Oncol.* **15(3)**: 775-784.

Sersa, G. (2006). The state of the art of electrochemo therapy before the ESOPE study; advantages and clinical uses. *EJC supplements* **4**: 52-59.

Sersa, G., Tozon, N., Kodre, V. and Cemazar, M. (2005). Effective treatment of perianal tumors in dogs by electrochemo therapy. *Proc Amer. Assoc. Cancer Res.* **46**: 1417-1503.

Snedecor, G.W. and Cochran, W.G. (1994). Statistical Methods. (8th edn.), East West Press Pvt. Ltd., New Delhi.

Spugnini, E.P., Vincenzi, B., Baldi, F., Citro, G. and Baldi, A. (2006). Adjuvant electrochemo therapy for the treatment of incompletely resected canine mast cell tumors. *Anticancer Res.* **26**: 4585-4590.

Spugnini, E. P., Vincenzi, B., Citro, G., Santini, D., Dotsinsky, I., Mudrow, N., Montesarchio, V., Teresa, L.M., Esposito, V. and Baldi, A. (2007). Adjuvant electrochemo therapy for the treatment of incompletely excised spontaneous canine sarcomas. *In vivo.* **21**: 819-822.