Haryana Vet. (June, 2019) **58(1),** 101-103

Research Article

SCANNING ELECTRON MICROSCOPIC STUDIES ON THE NASAL CAVITY OF PIGS (*SUS SCROFA*)

TEJ PARKASH*, PAWAN KUMAR and GURDIAL SINGH
Department of Veterinary Anatomy, College of Veterinary Sciences
Lala Lajpat Rai University of Veterinary and Animal Sciences, Hisar-125004, India

Received: 15.10.2018; Accepted: 06.02.2019

ABSTRACT

Surface characteristics of the nasal epithelium were studied in six young pigs by the scanning electron microscope. Samples were taken from various parts of nasal cavity and prepared for scanning electron microscopic study in a routine manner. The nasal cavity presented five regions under electron microscope. The vestibular region presented flat leaf like cells having microplicae system. The transitional zone-I represented a transition from vestibular to respiratory region. The respiratory region had ciliated, goblet and microvillous cells. The transitional zone-II separated the respiratory and olfactory portions. The olfactory region had olfactory dendrites and olfactory vesicles.

Key words: Nasal cavity, Pig, Scanning electron microscopy

The nasal cavity has been described as an efficient "scrubbing tower" that removes inhaled chemicals potentially harmful to the lower respiratory airways. The nasal cavity plays an important role in preparation of the inspired air, olfaction, phonation, thermoregulation of body and removal of foreign dust particles (Mygind, 1978). The anatomy of the nasal cavity will be helpful to understand the mechanism of thermoregulation of air during the process of respiration. Microvilli present on cells of the nasal cavity are important as they increase the surface area available for absorption and metabolism of obnoxious substances, while the mucous production helps to trap particulate matter and humidify the inhaled air. The scanning electron microscopy of nasal cavity has been studied in goat (Kahwa and Balemba, 1998; Kumar *et al.*, 1999), horse (Kumar *et al.*, 2000), sheep (Ganganaik *et al.*, 2007) and buffalo (Kumar *et al.*, 2008). Although the histological and anatomical structure of the nasal cavity in Bama minipigs (Yang *et al.*, 2017) have been documented however scanning electron microscopic studies on the nasal cavity of pigs are meagrely available. So the present study was planned in pig to elucidate the surface appearance of different regions of the nasal cavity.

MATERIALS AND METHODS

Six young pig heads of local mixed breed of either sex were procured from local slaughter house immediately after slaughter. The mid sagittal sections of the heads were cut to collect the tissues from various parts of nasal cavity. The tissues were fixed in 2% glutaraldehyde solution for 6-8 hours after thorough washing in chilled 0.1M phosphate buffer (pH 7.4). The tissues were again washed twice with 0.1M phosphate buffer and rest of the procedure was carried out at EM Lab., AIRF, JNU, New Delhi. The tissues after sputter coated with gold were viewed under scanning electron microscope.

*Corresponding author: yadavdrtp@gmail.com

RESULTS AND DISCUSSION

The nasal cavity of pig was divided into five regions depending upon distribution of different types of cells under scanning electron microscope. The regions were rostro-caudally delineated as the vestibular, transitional-I, respiratory, transitional-II and olfactory zones.

The rostral most vestibular region in pig was localized towards straight and alar folds of dorsal and ventral nasal turbinates, respectively. This region was having the polygonal shaped cells of varying size and these were generally strongly convex in shape and appeared protruding from the surface (Fig. 1). At higher magnification, these cells presented the microvilli of very small size as reported earlier in dog (Majid, 1986), bonnet monkey (Harkema *et al.*, 1987), horse (Kumar *et al.*, 2000), buffalo calves (Kumar *et al.*, 2008) and camel (Gewaily, 2009; Abdel-Salam *et al.*, 2014). However the vestibular region presented flat leaf like cells, which were continuous with each other and higher magnification of these cells presented microplicae systemin goat (Kahwa and Balemba, 1998; Kumar *et al.*, 1999) and sheep (Ganganaik *et al.*, 2007).

The transitional zone-I was observed as moved rostro-caudally from vestibular region towards the respiratory region (Figs. 2, 3). This region presented the densely packed cells of varying shapes. These cells also presented microvilli of the small size. In between these microvillous cells, a few ciliated cells and a few cells having large sized microvilli started appearing as reported earlier in bovine (Adam, 1986), dog (Majid, 1986), horse (Kumar *et al.*, 2000), sheep (Ganganaik *et al.*, 2007) and buffalo calves (Kumar *et al.*, 2008) whereas, transition zone was characterised by squamous cells in goat (Kumar *et al.*, 1999).

The respiratory zone was largest zone occupying the majority of the portion of the nasal cavity. It was localized

Scanning electron micrographs

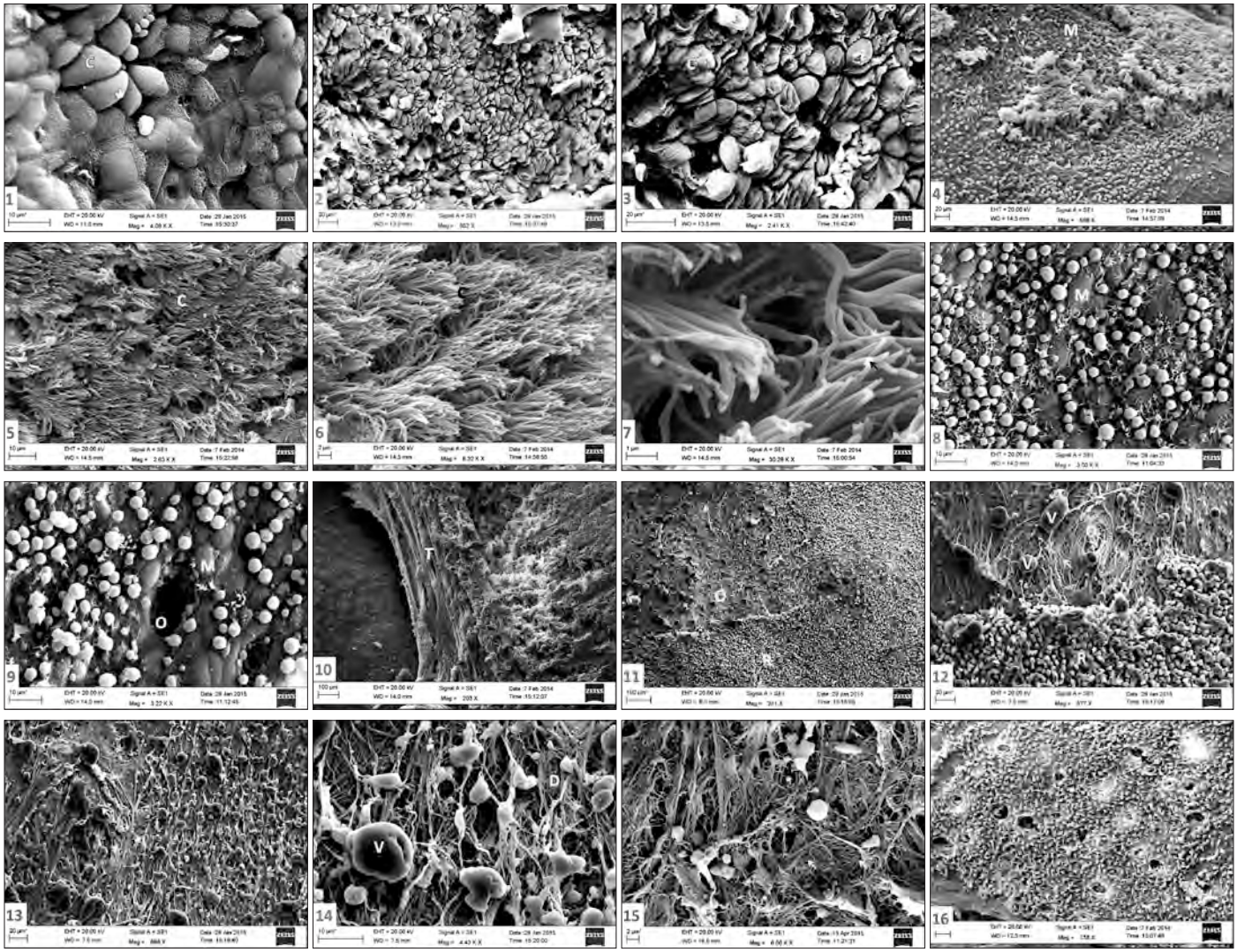



Fig.1. Polygonal shaped cells (C) in the vestibular region. × 4080; 2. Polygonal shaped and small size microvillous cells in the transition-I region. × 952; 3. Polygonal shaped (C)and small size microvillous cells (↑) in the transition-I region. × 2410; 4. Microvillous cells (M) and cilia (C) of respiratory region. × 698; 5. Tufts of cilia (C) of respiratory region. × 2630; 6. Dense carpet of cilia (C) of respiratory region. × 6320; 7. Tip of cilia showing blebs like (↑) arrangement in respiratory region. × 30280; 8. Respiratory epithelium showing the goblet(↑) and microvillous cells (M) in respiratory region where ciliated cells were less. × 3000; 9. Respiratory epithelium at higher magnification showing the goblet cell (↑), opening of glandular ducts (O) and microvillous cells (M) in respiratory region. × 3220; 10. Transitional zone-IIin the form of a transverse line (T) at the junction of respiratory and olfactory regions. × 203; 11. Transitional zone-II of respiratory (R) to olfactory region (O). × 241; 12. Transitional zone-II of respiratory (R) into the olfactory region (O) with olfactory dendrites (↑) and olfactory vesicles (V). × 977; 13. Dense meshwork of olfactory dendrites and olfactory vesicles (↑). × 899; 14. Dense meshwork of olfactory dendrites (D) and olfactory vesicles (V). × 4430; 15. Dense meshwork of olfactory dendrites (↑). × 6000; 16. Olfactory region showing the olfactory vesicles (V) and opening of Bowman's glandular ducts (↑). × 733; 17. Olfactory region at higher magnification showing the opening of glandular ducts (↑) and olfactory vesicles (V). × 2160

to dorsal nasal turbinate, ventral nasal turbinate and the rostral most portions of ethmoturbinates. The region was characterized by presence of tufts of cilia which formed a dense mat like arrangement, microvillus cells having microvilli of different shape and a few brush cells (Figs. 4-9) as observed in goat (Kumar *et al.*, 1999), horse (Kumar *et al.*, 2000), sheep (Ganganaik *et al.*, 2007), buffalo calves (Kumar *et al.*, 2008), camel (Gewaily, 2009; Abdel-Salam *et al.*, 2014). Small granules have been reported in addition to brush cells and secretory cells in nasal mucosa of the bovine (Adams, 1986) and bonnet monkey (Harkema *et al.*, 1987). The densely packed cilia were oriented in the tufts and these were directed towards the caudal direction (Figs. 5, 6). The cilia were almost of uniform size and shape with smooth surface except towards the tip where blebs like arrangement was observed (Fig. 7) as reported in the horse (Kumar *et al.*, 2000) and buffalo calves (Kumar *et al.*, 2008). At some places, the patterns of cilia beating in different waves were also observed. The wave like patterns of cilia account for the different phases of cyclic ciliary movement as reported in the goat (Kumar *et al.*, 1999) and buffalo calves (Kumar *et al.*, 2008). The rows of cilia were also observed. The tufts of cilia were densely arranged and masked the appearance of other cell types. At some places,

the dense arrangement of cilia in the form of carpet were observed only in isolated patches of varying size and in between these patches the microvillus cells of different types were observed. Similar type of patches of microvillus cells were reported in the buffalo calves (Kumar *et al.*, 2008). The microvillus cells having microvilli of different size and a few brush cells were observed in areas where density of the ciliated cells was comparatively lesser (Fig. 4). The microvillus cells possessed microvilli of varying size. In between these microvillus cells, a few ciliated cells were also present. The microvilli were so much extensive that it intermingled with those of adjacent cells and small bridge like pattern was observed. The goblet cells were visible only in the region where density of ciliated cells was less. The glandular ducts were seen in between ciliated and microvillus cells opening at the free surface of the epithelium (Figs. 8, 9) as reported in goat (Kahwa and Balemba, 1998) and sheep (Ganganaik *et al.*, 2007).

The transition zone-II was observed at the junction of respiratory and olfactory regions (Figs. 10-12). This zone was present in the form of a transverse line in the caudal part of ethmoturbinates (Fig. 10). In the goat, transition zone was observed as straight line perpendicular to nasal mucosa in the caudal part of the ethmoturbinates (Kumar *et al.*, 1999).The transitional zone lacked the ciliated cells and only microvillus and olfactory cells were observed as reported earlier in goat (Kumar *et al.*, 1999), horse (Kumar *et al.*, 2000), sheep (Ganganaik *et al.*, 2007) buffalo calves (Kumar *et al.*, 2008).

The olfactory region was confined to the cribriform plate of ethmoid bone (Figs. 13-17). However the olfactory zone was localised in the caudal most part of the dorsal nasal turbinate and the ethmoturbinates close to the cribriform plate of ethmoid bone in dog (Majid, 1986) and sheep (Ganganaik *et al.*, 2007). This region also presented different arrangements of olfactory vesicles, dendrites and axons. The olfactory region was comprised of olfactory vesicles with short hair like projections in the camel (Gewaily, 2009). In majority of the region, the olfactory vesicles were numerous which presented dendrites in different directions as reported earlier in the goat (Kumar *et al.*, 1999) and horse (Kumar *et al.*, 2000), whereas olfactory region was indicated by fewer olfactory receptors in buffalo calves (Kumar *et al.*, 2008). In some regions, these vesicles were lesser and the density of olfactory dendrites and axons were more numerous (Fig. 15) as observed in sheep (Ganganaik *et al.*, 2007) and horse (Kumar *et al.*, 2000). However the olfactory sensory cilia were much longer than the respiratory cilia as reported in the goat (Kumar *et al.*, 1999). Bowman's glandular ducts openings at the free surface of epithelium were seen in between the olfactory dendrites (Fig. 16, 17) as reported earlier in dog (Majid, 1986) and buffalo calves (Kumar *et al.*, 2008).

REFERENCES

Abdel-Salam, L.R., Moukhtar, H.G., Abdel-Raouf, A.A., and Amer, A.H. (2014). Hislological, histochemical and scanning electron microscopical study of nasal cavity epithelium of the dromedary camel (*Camelus dromedarius*). *J. Basic Med. Allied Sci.* **2**: 1-14.

Adam, D.R. (1986). Transitional epithelial zone of bovine nasal mucosa. *Am. J. Anat.* **176**: 159-70.

Ganganaik, S., Jain, R.K. and Kumar, P. (2007). Scanning electron microscopic studies on the nasal cavity of sheep (*Ovis aries*). *Indian J. Anim. Sci.* **77**: 878-879.

Gewaily M.S.M. (2009). Some anatomical studies on the nasal cavity in the one humped camel. M.V.Sc. thesis submitted to Faculty of Veterinary Medicine Kafrelsheikh University, Egypt.

Harkema J.R., Plopper C.G., Hyde D.M., Wilson D.W., St George J.A. and Wong V.J. (1987). Non olfactory surface epithelium of the nasal cavity of the bonnet monkey: A morphologic and morphometric study of the transitional and respiratory epithelium. *Am. J. Anat.* **180**: 266-279.

Kahwa, C.K.B. and Balemba, O.B. (1998).The non-olfactory nasal epithelium in the adult goat: A scanning electron microscopic study. *Small Rum. Res.* **29**: 277-282.

Kumar, P., Kumar, S. and Singh, Y. (1999). The scanning electron microscopic studies on the nasal cavity of goat. *Indian J. Anim. Sci.* **69**: 887-890.

Kumar, P., Timoney, J.F., Southgate, H.H.P. and Sheoran, A.S. (2000). Light and scanning electron microscopic studies of the nasal turbinates of the horse. *Anat. Histol. Embryol.* **29**: 103-109.

Kumar, P., Gupta, A.N. and Nagpal, S.K. (2008). Scanning electron microscopy of the nasal cavity of the buffalo calves (*Bubalus bubalis*). *Indian J. Anim. Sci.* **78**: 1094-1097.

Majid, A. (1986). A combined histological, histochemical and scanning electron microscopical study of the canine respiratory tract. Ph.D. thesis submitted to Faculty of Veterinary Medicine, University of Glasgow, UK.

Mygind, N., (1978). Applied physiology of the nose. Nasal Allergy(1st edn.) Blackwell, London, Edinburgh.

Yang, J., Dai, L., Yu, Q. and Yang Q. (2017). Histological and anatomical structure of the nasal cavity of Bama minipigs. *PLoS One.* **12**: 1-14.