Haryana Vet. (June, 2019) **58(1),** 108-110

Research Article

MICROSCOPIC CHARACTERIZATION OF HARDERIAN GLAND OF SHEEP (*OVIS ARIES*)

AMANDEEP SINGH*, PAWAN KUMAR, TEJ PARKASH, PARVEEN KUMAR GAHLOT
and IBRAHIM ALHAJI GIRGIRI
Department of Veterinary Anatomy, College of Veterinary Sciences
Lala Lajpat Rai University of Veterinary and Animal Sciences, Hisar-125 004, India

Received: 20.10.2018; Accepted: 24.12.2018

ABSTRACT

The present study was undertaken on six healthy young sheep of local breeds of either sex to study the histology and histochemistry of the Harderian gland. The parenchyma of compound tubuloacinar Harderian gland was comprised of serous, mucous and sero-mucous secretory pieces in secretory units. The secretory cells were surrounded by an incomplete layer of myoepithelial cells enclosed by a basement membrane. The interstitial tissue between adjacent secretory units varied from small thin containing only a few collagen and reticular fibres to larger containing numerous small blood vessels and nerves, scattered plasma cells and aggregates of lymphoid tissue. The tubuloacinar secretory units completely surrounded the hyaline cartilage of the third eyelid. The duct system was made up of intralobular, interlobular and large excretory ducts. The striated ducts were lacking. Histochemical studies revealed the presence of more amount of neutral mucopolysaccharides and moderate amount of weakly acidic sulfated mucosubstances, sialomucins and hyaluronic acid in the secretory units.

Key words: Harderian gland, Histology, Histochemistry, Sheep

The Harderian gland is also known as the deep gland of the third eyelid (Nomina Anatomica Veterinaria, 2012), present in the orbit just ventral and postero-medial to the eyeball. It is loosely attached to the periorbital fascia, so that when the eye is removed, it usually remains in the cavity of the orbit (Dyce *et al.*, 2018). The gland is involved in lubrication of the eye, secretion of pheromones, secretion of growth factors, osmoregulation, photoprotection and thermoregulation. It was reported that the Harderian gland possessed receptor for melatonin. The antibacterial factors in it, including immunoglobulins and soluble mucins, help to maintain corneal health (Ginkel *et al.*, 2012). Although extensive studies on the Harderian gland of chicken (Mobini, 2012), European bison (Nawrot *et al.*, 2015) and pig (Rajkhowa *et al.*, 2018) were available in the literatures, the sheep has received little attention. Keeping in view the importance of Harderian gland, the present study describes light microscopic details of the gland in young sheep and its comparison with other domestic animals.

MATERIALS AND METHODS

The Harderian gland used in the present study were obtained from six healthy young sheep of local mixed breed of either sex. The heads were procured from local slaughter house immediately after decapitation and the tissues were fixed in a 10% neutral buffered formalin solution for 48 hours, subjected to routine tissue processing for light microscopic examination and embedded in paraffin blocks. The paraffin sections (5-6 μ) were made through the entire gland and stained with routine Harris' hematoxylin and eosin stain for general histomorphological examination, Gomori's stain for reticular fibres, Weigert's method for elastic fibres (Luna, 1968) and Crossman's trichrome stain for collagen fibres (Crossman, 1937). In addition, selected sections were processed for histochemical demonstration of mucopolysaccharides using PAS-Alcian blue, Alcian blue, McManus' method, colloidal iron method and Mayer's mucicarmine method (Luna, 1968).

RESULTS AND DISCUSSION

The Harderian gland of sheep was of compound tubuloacinar type, however, the gland has been reported compound tubulo-alveolar type by Kozlu *et al.*, 2010; Mobini, 2012 and Rajkhowa *et al.*, 2018. It was encapsulated by a thick layer of fibrous connective tissue as reported by Boydak and Aydin (2009) in domestic geese and Kozlu *et al.* (2010) in osprey. The histological structure of this gland included a stroma and parenchyma. The stroma divided the gland to many lobes and lobules via the interlobular septae. The size of lobules varied without a definite pattern. The separating connective tissue was rich in blood vessels, adipocytes and possessed excretory ducts. The glandular parenchyma was represented by the secretory end pieces and duct system. Similar type of findings had been observed by Nawrot *et al.* (2015) in European bison and Rajkhowa *et al.* (2018) in pig. The secretory end pieces consisted of a majority of serous acini, a minority of mucous acini and seromucous (mixed) secretory units (Fig. 1). Each acinus was composed of pyramidal or low columnar cells. In serous acini, rounded nuclei were located near the basal region of the cells, whereas cytoplasm was eosinophilic in nature (Fig. 2). The mucous cells had a vacuolar cytoplasm and their elongated nuclei were situated towards the cell base. These secretory cells were surrounded by an incomplete layer of myoepithelial cells enclosed by a basement membrane. Similar findings were revealed by Altunay and Kozlu

[2]Corresponding author: dramandeep287@gmail.com

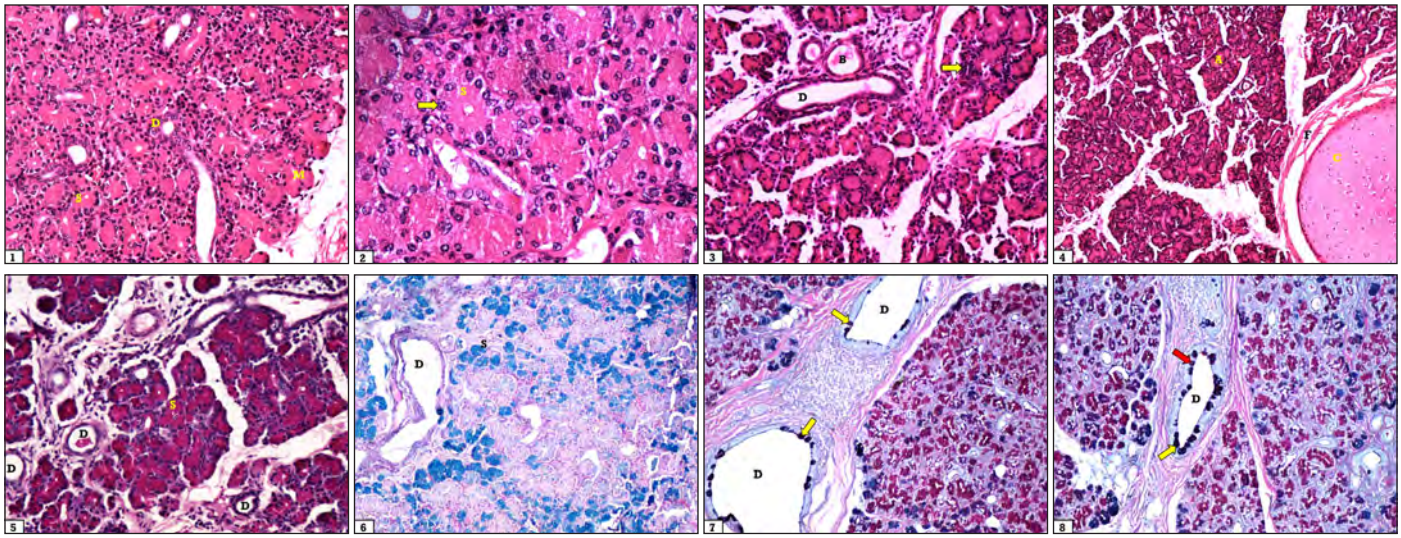

Fig 1. Photomicrograph of Harderian gland of sheep showing the glandular parenchyma consists of majority of serous acini (S), a minority of mucous acini and seromucous/mixed (M) secretory units as well as intralobular ducts (D). H. & E.×100; 2. Photomicrograph of Harderian gland of sheep showing that the rounded nuclei (arrow) were located near the basal region of the serous cells (S), whereas cytoplasm was eosinophilic in nature. H. & E.×400; 3. Photomicrograph showing the interstitial tissue present between adjacent secretory units contains numerous small blood vessels (B) and nerves, interlobular ducts (D), scattered plasma cells and aggregates of lymphoid tissue (arrow) in the Harderian gland of sheep. H. & E.×100; 4. Photomicrograph of Harderian gland of sheep showing the hyaline cartilage (C) surrounded by thick layer of connective tissue fibres (F) and tubuloacinar secretory units (A). H. & E.×40; 5. Photomicrograph showing a strong periodic acid-Schiff (PAS) positive reaction in the secretory units (S) of the sheep Harderian gland indicating the presence of high amount of neutral mucopolysaccharides however, the epithelium of all the ducts (D) showed negative reaction. PAS x100; 6. Photomicrograph of Harderian gland of sheep showing a weakly acidic sulfated mucosubstances, sialomucins and hyaluronic acid in the secretory units (S) whereas ductal epithelium (D) revealed negative reaction. Alcian blue x100; 7. Photomicrograph showing strong positive reactivity in the goblet cells (arrow) of interlobular and large excretory ducts (D) of sheep Harderian gland. PAS-AB x 40; 8. Photomicrograph of Harderian gland of sheep showing an intense positive reactivity in goblet cells for acid mucopolysaccharides (yellow arrow), however few goblet cells showed strong positive reaction for neutral mucopolysaccharides (red arrow). PAS-AB x 40

(2004) in ostrich. The relative proportion of serous and mucous acini was variable, depending on the position within the lobule. The mucous acini were preferentially located toward the periphery of the lobules.

The interstitial tissue between adjacent secretory units varied from small thin area containing only a few collagen and reticular fibres to larger area containing numerous small blood vessels and nerves, scattered plasma cells and aggregates of lymphoid tissue (Fig. 3) as observed by Scott *et al.* (1993) and Mobini (2012) in chicken; Nawrot *et al.* (2015) in European bison and Rajkhowa *et al.* (2018) in pig.

The tubuloacinar secretory units completely surrounded the cartilage of the third eyelid, which was hyaline in nature. The hyaline cartilage was surrounded by a thick layer of elastic and collagen fibres having large amount of blood vessels (Fig. 4). At the periphery of connective tissue fibres, white adipose and lymphoid tissues were present as reported in birds (Payne, 1994) and pig (Rajkhowa *et al.*, 2018).

The secretory units were followed by a duct system. The excretory duct system was made up of intralobular, interlobular and large excretory ducts. The intercalated ducts were lined with simple cuboidal epithelium which gradually increased in height to become stratified cuboidal epithelium in interlobular and stratified squamous in the large excretory ducts. The striated ducts were absent. These findings were in fully agreement with those reported by Nawrot *et al.* (2015) in European bison and Rajkhowa *et al.* (2018) in pig. Typical myoepithelial cells incompletely encircled the intralobular ducts. Goblet cells were present among the epithelium of interlobular and large excretory ducts with their varied numbers.

A strong periodic acid-Schiff (PAS) positive reaction was seen in the secretory units of the gland indicating the presence of high amount of neutral mucopolysaccharides however, the epithelium of all the ducts showed negative reaction (Fig. 5). A few secretory units and a few secretory cells in some secretory units showed weakly acidic sulfated mucosubstances, sialomucins and hyaluronic acid in the secretory units whereas ductal epithelium revealed negative reaction (Fig. 6). Similar findings were reported in the Harderian glands of South American armadillo (Marcos *et al.*, 2002), American bison and cattle (Pinard *et al.*, 2003) and chicken (Mobini, 2012). The goblet cells in the interlobular and large excretory ducts showed strong positive reactivity for both PAS and AB methods (Fig. 7). Nawrot *et al.* (2015) in European bison and Pinard *et al.* (2003) in American bison and cattle reported that PAS showed a negative reaction in large alveoli but a positive reaction in smaller alveoli.

PAS-AB method revealed strong positive reaction for both neutral and acid mucopolysaccharides in the secretory units, with the predominance of neutral mucopolysaccharides. The goblet cells presented the intense positive reactivity for acid mucopolysaccharides in the ducts, however a few goblet cells showed strong positive reaction for neutral mucopolysaccharides also (Fig. 8). Similar differences in the staining reaction were also observed in cattle and the American bison (Pinard *et al.*, 2003). Mayer's mucicarmine and colloidal iron methods showed moderate positive reaction which indicated the presence of acid mucopolysaccharides in the secretory cells.

REFERENCES

Altunay, H. and Kozlu, T. (2004). The fine structure of the Harderian gland in the ostrich (*Struthio camelus*). *Anat. Histol. Embryol.* **33**: 141-145.

Boydak, M. and Aydin, M.F. (2009). Histology of the Harderian gland of domestic geese (*Anser anser domesticus*). *Acta Vet. Brno.* **78**: 199-204.

Crossman, G.A. (1937). A modification of Mallory's connective tissue stain with a discussion of principles involved. *Anat. Rec.* **69**: 33-38.

Dyce, K.M., Sack, W.O. and Wensing, C.J.G. (2018). Textbook of Veterinary Anatomy. (5th edn.), Saunders-Elsevier Science, Philadelphia.

Kozlu, T., Bozkurt, Y.A., Altunay, H. and Sari, E.K. (2010). Histological and histochemical studies on the Harderian gland of the osprey (*Pandion haliaetus*). *J. Anim. Vet. Adv.* **9**: 1875-1879.

Luna, L.G. (1968). Manual of Histologic Staining methods of Armed Forces Institute of Pathology. (3rd edn.), McGraw Hill Book Co., New York.

Marcos, H.J.A., Ferrari, C.C., Cervino, C. and Affanni, J.M. (2002). Histology, histochemistry and fine structure of the lacrimal and nictitans gland in the South American armadillo (*Chaetophractus villosus*). *Environ. Sci.* **75**: 731-744.

Mobini, B. (2012). Histological and histochemical studies on the Harderian gland in native chickens. *Vet. Med.* **57**: 404-409.

Nawrot, J.K., Nowaczyk, R., Harlaczuk, K.G., Szara, T. and Olbrych, K. (2015). Histology, histochemstry and fine structure of Harderian gland, lacrimal gland and superficial gland of third eyelid of the European bison. *Zool.* **32**: 380-394.

Nomina Anatomica Veterinaria. (2012). Nomina Anatomica Veterinaria. Hannover, World Association of Veterinary Anatomists, (5th edn.), pp: 149-150.

Payne, A.P. (1994). The Harderian gland: A tercentennial review. *J Anat.* **185**: 1-49.

Pinard, C.L., Weiss, M.L., Brightman, A.H., Fenwick, B.W. and Davidson, H.J. (2003). Normal anatomical and histochemical characteristics of the lacrimal glands in the American bison and cattle. *Anat. Histol. Embryol.* **32**: 257-262.

Rajkhowa, J., Sarma, K., Deka, A. and Sinha, S. (2018). Macro and micro anatomical study of Harderian gland of pig. *J. Entomol. Zool. Stud.* **6**: 166-168.

Scott, T.R., Savage, M.L. and Olah, I. (1993). Plasma cells of the chickens Harderian gland. *Poult. Sci.* **72**: 1273-1279.

Ginkel, V., Gulley, S.l., Lammers, A., Hoer, F.J., Gurjar, R. and Toro, H. (2012). Conjunctiva-associated lymphoid tissue in avian mucosal immunity. *Dev. Comp. Immunol.* **36**: 289-297.