Haryana Vet. (December, 2020) **59(2)**, 236-238

Research Article

AN INSIGHT INTO HAEMATO-BIOCHEMICAL PROFILE DURING OPEN PYOMETRA AND ITS SUCCESSFUL MANAGEMENT BY METHYLERGOMETRINE IN SHE DOGS

AKSHAY SHARMA*, ISHA SHARMA, ANANYA SHARMA, MADHUMEET SINGH and PRAVESH KUMAR
Department of Veterinary Gynaecology and Obstetrics,
Dr. G.C. Negi College of Veterinary and Animal Sciences, CSKHPKV, Palampur-176062, India

Received: 23.12.2019; Accepted: 19.02.2020

ABSTRACT

Open pyometra is a secondary infection that occurs as a result of hormonal changes in reproductive tract and characterized by an open or relaxed cervix and draining out of pus from vulva. It was diagnosed on the basis of history, clinical signs and ultrasonography in nine she dogs. Pretreatment evaluation of physiological, haematological and biochemical parameters was done. B-mode ultrasonography was used to measure the uterine horn diameter and diagnose cystic endometrial hyperplasia. Treatment was done with methylergometrine (oral) and ceftriaxone (injectable) for seven days. On ultrasonographic examination, it was found that there was significant reduction ($p<0.01$) in the diameter of the uterine horns after treatment. Also, there was significant improvement ($p<0.05$) in haematological and biochemical parameters after completion of the treatment. Thus, regimen of methylergometrine combined with antibiotic can be effectively used for the treatment of open pyometra in she dogs without any side effects.

Keywords: B-mode ultrasonography, Haematological parameters, Methylergometrine, Open pyometra, She dogs

Pyometra is a hormonally mediated acute or chronic poly-systemic diestrual disorder, characterised by accumulation of purulent substance inside the uterus of intact she dogs, and is the most common genital disease leading to high mortality in untreated cases (Coggan *et al.*, 2008; Singh *et al.*, 2010). The pathogenesis of pyometra is incompletely understood, but it is considered that the hormonal influence of progesterone during its cyclic luteal phase leads to proliferation of endometrium, stimulation of endometrial glands secretions, suppression of myometrial contractions, closure of cervix and negative effects on uterine immunity while protecting against infections (Sant'Anna *et al.*, 2014). This favours the bacterial growth and colonization as the local leukocyte response and uterine resistance to bacterial infection is also suspended (Wijewardana *et al.*, 2015).

Various treatment protocols have been designed for the treatment of open pyometra in bitch. The treatment protocols include progesterone inhibition either directly by luteolysis using prostaglandins or indirectly either by using a dopamine-agonist which induces functional arrest and inhibition of prolactin or by using a progesterone-receptor antagonist such as aglepristone which prevents progesterone binding to its receptors (Verstegen *et al.*, 2008). Methylergometrine is a synthetic analogue of ergonovine, which causes smooth muscle contractions via serotonin receptors thereby helps to evacuate pus from the uterus along with reduction in the endometrial hyperplasia (Noakes *et al.*, 2001).

A very limited research is available on the treatment of open pyomtera with methylergometrine in she dogs (Haji *et al.*, 2018; Kantharaj *et al.*, 2018), therefore, the present research was conducted to study the efficacy of methylergometrine in she dogs having open pyometra.

*Corresponding author: akshays482@gmail.com

MATERIALS AND METHODS

The present study was conducted in she dogs presented at Department of Veterinary Gynaecology and Obstetrics, CSKHPKV, Palampur, Himachal Pradesh with the history of vomition, anorexia, foul smelling discharge from vagina, depression/lethargy, polydipsia, polyuria, fever, dehydration and abdominal distension. The study involved nine she dogs (n=9) of different breeds (Labrador and Pomeranian) aged 5-10 years having open pyometra. Diagnosis was based on history, clinical signs and B-mode ultrasonography. The blood was collected with and without anticoagulant for haematological and biochemical analysis before and after treatment. B-mode ultrasonography was performed to visualize the uterus using Mindray DC3 model with trans-abdominal (convex) probe at 5.0 MHz and the uterine horn diameter was measured using machine's inbuilt digital caliper.

The she dogs were treated with Methylergometrine 0.125 mg orally once a day for 7 days. Additionally, Inj. Ceftriaxone and Tazobactam combination @ 25 mg/kg body weight and supportive fluid @ 22 ml/kg body weight and additional 5 percent of body weight according to dehydration for 3 days intravenously were administered for 7 days. The data obtained was statistically analysed using one way ANOVA (analysis of variance) with SAS (Statistical Analysis Software), SAS® 9.2 TS Level version 2M2 for windows (USA).

RESULTS AND DISCUSSION

The haematological investigation revealed marked rise in TLC with characteristic increase in percent neutrophils before treatment (Table 1). However, post treatment evaluation revealed a significant decrease

(p<0.05) in TLC and percent neutrophils (p<0.01). Low heamatocrit (HCT) values as compared to reference range were encountered in she dogs before treatment. Our results were in concurrence with the findings of Patil *et al.*, (2013) who also reported marked leucocytosis with neutrophilia and monocytosis just to combat infection (Mojzisova *et al.*, 2000). Similarly, Gupta and Dhami (2013) reported that reduced level of Hb, HCT, TEC, platelets along with elevated level of total leucocyte count (TLC) and granulocytes is an indication of toxaemia in canine pyometra complex. Maddens *et al.* (2011) also found normocytic, normochromic regenerative anaemia which is in agreement to our findings. Decreased erythropoeisis may occur due to iron sequestration within the myeloid cells in the bone marrow and can also lead to erythrocyte diapedesis (Nath *et al.*, 2009). After treatment, haematocrit value increased significantly (p<0.05) and found well within normal range.

In order to access the renal functions, blood urea nitrogen (BUN) and creatinine in affected dogs were found higher than the reference range. After treatment, there was a significant decrease (p<0.05) in BUN and creatinine values (Table 1). Jitpean *et al.* (2014) found an increase in creatinine and BUN which is similar to our findings and indicates the hampered efficiency of kidneys to remove nitrogenous waste from the circulation (Gayakwad *et al.*, 1999). Renal dysfunction is a result of endotoxemia, glomerular dysfunction and renal tubular damage (Maddens *et al.*, 2011). Treatment with cloprostenol and methylergometrine for 7 days showed a significant improvement in haematological and biochemical parameters (Haji *et al.* 2018) in previous reports. Kantharaj *et al.* (2018) also reported a significant improvement in physiological, haematological and biochemical parameters after treatment with methylergometrine and antibiotics for 7 days.

All other haematological parameters i.e. Haemoglobin (g%; HGB), Total erythrocyte count (1012/L; TEC), Mean corpuscular volume (Femtolitre, Fl; MCV), Mean Corpuscular Haemoglobin (Picogram, Pg; MCH) and Mean Corpuscular Haemoglobin Concentration (g%; MCHC) witnessed a non-significant increase (p>0.05) in their values after treatment with methylergometrine. Rectal temperature was also found to be slightly higher in she dogs before treatment. All the she dogs were having moderate thrombocytopenia before treatment. However, a non-significant increase (p>0.05) in blood platelet count was evident after treatment (Table 1).

B-mode ultrasonography showed the presence of multiple hypo- to an-echoic sacs of pus inside the uterus and endometrial hyperplasia before treatment (Fig. 1 and 2). However, absence of hypoechoic sacs and decreased endometrial thickness was evident after treatment. Similarly, longitudinal diameter of uterine horn reduced significantly (p<0.01) which is suggestive of the efficacy of methylergometrine in treating open pyometra (Table 2). B-mode ultrasonography imaging has been one of the best diagnostic tool to observe hypoechoic sacs (Gupta *et al.*, 2013), with pus within the uterus showing slow, whirlpool like pattern which is similar to our findings (Bigliardi *et al.*, 2004; Kantharaj *et al.*, 2018). In

Table 1

Physiological, haematological and biochemical parameters in she dogs with open pyometra before and after treatment (Mean ± SE)

Parameters	Units	Day 0 (Pre treatment)	Day 8 (Post treatment)	Referral range (Merck's Veterinary Manual, 2016)
Rectal temperature	ºF	102.3 ± 0.47	101.4 ± 0.56	100-102
WBC	109/L	20.57 ± 2.87[a]	13.8 ± 1.08[b]	5-14.1
Lymphocytes	%	15.05 ± 1.42[a]	20.19 ± 1.84[b]	8 to 21
Monocytes	%	3.08 ± 0.14	2.75 ± 0.16	2 to 10
Neutrophils	%	79.5 ± 2.62[x]	66.38 ± 1.48[y]	45 to 75
TEC	1012/L	6.23 ± 0.85	6.84 ± 0.96	5 to 10
Hb	g/dl	13.22 ± 2.13	14.28 ± 1.36	9.8 to 15.4
HCT	%	31.73 ± 2.71[a]	41.28 ± 2.42[b]	35 to 57
MCV	Fl	70.74 ± 3.22	73.85 ± 2.33	66 to 77
MCH	Pg	21.25 ± 0.39	23.58 ± 0.76	21 to 26.2
MCHC	g/dl	33.78 ± 0.46	34.04 ± 0.78	32 to 36.3
PLT	109/L	197 ± 35.53	288.86 ± 44.43	211 to 621
BUN	mg%	34.07 ± 3.75[a]	22.36 ± 1.86[b]	8 to 28
Creatinine	mg%	2.7 ± 0.36[a]	1.46 ± 0.42[b]	0.5 to 1.7

[a,b] Values with different superscripts within the same row are significantly different (p<0.05)
[x,y] Values with different superscripts within the same row are significantly different (p<0.01)

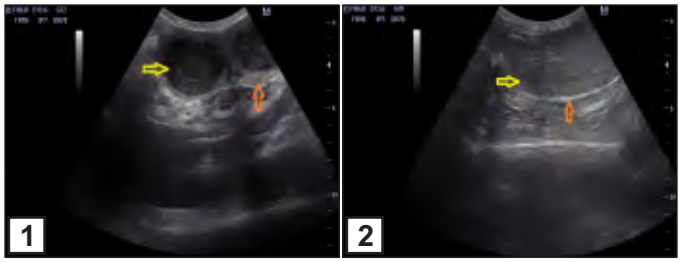

Fig. 1 & 2. **(1)** Hypoechoic areas of pus inside uterus (yellow arrow) and increased endometrial thickness evident of cystic endometrial hyperplasia (orange arrow) before treatment with methylergometrine. **(2)** Clear uterus with no hypochoic appearance of pus (yellow arrow) and reduced thickness of endometrium (orange arrow) after treatment with methylergometrine

Fig. 1 & 2. B-mode ultrasonography of bitch diagnosed with open pyometra

Table 2

Uterine horn diameter in she dogs with open pyometra before and after treatment (Mean ± SE)

Ultrasonography parameter	Pre treatment (Day 0)	Post treatment (Day 8)
Uterine horn diameter (mm)	26.78 ± 2.14^{x}	12.84 ± 1.89^{y}

x,y Values with different superscripts within the same row are significantly different ($p<0.01$)

agreement to Kantharaj *et al.*, (2018), the uterine horn diameter was reported to be higher in she dogs with pyometra as compared to clinically normal she dogs in diestrus. Yeager and Concannon (1995) also reported that the uterine diameter of 10-11 mm with little fluid inside uterus is normal during diestrus.

In conclusion, treatment with methylergometrine along with antibiotic course had been associated with significant improvement in physiological, haematological, biochemical and ultrasonographical parameters of the she dogs suffering from open pyometra, without any side effects.

REFERENCES

Bigliardi, E., Prmigiani, E., Cavirani, S., Luppi, A., Bonati, L. and Corradi, A. (2004). Ultrasonography and cystic hyperplasia-pyometra complex in the bitch. *Reprod. Dom. Anim.* **39**:136-140.

Coggan, J.A., Melville, P.A., de Oliveira, C.M., Faustino, M., Moreno, A.M. and Benites, N.R. (2008). Microbiological and histopathological aspects of canine pyometra. *Braz. J. Microbiol.* **39**: 477-483.

Gayakwad, S.G., Ranganath, B.N., Jayadevappa, S.M., Krishnaswamy, J. (1999). Observations on biochemical changes in canine pyometra. *Indian Vet. J.* **76**: 289-290.

Gupta, A.K., Dhami, A.J., Patil, D.B., Kumar, D. and Darr, M. (2013). Clinical and ultrasonographic evaluation of Bitches affected with pyometra. *Indian J. Field Vet.* **8**(3): 1-4.

Gupta, A.K. and Dhami, A.J. (2013). Haematological alterations in bitches affected with pyometra. *Indian J. Field Vet.* **9**(1): 1-5.

Haji, M.M., Borpujari, D., Talukdar, D.J., Ahmed, F.A., Lalrintluanga, K. and Sarma, K. (2018). Cystic endometrial hyperplasia- open pyometra complex in a female pug. *Indian J. Anim. Reprod.* **39**:63-65.

Jitpean,S., Strom-Holst, B. and Emanuelson, U. (2014). Outcome of pyometra in female dogs and predictors of peritonitis and prolonged postoperative hospitalization in surgically treated cases. *BMC Vet. Res.* **10**:6.

Kantharaj, S., Antoine, D., Murugavel, K., Shalini, G., Kunde A.A.S., Hemalatha, H. and Raju, M.S. (2018). Treatment of open pyometra with methylergometrine in bitches. *Indian Vet. J.* **95**(5): 49-51.

Maddens, B., Heine, R., Smets, P., Svensson, M., Aresu, L., Van der Lugt, J., Daminet, S. and Meyer, E. (2011). Evaluation of kidney injury in dogs with pyometra based on proteinuria, renal histomorphology and urinary biomarkers. *J. Vet. Intern. Med.* **25**(5): 1075-1083.

Mojzisova, J., Valocky, I. and Maracek, I. (2000). Monitoring of selected immunological parameters in bitches with glandular cystic hyperplasia pyometra complex before and after ovariohysterectomy. *Polish Vet. Sci.* **3**: 23-27.

Nath, K., Tiwari, S.K. and Kalim, O. (2009). Physiological and haematological changes in bitches with pyometra. *Indian Vet. J.* **86**: 734-736.

Noakes, D.E., Dhaliwal, G.K. and England, G.C. (2001). Cystic endometrial hyperplasic/pyometra in dogs: A review of the causes and pathogenesis. *J. Reprod. Fertil.* **57**: 395-406.

Patil, A.R., Swamy, M., Chandra, A. andJawre, S. (2013). Clinico-haematological and serum biochemical alterations in pyometra affected bitches. *Afri. J. Biotechnol.* **12**(13): 1564- 1570.

Sant'Anna, M.C., Giordano, L.G.P., Flaiban, K.K.M.C., Muller, E.E. and Martins, M.I.M. (2014). Prognostic markers of canine pyometra. *Arq. Bras. Med. Vet. Zootec.* **66**(6): 1711-1717.

Singh, K.P., Singh, B., Singh, J.P., Singh, S.V., Singh, P. and Singh, H.N. (2010). Diagnostic and therapeutic management of pyometra in bitches. *Intas Poli.* **11**(1): 86-87.

Verstegen, J., Dhaliwal, G. and Onclin, K.V. (2008). Mucometra, cystic endometrial hyperplasia, and pyometra in the bitch: Advances in treatment and assessment of future reproductive success. *Theriogenology* **70**: 364-374.

Wijewardana, V., Sugiura, K. and Wijesekera, D.P. (2015). Effect of ovarian hormones on maturation of dendritic cells from peripheral blood monocytes in dogs. *J. Vet. Med. Sci.* **77**: 771-775.

Yeager, A.E. and Concannon, P.W. (1995). Ultrasonography of the Reproductive Tract of the Female Dog and Cat. In: Current Veterinary Therapy, Kirk, R. and Bonagura, J. (Edts.), WB Saunders Co., Philadelphia. pp. 1040-1052.