*Haryana Vet.* (December, 2020) **59(2)**, 245-247

**Short Communication**

# COMPARATIVE DISTRIBUTION OF HAIR FOLLICLES IN SKIN OF DIFFERENT DOMESTIC ANIMALS

SHWETA RAGHAV, VARINDER UPPAL* and ANURADHA GUPTA
Department of Veterinary Anatomy, College of Veterinary Science
Guru Angad Dev Veterinary and Animal Sciences University, Ludhiana-141 004, India

Received: 15.01.2020; Accepted: 01.02.2020

## SUMMARY

The present study was conducted on the skin of adult cattle, buffalo, horse, goat, pig and dog (six samples of each) collected from slaughter house and post-mortem hall of the university. The collected skin samples were fixed in 10% neutral buffered formalin and processed for paraffin block preparation. The sections of 5-6 µm thickness were cut with rotary microtome and stained with hematoxylin and eosin stain. The distribution of hair follicle/mm$^2$ was maximum in buffalo and minimum in pig whereas hair follicle diameter was maximum in pig and minimum in dog.

**Keywords:** Buffalo, Cattle, Goat, Horse, Pig, Dog, Hairfollicle, Skin

The skin (cutis) derived from the Latin word meaning "Roof". Hairfollicles vary considerably in type and size. It undergoes a cyclic transformation from the stages of rapid growth (anagen) to apoptosis driven regression (catagen) and back to anagen, via an interspersed period of relative quiescence (telogen) (Paus *et al.*, 2014). In literature, histomorphological studies on skin are available in sheep (Purushothaman *et al.*, 2010; Mobini, 2012), goat (Nagaraju *et al.*, 2012), pig (Sumena *et al.*, 2012), cattle (Nagaraju *et al*., 2012) and buffalo (Dhandu *et al.*, 1998; Debbarma *et al.*, 2018), but scanty information is available regarding comparative distribution of hair follicles in skin of domestic animals. Thus, the present study was designed to provide comparative distribution of hair follicles in skin of domestic animals.

The study was conducted on the skin of adult cattle, buffalo, horse, goat, pig and dog (six samples of each) from slaughter house and post-mortem hall of GADVASU, Ludhiana. The tissues were fixed in 10% neutral buffered formalin and processed for paraffin block preparation (Luna, 1968). The sections of 5-6 µm thickness were cut with rotary microtome and stained with hematoxylin and eosin stain. The micrometrical observations on number of hair follicle /mm$^2$ and diameter of hair follicle were recorded in different animals The data obtained were statistically analyzed.

Hair follicle consisted of four major components hair matrix, dermal papillae, internal epithelial root sheath and external epithelial root sheath. Internal epithelial root sheath was further divided into three different parts: (a) internal root sheath (b) Huxley's layer (middle granular epithelial layer) (c) Henley's layer (outer pale epithelial layer). The cuticle of the internal epithelial root sheath was formed by overlapping keratinized cells; this arrangement resulted in solid implantation of hair root in the hair follicle. The middle granular epithelial layer was composed of 2-3 layers of cells which were rich in keratohyaline granules. The outer most layers were composed of a single layer of keratinized cells. The external epithelial root sheath was composed of several layers of cells similar to the epidermis with which it was continuous in the upper portion of the follicle. The entire epithelial root sheath was enclosed by a dermal root sheath. The arrector pilli muscles were attached to the dermal root sheath of the hair follicles as earlier reported by Dellmann (1993) in domestic animals. The hair follicle was surrounded by abundant collagen, reticular and elastic fibers as reported by Das *et al.*, (2019) in Assam Hill goat.

In the present study, the hair follicles of buffalo, horse, cattle, goat and pig were simple type (Fig.1-6). Primary hair follicle was associated with sebaceous, sweat gland and arrector pilli muscles as reported by Jenkison and Nay (1975) in water buffalo, Dellmann (1993) in domestic animals and Debbarma *et al.*, (2018) in buffalo. In buffalo, cattle, horse and goat, the primary follicles were arranged in linear rows, in pig, they were randomly distributed, whereas in dog the hair follicles were of compound type that arranged in a capsular form. Each compound follicle was consisted of one large primary follicle with six to eight secondary follicles. The secondary hair follicles lacked sweat gland and arrector pilli muscles. The compound follicles were encapsulated with fibrous connective tissue (Fig.1-6). Debbarma *et al.* (2018) reported that the hair follicles were of simple type and arranged in number of rows in buffalo skin and the

*Corresponding Author: v.uppal@yahoo.com

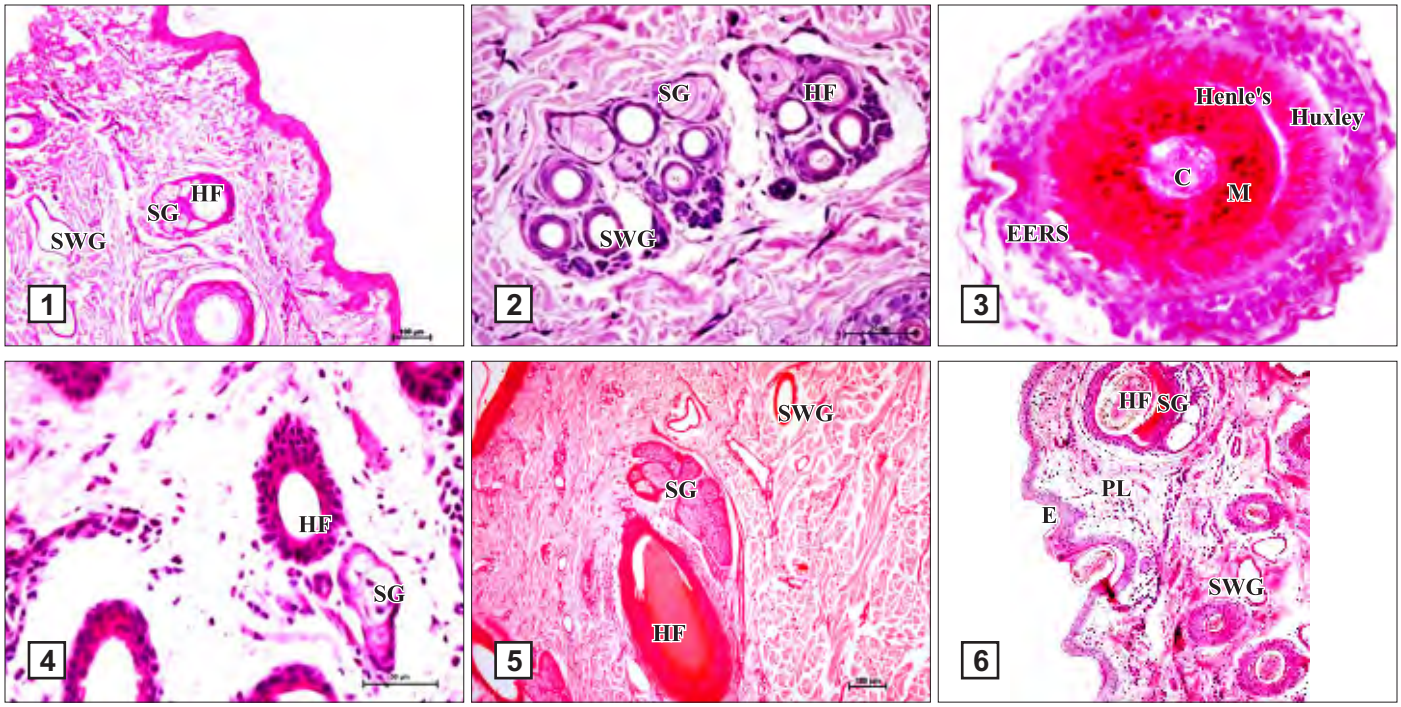


Fig. 1-6. **(1)** Buffalo skin showing hair follicle (HF), sebaceous gland (SG) and sweat gland (SWG). H. & E. x 100. **(2)** Skin of dog showing hair follicle (HF), sebaceous gland (SG) and sweat gland (SWG). H. & E. x 400. **(3)** Skin of pig showing cortex(C), medulla (M), Huxley layer, Henley's layer and external epithelial root sheath (EERS). H. & E. x 400. **(4)** Skin of cow showing hair follicle (HF) and sebaceous gland (SG) . H. & E. x 400. **(5)** Skin of goat showing hair follicle (HF), sebaceous gland (SG) and sweat gland (SWG). H. & E. x 100. **(6)** Skin of horse showing hair follicle (HF), sebaceous gland (SG) sweat gland (SWG), papillary layer (PL) and epidermis (E). H. & E. x 400.

**Table 1**

**Comparison of diameter of hair follicle and number of hair follicles/mm2 in different animals.**

| Species | Hair follicle diameter (µm) | Hair follicle number/mm$^2$ |
|---|---|---|
| Buffalo | $233.15 \pm 17.59^{b}$ | $1.91 \pm 0.28^{a}$ |
| Cattle | $140.57 \pm 7.37^{c}$ | $1.46 \pm 0.11^{ab}$ |
| Goat | $172.83 \pm 16.33^{b}$ | $1.30 \pm 0.08^{b}$ |
| Horse | $92.50 \pm 2.23^{d}$ | $0.75 \pm 0.15^{c}$ |
| Dog | $32.34 \pm 3.88^{e}$ | $1.09 \pm 0.06^{bc}$ |
| Pig | $274.50 \pm 20.88^{a}$ | $0.7 \pm 0.12^{c}$ |

Mean value with same superscript, with in column does not differ significantly ($p \leq 0.05$)

distribution varied in different regions of the body. Obayes (2016) reported that hair follicles in horse were of simple type and distributed evenly. Nagaraju *et al.,* (2012) reported that hair follicles in cattle and goat were of simple type and were arranged in linear fashion whereas hair follicle in dog was of compound type i.e. composed of cluster of hair follicle. Mangelsdorf *et al.*, (2013) reported that hair follicles distribution was random in pig skin and were in cluster in dog skin but a consistent cluster was not observed. In contrary to the above findings, Saleemm *et al.,* (2016) in goat reported that hair follicles were arranged in cluster of three. Primary follicles were larger in diameter. Secondary follicles were located at the deeper part of the dermis at an oblique angle by arrector pilli muscle in association with the sebaceous gland.

The diameter and number of hair follicle in different domestic animals has been summarized in Table 1. The maximum number of hair follicle/mm$^2$ was observed in buffalo (1.91±0.28), followed by cattle (1.46±0.11), goat (1.30±0.08), dog (1.09± 0.06) and horse (0.75±0.15) whereas as minimum number of hair follicle/mm$^2$ was seen in pig. It was inferred from the table that the numbers of hair follicle/mm$^2$ of buffalo were significantly ($p \leq 0.05$) higher than goat, horse, dog and pig except cattle. The number of hair follicle/mm$^2$ of cattle and goat were significantly ($p \leq 0.05$) higher than that of number of hair follicle/mm$^2$of horse and pig where as number of hair follicle/mm$^2$ of cattle does not differ significantly ($p \geq$

0.05) with goat and dog. The difference in the number of hair follicle/mm$^2$ between pig and horse was non-significant ($p \geq 0.05$). Mangelsdorf *et al.* (2013) reported the lowest density of hair follicles in pig.

The diameter of hair follicles of different domestic animals has been summarized in Table 1. The maximum hair follicle diameter was observed in pig (274 ± 20.88 µm) followed by buffalo (233 ± 17.59 µm), goat (172.83 ± 16.33 µm), cattle (140.57 ± 7.37 µm), horse (92.5 ± 2.23 µm) and dog (32.34 ± 3.88 µm). The diameter of hair follicle of pig was significantly ($p \leq 0.05$) more than that of buffalo, cattle, goat, horse and dog. Hair follicle diameter of buffalo and goat varied non-significantly ($p \geq 0.05$) from each other. The hair follicle diameter of cattle was significantly ($p \leq 0.05$) higher than that of horse and dog. The hair follicle diameter of dog was significantly ($p \leq 0.05$) lowest among all of the species.

Debbarma *et al.* (2018) reported maximum hair follicle diameter in buffalo as 263.93 ± 6.17 µm. Bhattacharya (2000) reported hair follicle depth was 160-200 µm in buffalo, 122-139 µm in goat and 160-259 µm in cow. In contrary to the current findings, Hazarika (2012) reported hair follicle diameteras 54.91±3.72 µm in black Bengal goat.

## REFERENCES


Bhattacharya, M.K. (2000). "Histoarchitecture of skin of Buffalo, Cow, Goat and Rabbit." M.V.Sc. thesis submitted to West Bengal University of Animals and Fishery Sciences. Kolkata, India.

Das, S., Sarma, K. and Talukdar, M.(2019). Histomorphometric study of hair follicle of Assam hill goat during pre-ruminant, transitional and ruminant age groups. *J. Entomol. Zool. Stud.* **7(1)**: 1559-566.

Debbarma, D., Uppal, V., Bansal, N., and Gupta, A. (2018). Histomorphological study on regional distribution of hair follicles in buffalo skin. *Indian Vet. J.* **95(4)**: 36-40.

Dellmann, H.D.(1993). Textbook of Veterinary Histology (4th Edn.). Lea and Febiger, Philadelphia.

Dhandu, P.L., Patil, A.S. and Nandeshwar, N.C. (1998). Sweat glands, sebaceous glands and hair follicles distribution in various body regions of Mehsana buffaloes (*Bubalus bubalis*). *Indian Vet. J.* **75**: 434-37.

Hazarika, D. (2012). Histomorphological study of skin of different regions of black Bengal goat (*Capra hircus*). M.V.Sc. thesis submitted to West Bengal University of Animals and Fishery Sciences. Kolkata, India.

Jenkison, D.M., and Nay, T. (1975). The sweat glands and hair follicles of different species of bovidae. *Aus. J. Biol. Sci.* **28**: 55-68.

Luna, L.G. (1968). Manual of Histological staining methods of the armed forces institute of pathology (3rd Edn). McGraw-Hill Book Company, New York.

Mangelsdorf, S., Vergou, T., Stery, W., Lademann, J. and Patzelt, A. (2013). Comparative study of hair follicle morphology in eight mammalian species and humans. *Skin Res. Technol.* pp. 1-8.

Mobini, B. (2012). Histology of the skin in an Iranian native breed of sheep at different ages. *J. Vet. Adv.* **2**: 226-31.

Nararaju, G.N., Prasad, R.V., Jamuna, K.V. and Ramkrishna, V. ( 2012). Histomorphological features in the differentiation of skin of Spotted Deer (*Axis axis*), Cattle (*Bos indicus*) and Goat (*Capra hircus*). *Indian J. Vet. Anat.* **24**: 10-12.

Obayes, A.K. (2016). Histological study of skin of horse. *Tikrit J. Pure Sci.* **21(1)**: 31-35.

Paus, R., Langan, E.A., Vidali, S., Ramot, Y., and Anderson, B. ( 2014). Neuroendocrinology of the hair follicle: Principles and clinical perspectives. *Trends Molecul. Med.* **20(10)**: 559-570.

Purushothaman, M.R., Thiruvenkadan, A.K., Karunanithi, K. and Balasundaram, K. (2010). Skin thickness, histology and leather traits of Mecheri sheep. *Indian Vet. J.* **87**: 60-62.

Saleemm Ronak, S., Habeeb Mahdi., A., Abdullah. (2016). Comparative histological study of the skin layers of black goats in north Iraq. AL-Qadisiyah. *J. Vet. Med. Sci.* **15(2)**: 25-30.

Sumena, K.B., Lucy, K.M., Chungath, J.J., Kuttinarayanan, P. and Ashok, N. (2012). Regional histology of stratum lucidum of epidermis in Large White Yorkshire pigs. *J. Vet. Anim. Sci.* **43**: 24-26.