Haryana Vet. (March, 2020) **59(SI),** 109-111

Short Communication

HISTOPATHOLOGICAL AND IMMUNOHISTOCHEMICAL EVALUATION OF LEIOMYOSARCOMA IN DOG

SHREYA BAHL*, BABU LAL JANGIR and GULSHAN NARANG
Department of Veterinary Pathology, College of Veterinary Sciences
Lala Lajpat Rai University of Veterinary and Animal Sciences, Hisar-125004, India

Received: 17.07.2019; Accepted: 14.10.2019

SUMMARY

This study reports histopathological changes and immunohistochemical expression of alpha smooth muscle actin (α-SMA), pancytokeratin (PCK), vimentin, proliferating cell nuclear antigen (PCNA), Ki67 and cycloxygenase-2 (COX-2) in leiomyosarcoma in 5 years old male Labrador dog. An ulcerated irregular oval growth was observed at shoulder level. Microscopically, it revealed interlacing fascicles of muscle fibres with densely packed elongated nuclei and scanty cytoplasm. Mean values of mitotic and AgNOR counts were 12/high power field and 3.44/nucleus, respectively. On immunohistochemistry, it revealed diffused cytoplasmic staining for α-SMA in neoplastic cells which indicated its smooth muscle origin. Mild to moderate cytoplasmic staining for vimentin and no immunoreactivity for PCK in the neoplastic cells suggested mesenchymal origin of neoplastic cells. Proliferating neoplastic cells showed nuclear immunoreactivity for PCNA and Ki67. PCNA and Ki67 index was 75% and 4.1%, respectively. COX-2 immunoreactivity was noticed in cytoplasm of spindle shaped cells. It may be concluded that the immunohistochemical expression of vimentin and α-SMA in this case explained the mesenchymal and smooth muscle origin of tumour, respectively. Evaluation of mitotic and AgNOR counts, expression of PCNA, Ki67 and COX-2 indicated the malignancy potential and biological behaviour of leiomyosarcoma.

Keywords: Alpha smooth muscle actin, COX-2, Leiomyosarcoma, Proliferating cell nuclear antigen, Vimentin

Leiomyosarcoma accounts for 5-10% of soft tissue sarcomas. These are observed in the wall of the blood vessels, pili-erector muscles, smooth muscles of vagina, vulva, uterus, perianal skin etc. (Serin *et al.*, 2010; Lee *et al.*, 2013; Meuten, 2017). Dermal smooth muscle tumours occur most frequently in dogs, cats and ferrets. It is often difficult to differentiate with malignant fibrohistiocytoma, fibrosarcoma or benign Schwannoma because of similar histological features. Therefore, the various differentiating markers such as pancytokeratin (PCK), vimentin and alpha smooth muscle actin (α-SMA) are widely used for determining the origin of tumours. Cytokeratins (CKs) are the intermediate filament proteins which are present within the cytoplasm of all epithelial cells and their tumours. Likewise, vimentin is an intermediate filament protein normally expressed in mesenchymal cells. α-SMA is a cytosolic intermediate filament and it is a specific marker for smooth muscle differentiation (Meuten, 2017). Several proliferative tumour markers such as argyrophilic nucleolar organizer region (AgNOR) and mitotic counts, proliferating cell nuclear antigen (PCNA) and Ki67 are the important prognostic factors which are determinants of aggressiveness of a tumour (Meuten, 2017). COX-2 is induced in response to inflammatory stimuli and it has been implicated in genesis of numerous cancers and high expression of COX-2 in the tumours has been related to malignancy (Spugnini *et al.*, 2005). Keeping above facts in view, the present study was carried out with an objective to study the pathomorphological and immunohistochemical expression of α-SMA, vimentin, PCK, PCNA, Ki67 and COX-2 in leiomyosarcoma.

The present study was conducted on the tissue sample collected from a 5 years old male Labrador dog presented to Private Veterinary Clinics, Haryana with history of growth at shoulder level. Detailed gross examination was carried out. Then representative tissue sample was collected and fixed in 10% buffered formalin. After fixation, tissue was processed as per conventional method. Sections of 5-micron thickness were cut and stained with haematoxylin and eosin (H&E) and duplicate sections stained with Masson's trichrome (Luna, 1968). The area of the tumour section in H&E stained slides with highest overall mitotic activity was chosen for evaluation of mitotic count. Then total number of mitotic figures were counted in 10 high power fields (hpf) and expressed as average mitotic count/hpf (Romansik *et al.*, 2007). AgNOR count was performed as per the method described by Crocker *et al.* (1989). All the AgNOR dots scattered in the nucleus were considered for counting without resolving the intranuclear dots. It was counted in 100 consecutive nuclei and mean number of AgNOR dots per nucleus was calculated. Multiple serial sections of 3-4 micron thickness of formalin fixed tissues were cut and taken on glass slides coated with 3-aminopropyl-triethoxysilane. After deparaffinization in xylene (2 changes of 10 min each), the sections were rehydrated through descending grades of ethanol (100, 90, 70 and 50%) and then in distilled water. Antigen retrieval was done by microwave irradiation in a coplin jar containing 0.01M citrate buffer (pH 6.0) for 30 minutes. Quenching of endogenous peroxidise activity was performed by treating sections

*Corresponding author: shreyabahl@gmail.com

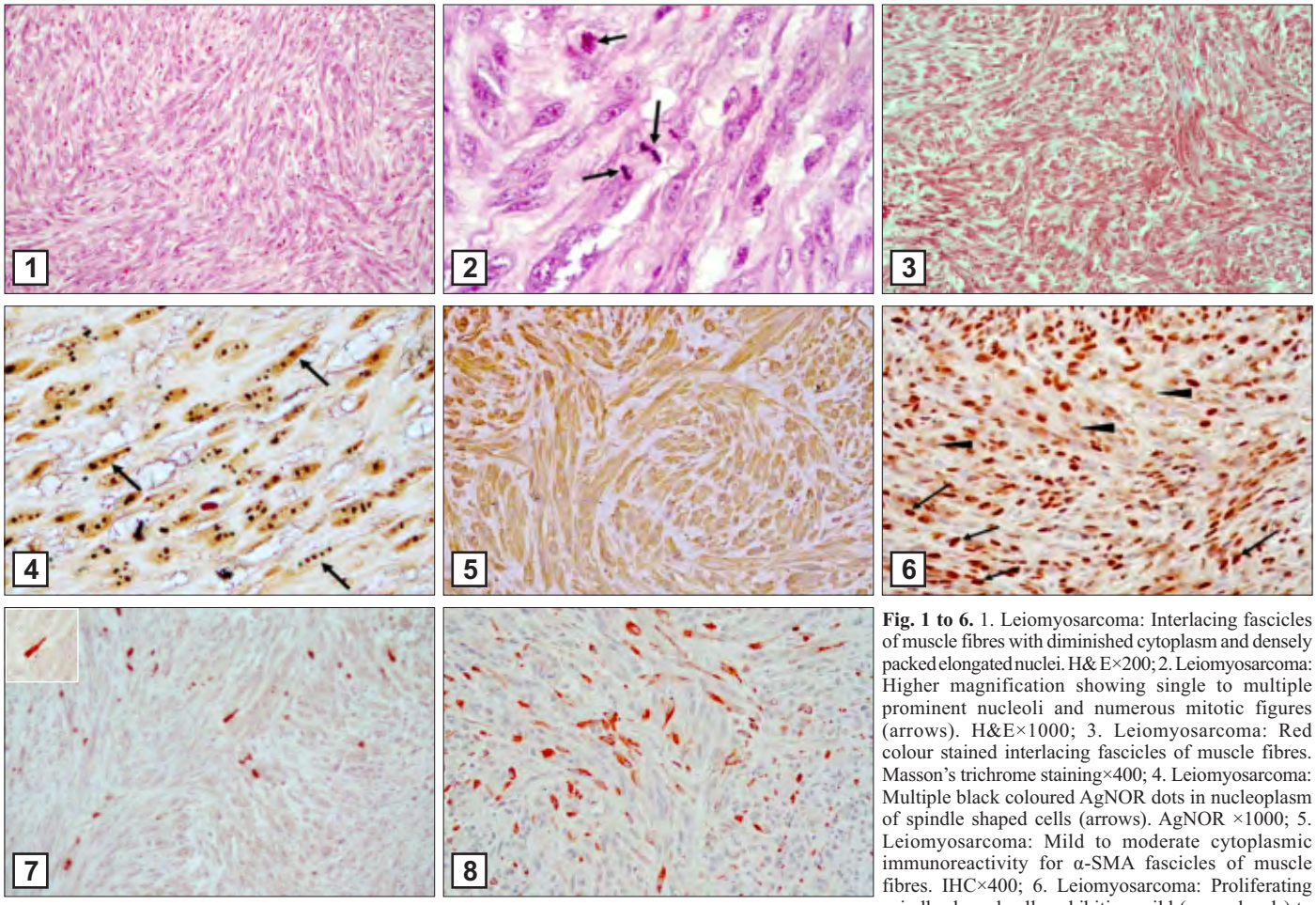

Fig. 1 to 6. 1. Leiomyosarcoma: Interlacing fascicles of muscle fibres with diminished cytoplasm and densely packed elongated nuclei. H& E×200; 2. Leiomyosarcoma: Higher magnification showing single to multiple prominent nucleoli and numerous mitotic figures (arrows). H&E×1000; 3. Leiomyosarcoma: Red colour stained interlacing fascicles of muscle fibres. Masson's trichrome staining×400; 4. Leiomyosarcoma: Multiple black coloured AgNOR dots in nucleoplasm of spindle shaped cells (arrows). AgNOR ×1000; 5. Leiomyosarcoma: Mild to moderate cytoplasmic immunoreactivity for α-SMA fascicles of muscle fibres. IHC×400; 6. Leiomyosarcoma: Proliferating spindle shaped cells exhibiting mild (arrow heads) to intense (arrows) nuclear immunostaining for PCNA. IHC×400

Fig. 7-8. 7. Leiomyosarcoma: Brick red Ki67 nuclear immunoreactivity in proliferating cells and enlarged view of Ki67 immunopositive cigar shaped nuclei (inset). IHC×200; 8. Leiomyosarcoma: COX-2 immunoreactivity in cytoplasm of spindle shaped cells. IHC×400

with 3% hydrogen peroxide (prepared in absolute methanol) for 15 min. The blocking of non-specific sites was done by 5% normal goat serum (Sigma Chemicals) prepared in phosphate buffered saline (PBS, pH 7.4) for 30 minutes. For different markers, immunostaining was done as per manufacturer's instructions with slight modifications. Primary mouse monoclonal antibodies i.e. anti- α SMA (clone 4A4, Novus biological), anti-pancytokeratin (clone PCK-26, Sigma), anti-vimentin (clone V9, Sigma), anti-PCNA (clone PC10, Sigma) were used at 1:400, 1:100, 1:400 and 1:400 dilutions, respectively. Primary rabbit monoclonal antibodies viz. anti-Ki67 (SP6) and anti-COX-2 (SP21) were used at dilutions of 1:25 and 1:50, respectively. Dilutions were prepared in 1% bovine serum albumin (BSA, Sigma Chemicals, USA) prepared in PBS (pH 7.4). Coloured reactions were developed by using 3-Amino-9-ethylcarbazole (Sigma Chemicals) as staining substrate and counter staining performed with Gill's haematoxylin (Sigma Chemicals). Negative and positive controls were used. Negative controls were treated with the diluents only. Reddish brown to yellowish brown staining in the cytoplasm of the neoplastic cell was considered positive immunostaining for α-SMA, vimentin, PCK, COX-2 while brick red or reddish brown nuclear staining in the neoplastic cells was considered as positive for PCNA and Ki67. Scoring of PCNA immunostaining was done according to the method described by Kumaraguruparan *et al.* (2006) based upon percentage of PCNA positive cells i.e. 0 for <5%, 1 for 5-25%, 2 for 26-50%, 3 for 51-75% and 4 for >75% positive cells. Scoring of Ki67 immunostaining was done according to Zuccari *et al.* (2004) based upon percentage of Ki67 positive cells i.e. 0 for no staining, 1 for <10%, 2 for 10-50% and 3 for >50% positive cells. Scoring for COX-2 immunostaining was done according to Heller *et al.* (2005) with slight modifications based upon percentage of COX-2 positive cells i.e. 0 for 0%, 1 for <10%, 2 for 10-30%, 3 for 31-60% and 4 for >61%. Presence of cytoplasmic immunoreactivity for PCK, vimentin and α-SMA in neoplastic cells regardless of the staining intensity was considered as positive.

A case of leiomyosarcoma was diagnosed in 5 years old male Labrador dog. Grossly, it revealed an irregularly oval and ulcerated growth of approximately 4 cm in diameter at the shoulder level. It was soft in consistency

and cut surface appeared pale to pink. Histologically, it was characterized by the presence of interlacing fascicles of muscle fibres with diminished cytoplasm and densely packed elongated nuclei (Fig. 1). Few nuclei were cigar shaped. Neoplastic cells revealed single to multiple prominent nucleoli and numerous mitotic figures (Fig. 2). Duplicate sections stained with Masson's trichrome exhibited red colour stained interlacing fascicles of muscle fibres (Fig. 3). These findings are in corroboration with that described by Meuten (2017). Multiple black coloured AgNOR dots were observed in the nucleoplasm of spindle shaped cells (Fig. 4). Average mitotic and AgNOR counts were 12.0/hpf and 3.44/nucleus, respectively. Mild to moderate immunoreactivity of vimentin indicated mesenchymal origin of this tumour. Spindle shaped neoplastic cells revealed diffused cytoplasmic immunoreactivity of SMA (Fig. 5). Mild to intense nuclear immunostaining for PCNA was observed in proliferating cells (Fig. 6) with 75% as PCNA index and PCNA score of 3. Brick red coloured Ki67 nuclear immunoreactivity was noticed in proliferating cells (Fig.7) with 4.1% Ki67 index and 1 as Ki67 score. Red coloured COX-2 immunore-activity was noticed in the cytoplasm of spindle shaped cells (Fig. 8) with 36.5% immunoreactive cells for COX-2. It was designated as COX-2 score of 3.

High mitotic count and AgNOR in this case indicated aggressiveness of the tumour. This is in agreement with Romansik *et al.* (2007) who reported that it is higher in malignant tumours than benign ones. This tumour showed positive cytoplasmic immunoreactivity for α-SMA and it indicated the smooth muscle origin of tumour. Positive immunoreactivity for vimentin and negative for PCK in neoplastic cells in present case indicated the mesenchymal origin of neoplastic cells. Similarly, Albertus *et al.* (2018) observed reaction of SMA and vimentin in urethral leiomyosarcoma. PCNA and Ki67 are the most common biomarkers which are used to evaluate cellular proliferation rate and analyzing the aggressiveness of a tumour for determining the prognosis of the tumour (Ozaki *et al.*, 2007 and Meuten, 2017). The strong positive immunoreactivity of PCNA in present study was similar to the findings of Leil *et al.* (2018) indicating the higher proliferating capacity of the tumour. However, the Ki67 index was 4.1% only. This may be attributed to short half life of Ki67 (Zuccari *et al.*, 2004). As COX-2 is an induced response to inflammatory stimuli and it has been involved in the genesis of numerous cancers (Spugnini *et al.*, 2005). COX-2 immunoreactivity observed in the spindle shaped cells in this case indicated the progression towards high malignancy. It may be concluded that along with routine histopathological examination, the estimation of mitotic index, AgNOR count and immunohistochemical expression of various tumour markers aids in determining the origin, biological behaviour of the tumour and hence appropriate diagnosis and prognosis of tumours.

REFERENCES

Albertus, J.C.C., Garcia, M.S., Moise, A., Navas, J.L.F., Manchado, E.M.J., Stonton, S. and Alonso, M.J.A. (2018). Urethral leiomyosarcoma in a bitch. *Isr. J. Vet. Med.* **73(2)**: 53-55.

Crocker, J., Boldy, D.A.R. and Egan, M.J. (1989). How should we count AgNORs. Proposals for a standardized approach. *J. Pathol.* **158(3)**: 185-188.

Heller, D.A., Clifford, C.A., Goldschmidt, M.H., Holt, D.E., Shofer, F.S., Smith, A. and Sorenmo, K.U. (2005). Cyclooxygenase-2 expression is associated with histologic tumor type in mammary carcinoma. *Vet. Pathol.* **42(6)**: 776-780.

Kumaraguruparan, R., Parthiba, D. and Nagini, S. (2006). Of humans and canines: Immunohistochemical analysis of PCNA, Bcl-2, p53, cytokeratin and ER in mammary tumours. *Res. Vet. Sci.* **81(2)**: 218-224.

Lee, K.C., Kim, M.S., Choi, H., Na, C.H. and Shin, B.S. (2013). Rapid growing superficial cutaneous leiomyosarcoma of the face. *Ann. Dermatol.* **25**: 237-241.

Leil, A.Z.A., Hallawany, H.A.E., Fadel, M.S., Elmesiry, A. and Elsayad, A. (2018). Electrosurgical excision and differential pathological diagnosis of external genital tumours in bitch. *Alex. J. Vet. Sci.* **57(2)**: 1-12.

Luna, L.G. (1968). Manual of Histologic Staining Methods of Armed Forces Institute of Pathology. (3rd Edn.), McGraw Hill Book Co., New York.

Meuten, D.J. (2017). Tumors in Domestic Animals. (5th Edn.), Wiley Blackwell.

Ozaki, K., Yamagami, T., Nomura, K. and Narama, I. (2007). Prognostic significance of surgical margin, Ki-67 and cyclin D1 protein expression in grade 2 canine cutaneous mast cell tumor. *J. Vet. Med. Sci.* **69(11)**: 1117-1121.

Romansik, E.M., Reilly, C.M., Kass, P.H., Moore, P.F. and London, C.A. (2007). Mitotic index is predictive for survival for canine cutaneous mast cell tumours. *Vet. Pathol.* **44(3)**: 335-341.

Serin, G., Aydogan, A., Yaygingul, R. and Tunca, R. (2010). Uterine leiomyosarcoma in a dog: a case report. *Veterinarni Medicina.* **55(8)**: 405-408.

Spugnini, E.P., Porrello, A., Citro, G. and Baldi, A. (2005). COX-2 over expression in canine tumors: potential therapeutic targets in oncology. *Histol. Histopathol.* **20(4)**: 1309-1312.

Zuccari, D.A.P.C., Santana, A.E., Cury P.M. and Cordeiro J.A. (2004). Immunocytochemical study of Ki-67 as a prognostic marker in canine mammary neoplasia. *Vet. Clin. Pathol.* **33(1)**: 23-28.