Haryana Vet. (March, 2020) **59(SI),** 14-19

Research Article

PREVALENCE OF UPPER RESPIRATORY TRACT AFFECTIONS IN THOROUGHBRED HORSES THROUGH RESTING ENDOSCOPY

O.S. GAJARLWAR*, R.V. SURYAWANSHI, A.H. ULEMALE, M.N. RANGNEKAR[1]and PHIROZ KHAMBATTA[2]
Department of Veterinary Surgery & Radiology, [1]Department of Animal Reproduction,
Gynaecology & Obstetrics, KNP College of Veterinary Science, Shirwal-412801, Satara, India
[2]Equine Hospital, Pune, India

Received: 06.03.2019; Accepted: 03.04.2019

ABSTRACT

A total of 166 endoscopic examinations were performed on 119 racing horses to diagnose upper respiratory tract affections in resting condition. Study was undertaken on privately owned horses reported to teaching veterinary clinical complex and in Pune, Mumbai and nearby regions of Maharashtra with chief complaint of progressive poor performance and recurrent respiratory symptoms. Diagnosis was made on the basis of history, clinical examinations, haemato-biochemical and endoscopic examinations. Out of 119 horses diagnosed with respiratory tract diseases, 49 were indicative of upper respiratory tract afflictions via - resting endoscopy and categorized as Dorsal displacement of soft palate (9; 18.36%); Guttural pouch affections (8; 16.32%); Recurrent laryngeal neuropathy grade-2 (7; 14.28%); Recurrent laryngeal neuropathy grade-4 (5; 10.20%); Recurrent laryngeal neuropathy grade-3 (4; 8.16%); Sinusitis (4; 8.16%); Pharyngeal lymphoid hyperplasia (4; 8.16%); Laryngitis (3; 6.12%); Pharyngitis (3;6.12%); Arytenoid chondritis (1; 2.04%) and Epiglottic entrapment (1; 2.04%). In present investigation, female were more often affected than males and showed overlapping clinical signs like coughing, abnormal respiratory noise and nasal discharge. Anamnesis, clinical appraisal and resting endoscopy findings were found to be a "gold standard" protocol for diagnosis and forecasting of various upper airway diseases in performing horses and immediate medical attention could be initiated to avoid further irreparable damage of upper respiratory tract and racing career of performing horses.

Keywords: Endoscopy, Epiglotic, Guttural pouch, Recurrent laryngeal hemiplegia

Horses are considered to be elite athletes because of their unique pulmonary physiology. Even tenuous changes in their health can significantly affect performance. The respiratory system is a highly specialized organ system that exchanges large volumes of air in and out of the lungs per minute. Owners push their competitive horses beyond their physiological limit during the training and during a race that leads to structural and functional alterations and considering the complexity of the upper respiratory tract, it is no surprise that dysfunction is so common (Rachel *et al.*, 2005).

Dynamic upper respiratory tract collapse is a common cause of poor performance in horses primarily through obstruction of airway (Franklin, 2008). Respiratory diseases are result of exposure to dust, airborne irritants, bacteria, molds, and ammonia characterized by excess nasal discharge, coughing, sneezing and mucus secretion (Gerard and Wikins, 2015). Elizabeth and Benson (2003) identified 40% to 42% of respiratory diseases in racehorses presented for poor performance evaluation, revealing that dorsal displacement of the soft palate was the most commonly identified respiratory disorder, affecting 29% to 35% of racehorses. They also found laryngeal hemiplegia (17% to 24%)and pharyngeal collapse (27%) in performing horses during endoscopy. Endoscopy facilitates visualization of inaccessible areas of the pharynx, larynx, guttural pouches and trachea (Ducharme, 2012; Gerard and Wikins, 2015).

Therefore, the present study was carried out to evaluate the prevalence of various afflictions of upper respiratory tract and to diagnose upper respiratory tract disorders by endoscopy in performing horses.

MATERIALS AND METHODS

Selection of horses: Total 119 racing horses were presented to equine hospital with chief complaints of respiratory disorders like exercise intolerance, nasal discharge and coughing. All the horses were stabled in well ventilated housing system with paddy straw bedding materials. In the present study, 73 horses undergoing more than 3 hours of work showed frequent respiratory noise and exercise intolerance whereas remaining 46 horses that underwent less than 3 hours of work had mild symptoms of respiratory distress were also screened endoscopically. Horses diagnosed for upper respiratory tract abnormalities via resting endoscopy were used as clinical material duly approved by the Institutional Animal Ethics Committee.

Clinical and Physical examination: All horses were housed in closed stables in racing premises and showed common clinical symptoms like coughing, exercise intolerance, nasal discharge and lacrimation during routine track work or during training period. The vital parameters such as heart rate, pulse rate, respiratory rate and rectal temperature were recorded in the reported horses. Physical examination like palpation were carried out to rule out

*Corresponding author: omkargajarlwar@gmail.com

nasal asymmetry, throat pain on palpation, consistency and color of nasal discharge, lung auscultation, epistaxis etc. at initial stage of screening.

Haemato-biochemical evaluation: About 5-6 ml of blood was drawn from jugular vein for haemato-biochemical analysis like haemoglobin, total leukocyte count, total erythrocyte count, differential leukocyte count and packed cell volume and biochemical parametrs such as serum creatine kinase (IU/L); ALT (IU/L); AST (IU/L) and lactate dehydrogenase (IU/L) were estimated if required during the present study.

Preparation of horses for resting endoscopy: Prior to endoscopic evaluation, each horse was restrained with nostril twitch in the stable. Vicious horses were sedated with Inj. Xylazine Hydrochloride @ 1.1mg/kg body weight intravenously to mediate their long term examination of upper respiratory tract. The effect of xylazine on epiglottis, laryngeal cartilage and soft palate were also kept in mind during endoscopic evaluation of upper respiratory tract disorders and was correlated accordingly during the course of present study.

Resting Endoscopic Evaluation: All 119 racing horses underwent resting endoscopic examination of upper respiratory tract with help of flexible fibre optic endoscope (Karl Stronz, Germany) with outer diameter of 13.3 mm, 3.2 mm working channel and 168 cm working length. Halogen light was used as light source. Endoscopy and related accessories such as cytology brush and biopsy brush were cleaned thoroughly during examination of each horse with 2% glutaraldehyde solution to prevent cross contamination. Grading system was used to evaluate the status of arytenoid cartilage as well as pharyngeal lymphoid hyperplasia in all horses (Table 1).

Statistical Analysis: The clinical data obtained from present study were analysed by using WASP-2 software and different tests like unpaired t-test, ANOVA and descriptive statistical analysis was carried out.

RESULTS AND DISCUSSION

Out of 119 examinations, 49 (41.18%) thoroughbred horses were found to be affected with upper respiratory tract afflictions (Table 2) and remaining 70 (58.82%) horses showed lower respiratory tract diseases with overlapping clinical manifestations (Table 3) and they were excluded from present study. Nasal twitch and mild sedation with Xylazine Hydrochloride found to be more effective method of restraining for URT endoscopy in stabled horse. Similar study was performed by Morris and Seeherman, 1991 who concluded that, about 40-42% of racehorses presented for evaluation of poor performance were found suffering with upper respiratory tract abnormalities and thoroughbred horses (67%) were highly susceptible to abnormal respiratory noise. All horses were housed in closed stables with paddy straw bedding and showed common clinical symptoms like coughing, exercise intolerance, nasal discharge and lacrimation during routine clinical examination and these findings were in correlation with Pusterla *et al.*, 2006 who recommended that, the approach to horses with respiratory diseases begins appropriately with careful and systemic investigation.

Table1

Endoscopic grading system for Laryngeal and Pharyngeal Lymphoid Hyperplasia (PLH) in Resting Horses

Grades	Movement of arytenoid cartilage (Hackett *et al.*, 1991)	Appearance of Pharyngeal Lymphoid tissue (Raker and Boles, 1978)
Grade 0	Synchronous full abduction and adduction of the left and right arytenoid cartilages	A few small white follicles over the dorsal pharyngeal wall
Grade 1	Asynchronous movement (hesitation, flutter, adductor weakness) of the left arytenoid cartilage during any phase of respiration. Full abduction of the left arytenoid cartilage is (as compared to the right) inducible by nasal occlusion or swallowing.	Mainly small white follicles with occasional larger pink follicles over the dorsal pharyngeal wall and extending laterally to the level of the guttural pouch ostia
Grade 2	Asynchronous movement (hesitation, flutter, adductor weakness) of the left arytenoid cartilage during any phase of respiration. Full abduction of the left arytenoid cartilage cannot be induced and maintained by nasal occlusion or swallowing	Pink and white follicles covering the entire dorsal and lateral pharyngeal walls and often also involving the dorsal surface of the soft palate
Grade3	Asymmetry of the larynx at rest and no substantial movement of the left arytenoid cartilage during any phase of respiration	Large pink, oedematous follicles covering all visible mucosa of the pharynx and sometimes including polyps
Grade 4	By laryngeal asynchrony or asymmetry not included in any one of the previous grades	

Table 2

Prevalence of upper respiratory tract (URT) abnormalities in performing horses examined endoscopically

S.No	URT abnormalities	No of examination	Mean age (Years)	Body weight (kg)	Sex distribution			Total 1	Prevalence (%)
					Colt	Filles	Gelding		
1	Arytenoid Chondritis (AC)	1	3.00±0.00	480.00 ± 0.00	-	-	1	1	2.04
2	Recurrent Laryngeal Neuropathy (RLN):Grade-2	7	5.28±1.52	442.80 ± 6.92	1	5	1	7	14.28
	Recurrent Laryngeal Neuropathy (RLN):Grade-3	4	3.50±0.25	471.25 ±9.41	-	4	-	4	8.16
	Recurrent Laryngeal Neuropathy (RLN):Grade-4	5	4.25±0.39	452.00 ±7.71	-	3	2	5	10.20
3	Laryngitis	3	4.33±1.83	440.00 ±10.02	2	1	-	3	6.12
4	Pharyngeal Lymphoid Hyperplasia (PLH)	4	8.75±2.63	445.00 ±13.23	1	3	-	4	8.16
5	Pharyngitis	3	14.00±00	450.00±21.27	-	3	-	3	6.12
6	Dorsal displacement of Soft Palate (DDSP)	9	3.57±0.16	444.45±5.46	-	2	7	9	18.36
7	Epiglottic Entrapment (EE)	1	4.00±00	475.00±0.00	1	-	-	1	2.04
8	Sinusitis	4	4.67±0.47	472.50±10.68	2	-	2	4	8.16
9	Guttural Pouch affections (GP)	8	3.84±1.31	462.22±0.00	2	6	-	8	16.32
			Total Horses reported		9	27	13	49	

Table 3

Clinical symptomatology and distribution of horses with respiratory tract afflictions and managemental conditions in present study (n=128)

S.No	Variables	Categories	Common clinical symptoms recorded	Number	Prevalence (%)
1	Housing system	Stable	Coughing, nasal discharge, ocular discharge, Respiratory noise and distress, coughing	128	100
		Paddock	-	-	-
2	Ventillation	Adequate	Nasal discharge, coughing, lacrimation	67	52.34
		Inadequate	Dull condition, respiratory noise	61	47.65
3	Bedding material	Straw	Respiratory distress and noise, coughing, High respiratory rate, coughing.	128	100
4	Duration of training	≤1 hour	Mild respiratory noise, coughing, nasal discharge	29	22.65
		≥ 1 hour	Exercise intolerance, coughing, nasal discharge	99	77.34
5	Exercise	≤ 3 days	Mucus nasal discharge, coughing while work	55	42.96
	(days per week)	≥ 3 days	Exercise intolerance, respiratory noise	73	57.03
6	Sex	Female	Coughing, nasal discharge, respiratory noise	89	69.53
		Male	Respiratory noise, dull, high respiration, coughing	39	30.46

Clinical parameters such as heart rate (33.30±0.33/min), pulse rate (34.12±0.23/min), respiratory rate (22.93±0.41/min) and rectal temperature (37.12±0.07°C) did not vary significantly in presented horses with varied upper respiratory tract affections. No alterations in levels of haemoglobin (12.67 ± 0.17 g/dL), packed cell volume (32.89±0.53 %) and red blood cell (7.09±0.06 million/cmm) were observed in present study. The mean average values of serum aspartate transferase (224±6.67 IU/L), alanine transferase (15.22±0.59 IU/L), lactate dehydrogenase (272.23±9.89 IU/L) and creatinine kinase (136.33±6.53 IU/L) in horses suffering with varied upper respiratory tract affections were within normal range. McGowan (2008) also studied the physiological and

Fig. 1. DDSP with Apical Ulcers on soft Plalate

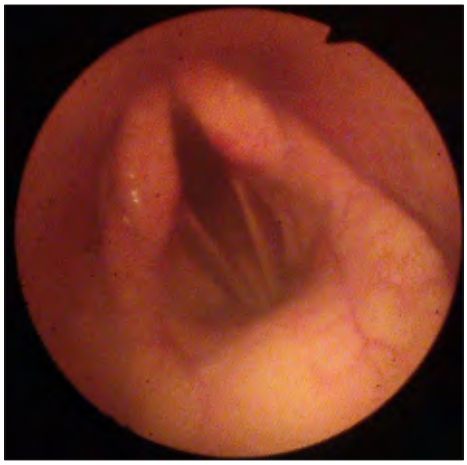

Fig. 2. Grade-3 Left Laryngeal Hemiplegia characterized by asymmetry of Larynx

Fig. 3. Grade-4 LRH with comple Asynchrony ans Asymmetry of Larynx

Fig. 4. Retroversion of glottis and elevation of soft Palate

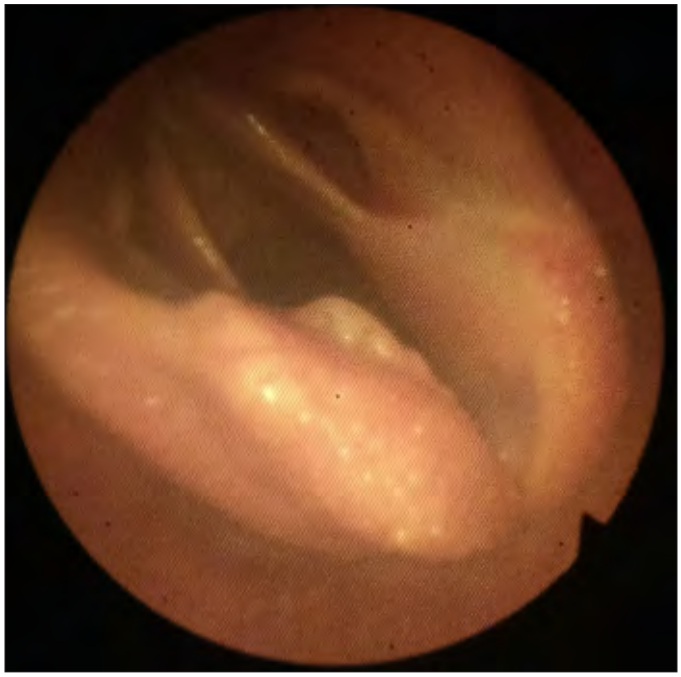

Fig. 5. Arytenoid Chondritis on left arytenoid cartilage

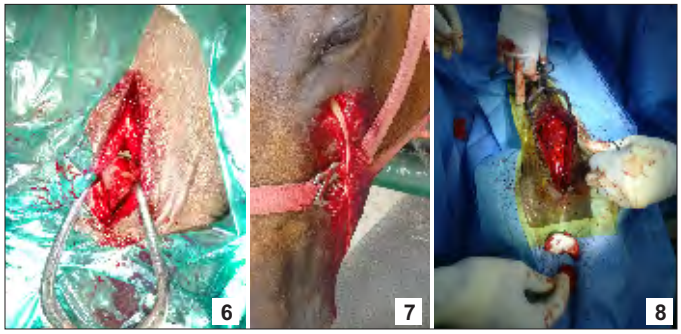

Fig. 6. Horse with Arytenoid chondritis underwent partial arytenoidectomy; Fig. 7. Horse with severe sinusitis treated successfully with antibiotic flush; Fig. 8. Laryngeal tie foreward procedure for DDSP affected horses

haemato-biochemical parameters in performing horses and conclude that, there were non-significant changes in blood profile.

Six, out of 8 horses had a muco-pus in guturrhal opening, characterized by profuse purulent discharge oozing from the guttural pouch opening which caused inspiratory distress and coughing reflexes whereas remaining two horses showed mycosis infection and had a blood tinged nasal discharge with dyspnoea. Similar findings were recorded via resting endoscopy by Hardy and Leveille (2003) in their study and they concluded that guttural pouch infection in younger horses was due to fungal or bacterial infection with profuse yellowish nasal discharge. Nine out of 49 horses had a dorsal displacement of soft palate in the present study characterized by poor visualization of soft palate, bellowing of soft palate during exhalation, laxity of soft palate and apical ulcers on soft palate (Fig. 1) during rest as reported previously by various workers (Barakzai and Dixon, 2011).

Seven horses showed grade-2 left laryngeal hemiplegia (LLH), arytenoid movement was observed for synchronised and symmetrical adduction and abduction

with transient asynchrony or delayed abduction of arytenoid cartilage. Four horses had grade-3 left laryngeal hemiplegia, characterised by asymmetry of larynx (Fig. 2), no substantial movement of left arytenoid cartilage was observed whereas remaining five horses showed complete asymmetry and asynchrony of larynx with dropped left recurrent laryngeal cartilage indicating grade-4 left laryngeal neuropathy (Fig. 3).

In present study, the exact cause of recurrent laryngeal neuropathy was unknown and it could be due to trauma to the recurrent laryngeal nerve which causes flaccidity of laryngeal cartilage (Semeco *et al.*, 2011). Movements of laryngeal cartilage during rest via endoscopy play an important role to assess degree or grade of arytenoid cartilage symmetry and movement as per recommendation of Woodie, 2011. One horse showed retroversion into the glottis and elevation of soft palate endoscopically (Fig. 4), which indicates entrapment of epiglottis that causes abnormal respiratory noise in performing horses (Franklin, 2008).

Three horses had pharyngitis as evident by inflammation and redness of pharynx along with history of frequent coughing whereas one horse showed arytenoid chondritis (Fig. 5) on left arytenoid cartilage which was removed surgically (Fig. 6) under general anaesthesia. The present finding is in corroboration with Sinclair (2008), who reported redness and inflammation in pharyngitis. In present study, one horse showed chondritis changes over left arytenoid cartilage which could be due to colonization of various bacteria in accordance with Ducharme (2012).

Out of 49, seven horses showed grade-2 laryngeal hemiplegia and they were kept under observation and further progress of disease periodically. Horses affected with laryngitis, pharyngitis and pharyngeal lymphoid hyperplasia were treated symptomatically with fluticasone and amikacin nebulisation till complete recovery and responded well to medication after one week. The present findings is collaborated with Neumeister and Reinertson (1982) who treated horses suffering with laryngitis and pharyngitis with fluticasone and amikacin nebulisation for 5-7 days. Four horses with sinusitis were treated successfully with regular lavage of the sinus (Fig. 7) with normal saline on daily basis or till the symptoms disappear clinically and similar therapy was recommended (Dixon *et al.*, 2011) for management of acute sinusitis in horses.

In present study, eight horses with guttural pouch infection were treated successfully with antibiotic flushing in accordance with Hardy and Leveille (2003). Among 4, one horse showed grade 1 pharyngeal lymphoid hyperplasia and remaining 3 horses showed grade 2 PLH and this was in affirmation with Woodie (2011) who, stated that, PLH lesions are commonly observed in young horses during routine endoscopic evaluation and will subside after horses gained complete immune status.

Nineteen horses (38.78%) were prepared aseptically for surgical correction of various upper respiratory affections and general anaesthesia was achieved with help of triple drip protocol consisting of Inj. Xylazine @1.1mg/kg; Inj. Ketamine @ 2.2mg/kg and Inj. Guisefensin intravenously whereas nine horses with grade-3 and 4 recurrent laryngeal hemiplegia were corrected with Prosthetic Laryngoplasty followed by Ventriculocordectomy procedure as suggested by Lumsden *et al.* (1994).

Remaining nine horses with dorsal displacement of soft palate underwent for laryngeal tie forward (Fig. 8) procedure as a corrective method to avoid recurrence of displacement of soft palate dorsally as followed by Cheetham *et al.* (2008). Postoperatively, all horses received Inj. Dicryticine- 5gm intramuscularly and Inj. Phenylbutazone-10ml intravenous route for 5 days. Owners or trainers were advised for routine observation of all horses like clinical signs, recovery and physical activities on daily basis.

The present study concluded that, the incidence of upper respiratory tract abnormalities were common malady in performing horses and can be detected via endoscopy in early stage. Among URT abnormalities, left laryngeal recurrent neuropathy and dorsal displacement of soft palate was most frequently encountered maladies. Faulty ventilation and dusty bedding material used in stable predisposes the occurrence of respiratory problems in thoroughbred horses which can be manageable with routine medical treatment. Early endoscopic diagnosis of upper respiratory tract abnormalities was gold standard approach in young stock to prevent irreparable damage and to improve the performance of horses on racing track.

ACKNOWLEDGEMENT

The authors duly acknowledge the respected Dr. A.S. Ranade, Associate Dean, KNP College of Veterinary Science, Maharashtra Animal and Fishery Sciences University for permitting us to complete the present work at Pune and Mumbai race course.

REFERENCES

Barakzai, S.Z. and Dixon, P.M. (2011). Correlation of resting and exercising endoscopic findings for horses with dynamic laryngeal collapse and palatal dysfunction. *Equine Vet. J.* **43**:18-23.

Cheetham, J.C., Pigott, J.H. and Thorson, L.M. (2008). Racing performance following the laryngeal tie-forward procedure: a case- controlled study. *Equine Vet. J.* **40**(5): 501-507.

Dixon, P.M., Parkin, T.D. and Collins, N. (2011). Equine par nasal sinus disease: a long-term study of 200 cases (1997-2009): treatments and long-term results of treatments. *Equine Vet. J.* **10**: 2042-3306.

Ducharme, N.G. (2012). Pharynx. In: Stick Equine Surgery. 4th Edn. Elsevier Saunders, Missouri. US. pp: 569-591.

Elizabeth, J.D. and Benson, B.M. (2003). Diagnosis of upper respiratory tract diseases in the performance horse. *Vet. Clin. Equine.* **19**: 51-62.

Franklin, S.H. (2008). Dynamic collapse of the upper respiratory tract: A review, *Equine Vet. Edu.* **20**(4): 212–224.

Gerard, P.M and Wikins, A.P. (2015). Respiratory tract. In: Equine Emergency and Critical Care Medicine. Southwood, L.L. and Wilkins, P.A. (Edts.). Boca Raton, Florida, United States: CRC Press; Abingdon, UK. pp. 253-303.

Hackett, R.P., Ducharme, N.G. and Fubini, S.L. (1991). The reliability of endoscopic examination in assessment of arytenoid cartilage movement in horses Part 1: Subjective and objective laryngeal evaluation. *Vet. Surg.* **20**: 174-179.

Hardy, J. and Leveille, R. (2003). Diseases of guttural pouches. *Vet. Clin. Equine.* **19**: 123-158.

Lumsden, J.M., Stick, J.A. and Caron, J.P. (1994). Surgical treatment for epiglottic entrapment in horses: 51 cases (1981-1991). *J. Am. Vet. Med. Assoc.* **205**: 729-735.

McGowan, C. (2008). Clinical pathology in racing horses: the role of clinical pathology in assessing fitness and performance in the racehorse. *Vet. Clin. Equine.* **24**: 405-421.

Morris, E.A. and Seeherman, H.J. (1991). Clinical evaluation of poor performance in the racehorse: the results of 275 evaluations. *Equine Vet. J.* **23**: 169-174.

Neumeister, M.L. and Reinertson, E.L. (1982). Pharyngeal Lymphoid Hyperplasia. *Iowa State University Veterinarian*. **44**: 4-6.

Pusterla, N., Watson, J.L. and David, W. (2006). Diagnosis approach to infectious respiratory disorders. *Clin. Tech. Equine. Pract.* **5**:174-186.

Rachel, H.H., Dowling, B.A. and Dart, A.J. (2005). High speed treadmill video-endoscopy examination of the upper respiratory tract in the horses: the results of 291 clinical cases. *Vet. J.* **170**: 243-248.

Raker, C. and Boles, C.L. (1978). Pharyngeal Lymphoid Hyperplasia in the horse. *Equine Med. Surg.* **2**: 202-207.

Semeco, E., Rodriguez, M., Basola, A., Aranguren, J and Fernandez, M. (2011). Prevalence of upper respiratory tract diseases in thoroughbred racehorses. *Rev. Client.* **21**: 215-223.

Sinclair, E.A. (2008). Pharyngeal cyst in a 5 year old Dutch warm blood. *Can. Vet. J.* **49**(8): 806-808.

Woodie, J.B. (2011). Evaluation of the upper respiratory tract at rest and during exercise. In Depth: Respiratory. Rood and Riddle Equine Hospital. *Lexington.* pp. 1-4.