

## A CASE REPORT ON CLINICO-PATHOLOGICAL DIAGNOSIS, PROGNOSIS AND TREATMENT OF NASAL TUMOURS IN DOGS

SUJATA TURKAR\*, GURPREET SINGH PREET, NEETU SAINI, SUSHMA CHHABRA and S. DESHMUKH

Department of Veterinary Medicine,  
Guru Angad Dev Veterinary and Animal Sciences University, Ludhiana-141004, India

Received: 25.07.2020; Accepted: 28.08.2020

### SUMMARY

Primary neoplasms of the nasal cavity, paranasal sinuses and nasopharynx are rare in the dogs. A four years old Labrador retriever dog with history of inappetence, facial swelling, noisy breathing and another four years old Pug dog with unilateral epistaxis were presented to the Teaching Veterinary Hospital of Guru Angad Dev Veterinary and Animal Sciences University, Ludhiana. Nasal cytology from Labrador revealed angular, cytoplasmic basophilia with increased cohesiveness in an acinar pattern, indicative of nasal adenocarcinoma, whereas in Pug, many typical round cells with presence of discrete cytoplasmic vacuolation and eccentric nuclei was observed and confirmed the extra-genital form of transmissible venereal tumour (TVT). The dog with adenocarcinoma succumbed to death due to massive spread of neoplasia in the nasal cavity, whereas, the dog with nasal TVT was successfully treated with Vincristine sulphate @ 0.025 mg/kg b.wt. at weekly interval for three weeks.

**Keywords:** Adenocarcinoma, Dogs, Nasal tumour, Nasal transmissible venereal tumour

Tumours of the nasal cavity and paranasal sinuses comprises less than 1% of canine neoplasms. Nasal adenocarcinoma occurs more frequently than sarcomas in canines (Rassnick *et al.*, 2006). Most of these tumours are malignant and associated with a poor prognosis. This case report presents diagnosis, management and prognosis of nasal cavity tumours in two dogs.

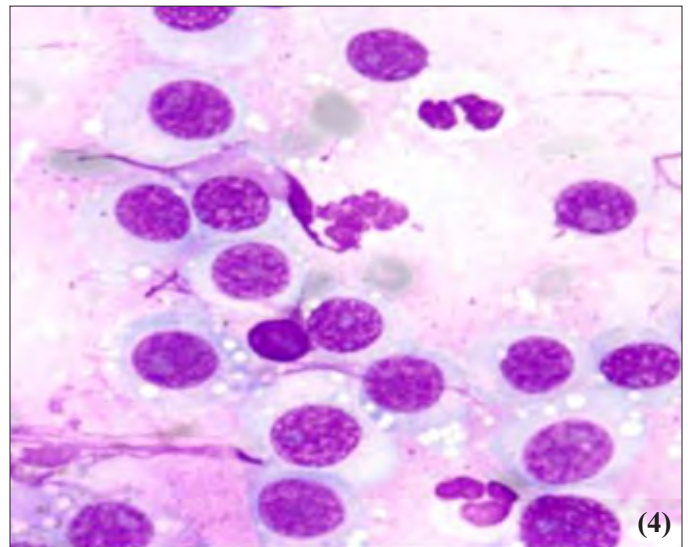
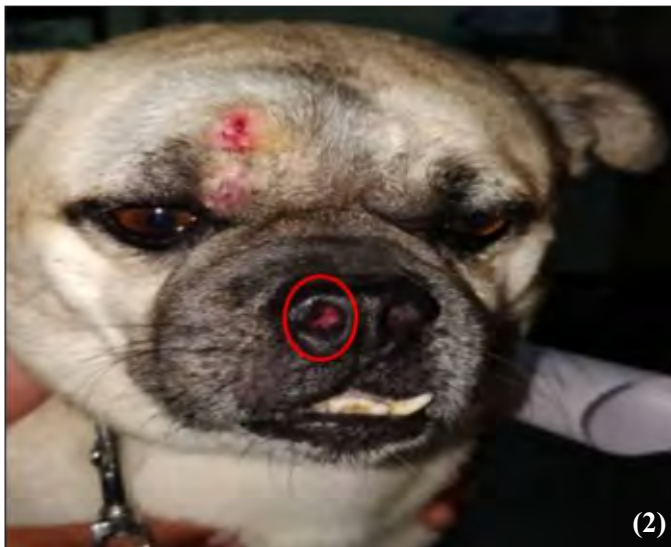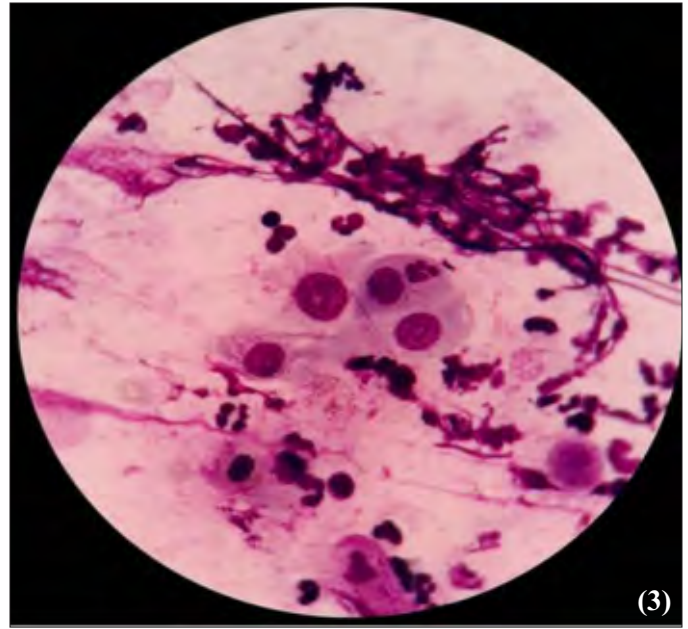
A four years old Labrador dog was presented with the history of inappetence, facial swelling and noisy breathing for last one month. Detailed clinical examination of the dog revealed dyspnea, stertorous respiratory sound, massive oedematous maxillary and mandibular swelling (Fig. 1), very thick salivary secretion, enlarged bilateral prescapular lymph nodes and normal body temperature and mucus membrane. The hematological parameters revealed neutrophilic leukocytosis [Total leucocyte count (TLC): 18750/ $\mu$ L, Neutrophils: 92%, Lymphocytes: 08%] with toxic changes. Blood biochemistry revealed hypoproteinemia (serum total protein: 4 g % and serum albumin: 2.2 g %). Radiography of nasal cavity and neck showed diffuse soft tissue density in neck and pharynx region. On cytological examination, many small clusters of angular to rounded epithelial cells possessing moderate anisokaryosis with evident nucleolar prominence and cytoplasmic vacuolation in few cells forming a putative acinar pattern was seen (Fig. 3) and tentatively suggested adenocarcinoma of nasal cavity. The dog was immediately treated with IV fluids (Inj. DNS 5% 500 ml), antibiotics (Inj. Clindamycin @ 10 mg/kg IM and Metronidazole @ 10 mg/kg IV), Diuretic (Inj. Furosemide @ 2 mg/kg, IM), corticosteroid (inj. Prednisolone @ 1 mg/kg, IM) and multivitamin (Inj. Polybion @ 2 ml, IM). The dog succumbed to death after 24 hours of initial

treatment but before initiation of chemotherapy.

Another four years old Pug dog was presented with the history of unilateral epistaxis for last four months. Detailed clinical examination of dog revealed normal vital parameters and ulcerated mass in right nostril (Fig. 2). Hematology showed neutrophilic leukocytosis (TLC: 18460/ $\mu$ L, Neutrophils: 90%, Lymphocytes: 10%) with toxic changes. Blood smear examination for hemoprotozoan parasites was negative. Radiography of nasal cavity showed diffuse soft tissue density in right nostril. The suspected cytological preparation assumed for TVT originated from nasal mucosal surface was subjected to Leishman staining. Based on microscopic observation, typical cells of rounded outline with varying presence of discrete cytoplasmic vacuolation and characteristic nuclear eccentricity was observed (Fig.4), which is a distinguished feature for TVT. The dog was successfully treated with Inj. Vincristine sulphate @ 0.025mg/kg b.wt. intravenously at weekly interval for three weeks.

Nasal adenocarcinoma are primary tumours of the respiratory epithelium covering the respiratory portion (maxilla-turbinates, ethmo-turbinates, naso-turbinates and nasal septum) of the nose, which causes death by local invasion; metastasis is rare. Unfortunately, early diagnosis and treatment is difficult to accomplish because clinical signs appear only after the tumour is fairly well advanced (Worley, 2016). Clinical signs associated with intranasal tumours consist of unilateral or bilateral nasal discharge, epistaxis, non-healing ulcer on the nasal planum, deformation of the nasal planum and nose, ocular discharge (Worley, 2016). Dogs with an intranasal mass may also experience discomfort on palpation of the nose and face and have sleeping disturbances

\*Corresponding author: sujataturkar@gmail.com



**Figs. 1 to 4.** (1) Massive facial swelling due to nasal adenocarcinoma in a Labrador dog; (2) An ulcerated mass in right nostril in Pug; (3) Cytology of nasal adenocarcinoma showing cells of epithelial origin in an acinar pattern having angular borders possessing highly active chromatin materials in nucleus with cytoplasmic granularity within cells and cell aggregates surrounded by some poly morphonuclear cells and fibrinous materials (Leishman Staining, x100). (4) Cytology of nasal TVT showing round to oval neoplastic cells with characteristic eccentric nuclei, discrete and punctate vacuoles in the basophilic cytoplasm and few neutrophils around (Leishman Staining, x100).

ranging from restlessness to interrupted sleep due to obstructed breathing. Some dogs with neoplastic obstruction of the air passages do not adapt to open mouth breathing even at rest (Lux *et al.*, 2017). Similar clinical signs were also seen in present patients. Although, the clinical signs in these dogs were most consistent with upper airway obstruction but definitive diagnosis requires the complementary examinations such as radiography, cytological examination of nasal swab and histopathology. This report reaffirms the importance of specifically cytological examination of nasal swab for diagnosis of neoplasia in routine clinical practice. The first patient exhibited a prolonged period of respiratory distress and massive facial swelling, whereas second patient

showed a prolonged period of epistaxis and visible growth in nasal cavity. It is important to note the significance of clinical signs and detailed anamnesis; however, the cytological examinations are important for establishing differential diagnosis. In these cases, the patients received several different treatments for a number of months by local field veterinarians and delayed diagnosis might have reduced the survival chances in intranasal tumors, especially adenocarcinoma. Hematological findings in both cases were indicative of marked neutrophilic leukocytosis and lymphopenia owing to immunosuppression, leading to secondary bacterial invasion. In the first case, hypoproteinemia and hypoalbuminemia were due to malnutrition and

wasting condition in conjunction with the disease.

In general, arriving at confirmatory diagnosis of intranasal neoplasm with malignant potential is quite difficult, as it needs certain criteria to be fulfilled and there are high numbers of cells, irregular chromatin structure, increased ratio of the nucleus to cytoplasm and mitotic index (Cowell *et al.*, 1999). Resembling close to these criteria, there are other conditions where cytological variations differ with hairline breadth features, thus making differentiation a bit difficult. Secondary hyperplastic and dysplastic changes of the epithelial tissue are mostly surrounded with inflammatory and necrotic changes and are the few changes which offer little help in diagnosis of such cases. So, in the present case, the cytology of nasal samples revealed inflammatory cells, with variable sized angular epithelial cells containing activated chromatin materials in nucleus. There is usually enough exfoliation in carcinomas. However, in this case, a moderate degree of exfoliation was noted with mucous secretions. Unlike to this, round cell tumour(s) like lymphosarcomas, mastocytomas and transmissible venereal tumours possess high cellularity and their cells exfoliate in confluent manner. The case of Pug dog clearly falls within the category of round cells as TVT, as it contained numerous cells with rounded contour having plentiful of distinct cytoplasmic vacuolation margins (Knotek *et al.*, 2001).

Concerning the first case, nasal adenocarcinoma is considered locally aggressive and invasive, with a poor prognosis. Resolution was not always successful given that the treatment chosen and administered was palliative, not curative, due to the advanced stage of the neoplasia. Similar observation was reported by Solorzano *et al.* (2003) in a clinico-pathological study of nasal adenocarcinoma. Whereas for nasal TVT, chemotherapy is considered the most effective and practical method and vincristine sulphate is the drug of choice that is commonly employed. Vincristine, a plant alkaloid, is a chemotherapeutic agent and exerts cytotoxic activity by disrupting cellular microtubule formation. This sequence induces the inhibition of cell replication, including the replication of the

cancer cells. The TVT treatment consists of the weekly administration of vincristine at a dosage of 0.5 to 0.7 mg/m<sup>2</sup> of body surface area for a period of 4-8 weeks. Turkar *et al.* (2018) also found the similar result in therapeutic management of nasal TVT.

Canine nasal neoplasia represents a challenge for the clinician given their poor prognosis and the poor response to treatment, since the majority of cases are diagnosed in their final stages. Therefore, the fate of animals with nasal tumours clearly depends on the early and precise diagnosis, type and stage of tumour. In the present study, the case of nasal adenocarcinoma had an unfortunate fatal end just because of end stage diagnosis of advanced neoplastic growth within nasal passages, whereas nasal transmissible venereal tumour had better outcome with chemotherapy.

## REFERENCES

- Cowell, R.L., Tyler, R.D. and Meinkoth, J.H. (1999). *Diagnostic Cytology and Hematology of the Dog and Cat* (2<sup>nd</sup> Edn.), Mosby, St. Louis, pp. 52-58.
- Knotek, Z., Fichtel, T., Kohout, P. and Benak, J. (2001). Diseases of the nasal cavity in the dog. aetiology, symptomatology, diagnostics. *Acta Vet. Brno.* **70**: 73-82.
- Lux, C.N., Culp, W.T.N., Johnson, L.R., Kent, M., Mayhew, P., Daniaux, L.A., Carr, A. and Puchalski, S. (2017). Prospective comparison of tumor staging using computed tomography versus magnetic resonance imaging findings in dogs with nasal neoplasia: a pilot study. *Vet. Radiol. Ultrasound.* **58**: 315-325.
- Rassnick, K.M., Goldkamp, C.E., Erb, H.N., Scrivani, P.V., Njaa, B.L., Gieger, T.L., Turek, M.M., McNeil, E.A., Proulx, D.R., Chun, R., Mauldin, G.E., Phillips, B.S. and Kristal, O. (2006). Evaluation of factors associated with survival in dogs with untreated nasal carcinomas: 139 cases (1993-2003). *J. Am. Vet. Med. Assoc.* **229**(3): 401-406.
- Solorzano, I.B., Mayagoitia, A.L. and Tavera, F.J.T. (2003). Clinico-pathological study of six dogs with nasal carcinoma and adenocarcinoma: diagnosis and treatment. *Vet. Mex.* **34**(1): 81-95.
- Turkar, S., Saini, N. and Sood, N.K. (2018). Cytological diagnosis of rare primary extragenital transmissible venereal tumours in dogs. *Intas. Polivet.* **19**(2): 428-429.
- Worley, D.R. (2016). Nose and nasal planum neoplasia, reconstruction. *Vet. Clin. North. Am. Small Anim. Pract.* **46**: 735-750.