

OCCURRENCE OF VARIOUS PATHOLOGICAL CONDITIONS IN LUNGS OF PIG

SEEMA MEENA¹, RAMHARI MEENA², MANISHA MEHRA³ and MANISHA MATHUR³¹Teaching Associate Pashu Vigyan Kendra, Kota-324007, India²Veterinary Officer, Veterinary Hospital, Undwa (Kota)-326519, India³Department of Veterinary Pathology, College of Veterinary and Animal Sciences, RAJUVAS, Bikaner-334001, India

Received: 24.06.2022; Accepted: 06.10.2022

ABSTRACT

In the present investigation a total of 385 specimens of lungs of pig were investigated for various pathological conditions. During this period, specimens of lungs of pig, suspected for abnormalities were examined irrespective of age, sex and breeds in Bikaner and Jaipur, Rajasthan. Out of these 385 specimens, 158 specimens were suspected for abnormalities (34 Circulatory disturbances, 37 Abnormalities of inflation 81 Inflammatory conditions, 6 Miscellaneous condition), grossly. These were further processed for histopathological examination to find various pathological conditions.

Keywords: Histopathological examination, Lungs, Pathological conditions, Pig

How to cite: Meena, S., Meena, R., Mehra, M. and Mathur, M. (2023). Occurrence of various pathological conditions in lungs of pig. *The Haryana Veterinarian* 62(1): 60-63.

The pigs with high prolificacy, efficient mothering ability, rapid growth, most economic feed conversion efficiency, shorter gestation period and high dressing percentage (65-80) are rated as one of the best meat producing animal in world (Das and Bujarbaruah, 2005). In India the current goal for pig industry is to produce high quality lean meat at low cost which will play an important role in improving socio-economic status of pig rearing farmers (Das and Bujarbaruah, 2005). Respiratory diseases are major health problems in growing swine throughout the world including India. Moreover, the establishment of secondary infections in these animals and the increase in the treatment costs and death of animals are additional economic losses (Ostanello *et al.*, 2007). A wide range of pathological conditions are common in lungs of pig such as congestion, haemorrhage, oedema, atelectasis, emphysema, abscess, bronchointerstitial pneumonia, bronchopneumonia, haemorrhagic pneumonia, interstitial pneumonia, suppurative pneumonia, catarrhal pneumonia, pleuritis, bronchitis, bronchiectasis, bronchostenosis, haemosiderin pigmentation etc (Gidey *et al.*, 2014). In Rajasthan, so far very little efforts have been made to study the occurrence of various pathological conditions in lungs of pigs. Therefore, it becomes pertinent to study the lungs affections in pigs.

The materials for the present study consisted of tissue samples of lungs collected from various slaughter houses and from private piggery farms located in and around Bikaner and Jaipur district of Rajasthan. A total of 385 pigs of either sex and of different age groups were examined in detail and lung samples were collected for the study. During slaughter, the samples were thoroughly

examined grossly for alterations in morphology, in shape, size, colour, consistency, location and present of cyst, tumor and abscess etc. lesions in individual part of lungs. Tissue pieces from portions of lungs were collected in 10% buffered formalin for histopathological examination. The samples were processing by routine paraffin embedding using acetone and benzene technique (Lillie, 1965) and sections of 4-5-micron thickness were cut and stained by Harris Hematoxylin and Eosin method (Luna, 1968). These were further proceeding for histopathological examination.

RESULTS AND DISCUSSION

The present study was carried out from November, 2017 to November, 2018. During this period a total number of 385 specimens of lungs of pig were collected from various slaughter houses and private piggery farms. Out of these specimens 158 lungs were suspected for abnormalities grossly. These were further processed for histopathological examination to find various pathological conditions. An overall incidence of various pathological conditions of lungs of pig was reported as 41.03 % cases and circulatory disturbances in 21.51% cases, abnormalities of inflation in 23.41% cases, inflammatory conditions in 51.26% cases and miscellaneous conditions in 3.79% cases (Table 1). Whereas the incidence of pneumonia was found to be 49.36% cases of the total affected lungs.

Table 1. Various pathological conditions in lungs of pig

Sr. No.	Type of condition	No. of cases	Percentage
A	Circulatory disturbances	34	21.51%
B	Abnormalities of inflation	37	23.41%
C	Inflammatory conditions	81	51.26%
D	Miscellaneous conditions	6	3.79%

*Corresponding author: dr.ram1005@gmail.com

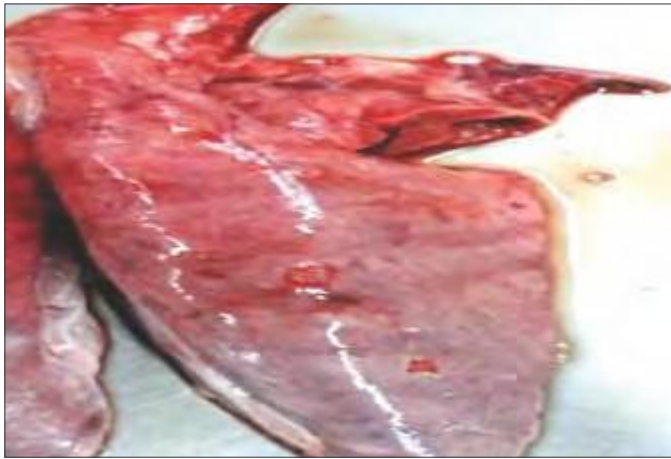

Fig. 1. Gross photograph showing congestion in lungs

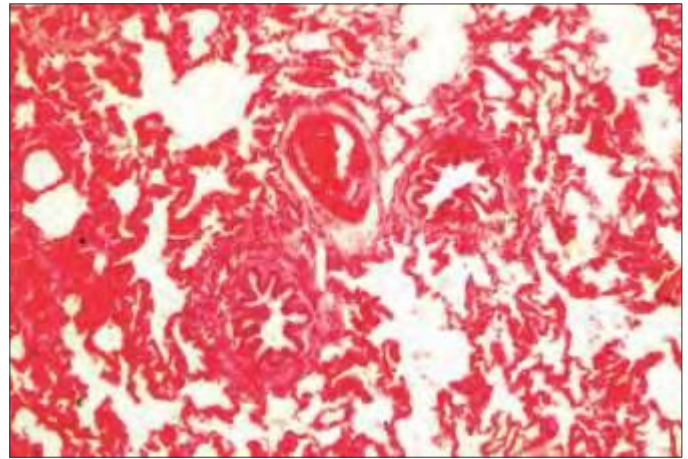


Fig. 2. Microphotograph showing congestion (H&E, 10x)

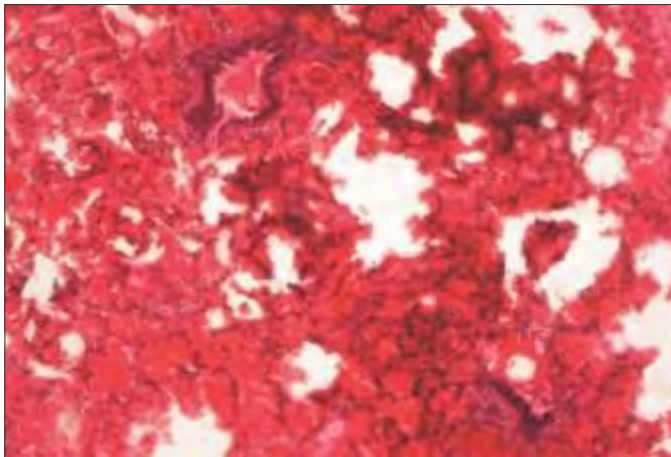


Fig. 3. Microphotograph showing hemorrhage (H&E, 10x)

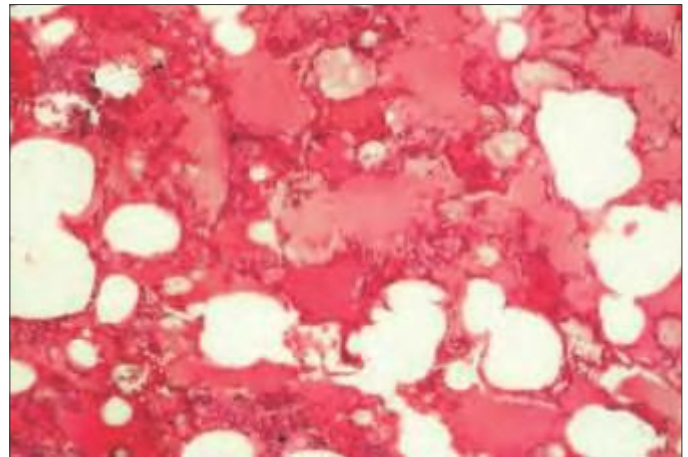


Fig. 4. Microphotograph showing edema in lungs (H&E, 10x)

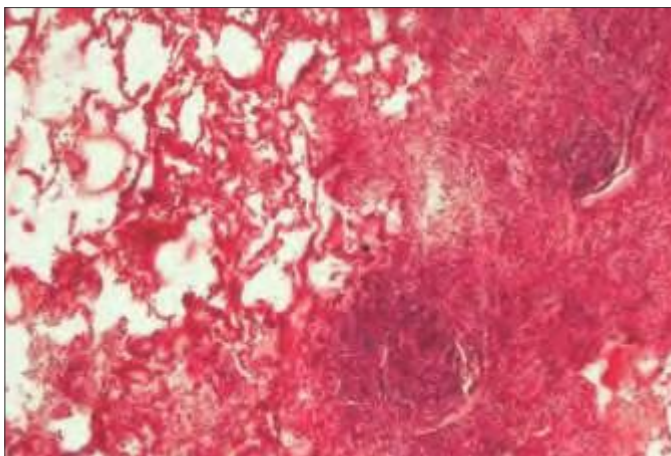


Fig. 5. Microphotograph showing abscess in lungs (H&E, 10x)

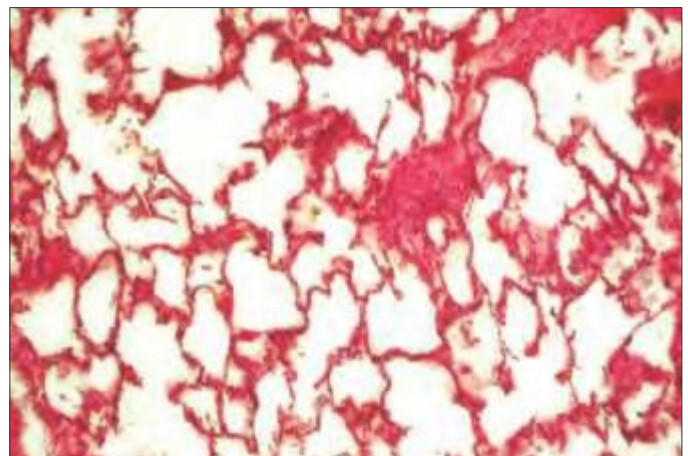


Fig. 6. Microphotograph showing emphysema in lungs (H&E, 10x)

Pulmonary congestion was recorded in 14 (8.86 %) cases of the total affected lungs. This was similar with earlier report of 7.89% by Belkhiri *et al.* (2009). However, the incidence observed was higher compared to the findings of Sreevidya (2017) because the incidence of lesions depends on various factors such as the difference in environmental conditions, managerial practices and health status of the different age group of flocks. Grossly,

the affected lungs were enlarged with areas of severe congestion and diffuse areas of bright red colour (Fig. 1). Microscopically, around the bronchi and bronchioles, the blood vessels in the interlobular septa, were greatly dilated and engorged with blood (Fig. 2). Both gross and microscopic findings are in concurrence with observations of Belkhiri *et al.* (2009). Pulmonary hemorrhage was recorded in 9 (5.69 %) cases of the total affected lungs. The

incidence observed was lower compared to the findings of Rajao *et al.* (2013) and slightly higher than the findings of Sreevidya (2017). Grossly, the lung showed ecchymoses to diffuse area of dark red colour. Microscopically, large blood areas were seen (Fig. 3). Oedema was observed in 6 (3.79 %) cases of the total affected lungs. This was similar with earlier report of 3.75% by Akbor *et al.* (2007). Gross findings of oedema are in close approximation with the finding recorded by Jones and Hunt (1983) who found that if a watery fluid exudes, perhaps a little tinged with blood the lung tissue distended and of firm consistency, the condition is oedema and Microscopically, various oedematous parts showed pink stained homogenous serous fluid in alveoli along with peribronchial severe congestion in blood vessels (Fig. 4). These findings are similar with Akbor *et al.* (2007).

Pulmonary abscess was observed in 5 (3.16%) cases of the total affected lungs. Comparatively lower incidence of 1% was recorded by Fablet *et al.* (2011) because the incidence of lesions depends on various factors such as the difference in environmental conditions, managerial practices and health status of the different age group of flocks. Gross, finding of pulmonary abscess are in close approximation with the finding recorded by Sarkar and Bhattacharya (1975), who found that the affected lung showed varying sizes abscesses located beneath the pleura and affected lung parenchyma was raised, thick, rough and microscopically, young abscess surrounded by a zone of acute inflammation and contained yellowish detritus (Fig. 5).

Pulmonary emphysema was seen in 13 (8.22%) cases of the total affected lungs. However, a lower incidence of 2.55% and 0.66% was recorded by Gidey *et al.* (2014). Gross findings of emphysema are an agreement with McGavin and Zachary (2007) who found that the affected areas of lung were unduly distended with air, slightly raised as compared to the surrounding tissues, yellow white in colour, puffy in consistency and crepitant. Microscopically, distended alveoli were seen that were forming giant alveoli in some areas by coalescence and the neighbouring areas revealed atelectic foci. Many alveoli were irregularly distended. The above findings are in concurrence with observations of Rashid *et al.* (2013) (Fig. 6). Atelectasis was present in 24 (15.18%) cases of the total affected lungs. A lower incidence of 5.03% was recorded by Belkhiri *et al.* (2009). Grossly, the affected area was shrunken and slightly depraved as compared to the surrounding tissue and was bluish red in colour, cut surface was smooth, dry and leathery in consistency and no fluid squeezed out from it. The above findings are in concurrence with observations of Jones and Hunt (1983). Microscopically,

the alveoli were collapsed and the alveolar septa appeared small elongated irregular cleft making the interstitial tissues prominent without any inflammation. The bronchioles were also collapsed and had constricted satellite shaped lumen which an agreement with the findings of McGavin and Zachary (2007).

In the present study, 78 (20.25%) cases of pneumonia were observed out of 385 pig lungs examined. Various survey carried out on lung lesions in pig by earlier authors showed variation in the incidence of pneumonia and was reported as 61.71% (Lavanya *et al.*, 2011) and 3.87% (Sreevidya, 2017). The higher incidence of pneumonia recorded in the present study compared to the incidences reported previously in India might be due to variation in the age, location, season, managerial practices and causes of pneumonia. Pleuritis was observed in 1 (0.63%) cases of the total affected lungs. A higher incidence 13.6% was reported by Fablet *et al.* (2011). Grossly, thickened pleura with glistening surface was seen which was hard to cut and microscopically, the pleura was edematous and the parenchyma of lung show purulent exudate along with infiltration of mononuclear cells Bronchitis was observed in 2 (1.26%) cases of the total affected lungs. A higher incidence of 16.7%, was reported by Cappuccio *et al.* (2018).

Bronchiectasis was in 3 (1.89 %) cases of the total affected lungs. Comparatively lower incidence of 0.41% was recorded by Buri (2017). On microscopic examination, bronchiectasis having narrowing of bronchial lumen and these structures were seen to consist of a dense hyaline proteinaceous material within the lumina of bronchiectatic bronchi along with congestion, microabscess and severe infiltration of polymorphonuclear and mononuclear cells. Bronchostenosis was recorded in 2 (1.26 %) cases of the total affected lungs with comparatively lower incidence of 0.41% (Buri, 2017).

CONCLUSION

The present investigation concluded that the different circulatory disturbances in lungs were demonstrated with various pathological conditions encountered. Almost all the gross and microscopic observations on various lungs affections were in close conformity with the findings of earlier workers.

REFERENCES

- Akbor, M., Haider, M.G., Ahmedullah, F., Khan, M.A.H. N.A., Hossain, M.I. and Hossain, M.M. (2007). Pathology of trachea and lungs of buffaloes. *Bangl. J. Vet. Med.* **5(1&2)**: 87-91.
- Das, A. and Bujarbarush K.M. (2005). Pig for meat production. *Ind. J. Anim. Sci.* **75(12)**: 448-452.

- Belkhiri, M., Tlidge, M., Benhathat, Y. and Meziane, T. (2009). Histopathological study and pulmonary classification of bovine lesions. *Afri. J. Agri. Res.* **4(7)**: 584-591.
- Buri, (2017). Occurrence and pathology of various conditions of respiratory system in sheep, M.V.Sc. thesis, submitted to Rajasthan University of Veterinary and Animal Sciences, Bikaner, Rajasthan, India.
- Cappuccio, J.A., Dibarbora, M. and Bessone, F.A. (2018). Evaluation of pig pneumonia at slaughter using polymerase chain reaction and histopathology in Argentina. *J. Swine Health Prod.* **26(6)**: 304-308.
- Fablet, C., Dorenlor, V., Eono, F., Eveno, E., Madec, F. and Rose, N. (2011). Prevalence of macroscopic lung lesions in slaughter pigs in France. In: animal hygiene and sustainable livestock production. Proc. of the XVth Intern. Congress of the *Intern. Soc. for Anim. Hygiene, Vienna, Austria.* **1**: 47-49.
- Gidey, H.S., Seleshe, N. and Debebe, D. (2014). Major causes of organ and carcasses condemnation in swine slaughtered at Addis Abeba municipal abattoir. *African J. Basic Appl. Sci.* **6(3)**: 76-81.
- Jones, T.C. and Hunt, R.D. (1983). Veterinary pathology. (5th Edn.), Lea and Febiger, Philadelphia.
- Lavanya, K., Ramadevi, V. and Srilatha, C.H. (2011). Pneumonia in pigs. A pathomorphological study. *Indian J. Vet. Pathol.* **35(2)**: 206-208.
- Lillie, R.D. (1965). Histopathological technique and practical histochemistry. Mc-Gh London. Lipatov, S.A., Kwon, Y.K., Sarmiento, V.L., Lager, M.K., Spackman, E., Suarez, D.L., Swayne, D.E. Domestic pigs have low susceptibility to H5N1 highly pathogenic avian influenza viruses. *PLoS Pathog.* **4(7)**: e1000102.
- Luna, L.G. (1968). Manual of Histological staining methods of the Armed Forces Institute of Pathology, (3rd Edn.), McGraw Hill Book Co., NewYork.
- McGavin, M.D and Zachary, J.F. (2007). Pathologic basis of veterinary diseases. (4th Edn.), pp. 463-538.
- Ostanello, F., Dottori, M., Gusmara, C., Leotti, G. and Sala, V. (2007). Pneumonia disease assessment using a slaughterhouse lung-scoring method. *J. Vet. Med.* **54**: 70-75.
- Rajao, D.S., Couto, D.H., Gasparini, M.R., Costa, A.T.R., Reis, J.K.P., Lobato, Z.I.P., Guedes, R.M.C. and Leite, R.C. (2013). Diagnosis and clinic-pathological findings of influenza virus infection in Brazilian pigs. *Pesquisa Veterinária Brasileira.* **33(1)**: 30-36.
- Rashid, M.M., Ferdoush, M.J., Dipti, M., Roy, P., Rahman, M.M., Hossain, M.I. and Hossain, M.M. (2013). Bacteriological and pathological investigation of goat lungs in Mymensingh and determination of antibiotic sensitivity. *Bangl. J. Vet. Med.* **11(2)**: 159-166.
- Sarkar, P. and Bhattacharyya, H.M. (1975). Caprine pneumonia caused by *Corynebacterium ovis*. *Indian J. Anim. Hlth.* **14**: 5-6.
- Sreevidya (2017). Pathological studies on spontaneous lesions in slaughtered pigs. M.V.Sc. thesis submitted to Sri Venkateswara Veterinary University, Tirupati, Andhra Pradesh, India.

THE HARYANA VETERINARIAN

Editors/Editorial Board Members are highly thankful to all the distinguished referees who helped us in the evaluation of articles. We request them to continue to extend their co-operation and be prompt in future to give their valuable comments on the articles for timely publication of the journal.