

## MANAGEMENT OF DYSTOCIA DUE TO *SCHISTOSOMA REFLEXSUS* MONSTER IN BEETAL GOAT - A CASE REPORT

DEEPAK<sup>1\*</sup>, HANUMAN PRASAD YADAV<sup>1</sup>, SANDEEP<sup>2</sup> and UMED SINGH<sup>1</sup>

<sup>1</sup>Department of Veterinary Gynaecology and Obstetrics, <sup>2</sup>Department of Veterinary Parasitology, International Institute of Veterinary Education and Research, Rohtak-124 001, Haryana, India

Received: 28.07.2022; Accepted: 14.10.2022

### SUMMARY

A case of dystocia associated with malpresentations and atypical *Schistosoma reflexus* monster with ankylosed limbs was delivered through per-vaginal manual traction (fully relaxed cervix) in a Beetal doe.

**Keywords:** Ankylosed, Beetal doe, Dystocia, *Schistosoma reflexus*, Visceral organ

**How to cite:** Deepak, Yadav, H.P., Sandeep and Singh, U. (2023). Management of dystocia due to *Schistosoma reflexus* monster in beetal goat - A case report. *Haryana Vet.* 62(1): 158-159.

*Schistosomus reflexus* (SR) is seen most commonly in cattle (Jana and Ghosh, 2001; Kumar *et al.*, 2016a), but rare in goats (Hashemnia *et al.*, 2013; Kumar *et al.*, 2016b), sheep and swine (Roberts *et al.*, 1971). The highest prevalence of *Schistosomus reflexus* is believed to occur in cattle ranging from a low of 0.01% (Sloss and Johnston, 1967) to a high of 1.3% (Knight, 1996) of bovine dystocia. *Schistosomus reflexus* is a significant congenital anomaly that occurs during embryonic development. The etiology is unknown but it may be due to genetic factors, mutation, chromosomal anomalies, infectious agents and environmental factors, or a combination of all the factors (Ozsoy *et al.*, 2009; Ravikumar *et al.*, 2013). The primary defect is acute angulations of the vertebral column such that the tail lies close to the head. This fatal congenital syndrome is characterized by exposed abdominal and sometimes thoracic viscera (Kumar *et al.*, 2020). The present case report describes dystocia due to *Schistosomus reflexus* in a Beetal doe and its successful management through per-vaginal manual traction of a male kid.

A 3-years-old Beetal doe in its second parity with a body condition score of 3.5 (Scale of 1 to 5), presented with a history of full-term gestation, straining for the last five hours, and water bag ruptured before presented to Veterinary Clinical Complex, International Institute of Veterinary Education and Research (IIVER), Bahu Akbarpur, Rohtak-124001, Haryana, India. An increase in pulse and respiration rate was observed, however rectal temperature was normal. Per-vaginal examination revealed a dead fetus in anterior longitudinal presentation and dorso-sacral position with the fore limb in the birth canal (Fig. 1). This was astonished to note that an abnormally large size foetus was palpated and obstructed the birth canal.

The animal was restrained in right lateral position on the handling table (Fig. 1). The perineal region was

cleaned with potassium permanganate (1:1000). The gynaeco-clinical examination was done under epidural anesthesia (2 ml, 2% lignocaine HCl) after sufficient lubrication of the birth canal through liquid paraffin.

A monster foetus was palpated inside the uterus through per-vaginal examination which was unable to deliver without any assistance. The genital tract was lubricated with liquid paraffin. After that, the male kid was delivered per-vaginal by mild traction with hand on the fore limbs and head along with simultaneous adjustment of other foetal parts. The kid was appearing exposed to all visceral organs in the thoracic-abdominal area ruptured (Fig. 2), both ears were normal and hairs were present all over the body. The goat was stabilized with fluid therapy comprised of Inj. DNS (5%) @ 500 ml, I/V, Single dose, (Facmed Pharma), Inj. Mifex @ 50 ml) half I/V and half S/C, single dose (Novartis), Inj. Fortivir- LA (Enrofloxacin) @ 200.0 mg, I/M, single dose, repeated after 72 hr, (Virbac), Inj. Melonex (Meloxicam) @ 15.0 mg, I/M, single dose for three days, (Intas), Inj. Anistamin (Chlorpheniramin maleate) - @20.0 mg, I/M, single dose for three days, (Intas), and Boli-Furex (Nitrofurazone 60 mg + Urea 6 g) @ 2, Intrauterine, single dose, (Vetsfarma). The placenta was expelled within three hrs after traction. After one week postpartum, the animal was normal and healthy.

The gross morphological observation of the fetus revealed that there was severe ankylosis of fetal limbs (Ravikumar *et al.*, 2013), angulated lumbar region, and thoracic region (Fig. 2). Though the thoracic region was fully developed, the sacrum was under developed, the diaphragm was incomplete, the lungs were atrophied and congested abdominal viscera *viz.* stomach, intestines, liver, etc were protruding out of the abdominal cavity (Yadav *et al.*, 2017).

Based on the presentation *Schistosomus reflexus*

\*Corresponding author: drdeepakvet1998@gmail.com



Fig. 1. Beetal doe in right lateral position at the examination table

can be grouped into two categories i.e., visceral presentation in which fetal viscera are lying in the birth canal or protruding from the vulva and extremities presentation in which all four limbs or either of two limbs are present in the birth canal. Most of the literature concerning *Schistosomus reflexus* in cattle revealed extremities presentation (Kalita *et al.*, 2004; Sharma *et al.*, 2017). However, in the present case, the visceral organs along with the water bag protruding from the vulva confirmed the visceral presentation (Yadav *et al.*, 2017). The right cause of these teratological defects is still not known but the preliminary analysis of associated etiology may inform that *Schistosomus reflexus* has a genetic etiology. Murine gene mutations producing severe ventral body wall defects associated with anomalies of internal organs and other structures have been implicated in causing this condition (Laughton *et al.*, 2005). The condition is common in cattle and buffaloes (Srivastava *et al.*, 1998; Kumar *et al.*, 2016b; Dutt *et al.*, 2019) and can be corrected either by fetotomy or caesarean section and if the fetus is smaller than normal size and fully relaxed cervix then it can be delivered manually (Periyannan *et al.*, 2022).

#### ACKNOWLEDGEMENT

Authors thank the Dean, International Institute of Veterinary Education and Research (IIVER), Rohtak, Haryana and Director of VCC, Department of Veterinary Gynaecology and Obstetrics for providing necessary facilities to carry out this case study.

**Conflict of Interest:** All authors declare no conflict of interest.

#### REFERENCES

Dutt, R., Singh, G., Jasmer, Chandolia, R.K. (2019). Delivery of a *Schistosomus reflexus* monster through caesarean section in a Murrah buffalo. *Buffalo Bulletin*. **38(1)**: 165-168.

Hashemnia, M., Asadi, J., Kish, G.F. and Javdan, M. (2013). A rare case of *Schistosomus reflexus* in a goat. *Online J. Vet. Res.* **17(12)**: 685-690.

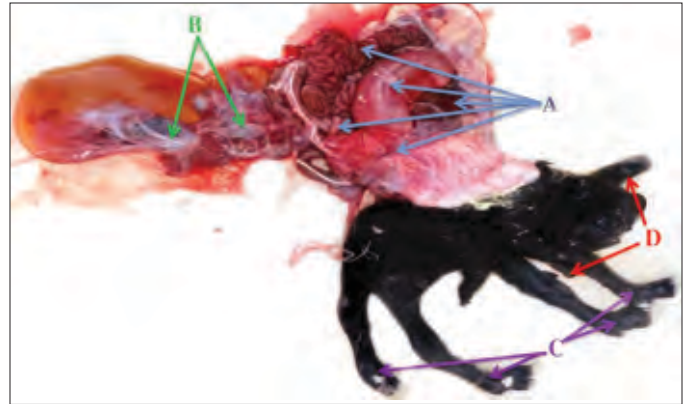


Fig. 2. *Schistosomus Reflexus* Kid (A) Visceral organ out side the body through thoraco-abdominal region: Rumen, liver, small and large intestine and spleen (B) Placenta attached to visceral organ (C) Ankylosed all limbs (D) Normal both ears.

Jana, D. and Ghosh, M. (2001). Dystocia due to fetal monster with *Schistosomus reflexus* ectopic viscera - A case report. *Indian Vet. J.* **78**: 333-334.

Kalita, D., Bhuyan, Mukit, A. and Islam, D. (2004). Dystocia due to *Schistosomus reflexus* in a goat. *Indian J. Anim. Reprod.* **61(1)**: 76-77.

Knight, R.P. (1996). The occurrence of *Schistosomus reflexus* in bovine dystocia. *Australian Vet. J.* **73**: 105-107.

Kumar, B., Yadav, D., Vandana and Saxena, A. (2016a). *Schistosomus reflexus* in a goat- A case report. *The riogenol. Insight.* **6(3)**: 119-121.

Kumar, B., Yadav, D., Vandana and Saxena, A. (2016b). A typical *Schistosomus reflexus* with multiple congenital abnormalities in Haryana cow. *The riogenol. Insight.* **6(3)**: 123-125.

Kumar, P., Sasi G., Satish., Prakash B., Mehra R., Sultan T. and Shafiullah. (2020). Dystocia due to *Schistosomus reflexus* in a Marwari ewe. *Haryana Vet.* **59(2)**: 285-286.

Laughton, K.W., Fisher, K.R.S. and Partlow, G.D. (2005). *Schistosoma reflexus* syndrome: A heritable defects in ruminants. *Anat. Histo. Embryo.* **34**: 312-318.

Ozsoy, S.Y., Oto, C. and Hazroglu, R. (2009). *Schistosoma reflexus* in dog. *Ankara Univ. Vet. Fak Derg.* **56**: 225-226.

Periyannan, M., Senthilkumar, K., Gawhane, A.S., Selvaraju, M., Manokaran, S., Palanisamy, M. and Ravikumar, K. (2022). Rare incidence of *Schistosomus reflexus* and its successful pervaginal delivery in a Mecheri ewe. *The Pharma Innov.* **11(5)**: 539-541.

Roberts, S.J. (1971). *Veterinary Obstetrics and Genital Disease (Therio genology)*, (2<sup>nd</sup> Edn.) CBS Publisher and Distributors, New Delhi, India. pp. 36-68.

Ravikumar, K., Selvaraju, M., Kumarasen, A. and Sivaraman, S. (2013). *Schistosomus reflexus* in a Doe: A case report. *Shanlax Int. J. Vet. Sci.* **1(1)**: 30-31.

Sharma, A., Kumar, P., Sharma, A., Singh, M. and Bhardwaj, N. (2017). Dystocia due to *Schistosoma reflexus* in Jersey crossbred cow. *Indian J. Vet. Sci. Biotech.* **12(4)**: 91-92.

Sloss, V.E. and Johnston, D.E. (1967). The cause and treatment of dystocia in beef cattle in western Victoria. *Australian Vet. J.* **43**: 13-21.

Srivastava, K.K., Sharma, A.K., Ahlawat, S.P.S. and Maithy, S.K. (1998). *Schistosomus reflexus* with Perosomus elumbis in Holstein Friesian cow. *Indian J. Anim. Reprod.* **19(1)**: 75.

Yadav, H.P., Shah, N., Kumar, B. and Saxena A. (2017). Dystocia due to *Schistosoma reflexus* and its management through fetotomy: A case report. *Indian J. Vet. Sci. Biotech.* **13(1)**: 91-93.