

C-ARM GUIDED REMOVAL OF FOREIGN BODY IN A DOBERMAN DOG: A CASE REPORT

S. VIGNESHWARAN, S. KATHIRVEL¹, C. SARANYA¹, P. SANKAR¹ and S. DHARMACEELAN¹

Veterinary Clinical Complex, VCRI, Udumalpet,

¹Department of Veterinary Surgery and Radiology, VCRI, Namakkal
Tamil Nadu Veterinary and Animal Sciences University, Chennai 600 051, India

Received: 21.10.2021; Accepted: 06.01.2022

SUMMARY

A three month old male Doberman dog was presented with history of excessive salivation and regurgitation immediately after taking solid food for past two days. A palpable and freely movable solid mass was noticed on palpation of the esophagus. Radiography confirmed presence of foreign body in the cranial part of the esophagus. The animal was positioned in lateral recumbency under general anaesthesia. Under C-arm guided fluoroscopic imaging foreign body was grasped and the foreign body (bone piece) was removed. Early diagnosis and non-invasive removal of foreign body using C-arm fluoroscopy made animal uneventful recovery.

Keywords: C-arm, Dog, Foreign body

How to cite: Vigneshwaran, S., Kathirvel, S., Saranya, C., Sankar, P. and Dharmaceelan, S. (2023). C-Arm guided removal of foreign body in a doberman dog: A case report. *The Haryana Veterinarian* 62(SI): 139-140.

In veterinary medicine, esophageal foreign bodies are considered to be the common emergency life threatening presentation. An esophageal foreign body is said to be any ingested item that fails, to pass into the stomach after being swallowed. The most frequently reported foreign bodies in dogs were bones, raw hide, toys and balls, coins, towels, socks, plastic, nylon, dental chews and sharp objects like fishhooks (Luthi and Neiger, 1998). Removal of foreign body should be considered an emergency rescue procedure as if it remains for longer time may lead to risks like aspiration and esophageal wall injury due to pressure necrosis (Houlton *et al.*, 1985). C-Arm fluoroscopy provides a real time image and a freeze image which helps to localize the foreign body easily (Pandyan *et al.*, 2013). This present paper reports successful retrieval of esophageal foreign body under non-invasive fluoroscopic C-arm guidance in a Doberman dog.

A three month old male Doberman dog was presented to Veterinary Clinical Complex, Veterinary College and Research Institute, Namakkal with anamnesis of excess salivation and regurgitation immediately after taking solid food from past two days. General clinical examination revealed vital signs within normal range. Oral cavity examination revealed presence of no foreign body. On palpation of the esophagus revealed a palpable and freely movable solid mass. Radiography confirmed the presence of foreign body with increased radio density (Fig. 1). Since the foreign body was movable and with smooth edges oral retrieval was planned under the guidance of fluoroscopic C-arm (Fig. 2). The animal was positioned in lateral recumbency under intravenous general anaesthesia using diazepam at 0.5 mg per kg and propofol at 6 mg per kg body weight. Endotracheal intubation was done to maintain airway passage and to avoid the risk of aspiration. Under C-arm guided fluoroscopic imaging a long handle grasping forceps was introduced into the esophagus and

the cranial end foreign body was grasped (Fig. 3). With gentle traction of forceps, foreign body (bone piece) was removed manually in single attempt without failure (Fig. 4). Antibiotics, anti-inflammatory and antacids were administered continuously two days for early recovery and to avoid postoperative esophagitis. The animal returned to normalcy on the next postoperative day itself.

All esophageal foreign bodies must be treated as emergency cases, especially for the foreign bodies that have sharp point, since minimal delay could result in increased risk of esophageal perforation (Deroy *et al.*, 2015). Esophageal foreign body obstruction was more common in terriers (Moore, 2001). The usual site for foreign body obstruction was the place where the esophagus cannot fully dilate (thoracic inlet; base of the heart; diaphragmatic hiatus (Rosin, 1973) and Thrall (2013). In the present case the location of obstruction was 10 cm caudal to larynx which was not a common site of obstruction. Clinical signs such as excessive salivation and regurgitation of swollen food materials observed in the present case were in agreement with the findings of Luthi and Neiger (1998). Pain on palpation was not exhibited in the present case, this could be due to smooth edges and small size of foreign body. Thompson *et al.* (2012) suggested diagnosis of esophageal foreign body obstruction can be made via physical examination and radiography. Similarly, in the present case physical examination and radiography helped for precised diagnosis. Raw uncooked bones were the most common cause of esophageal foreign body obstruction in dogs (Leib and Sartor, 2008).

The technique used for removal of the foreign body depends on the location and nature of the object and the duration of the obstruction. Smooth foreign bodies located anterior to the heart may be removed through the mouth. In present case fluoroscopic C-arm guided removal made the procedure non-invasive and easier to perform. The

*Corresponding author: vigneshvet@gmail.com

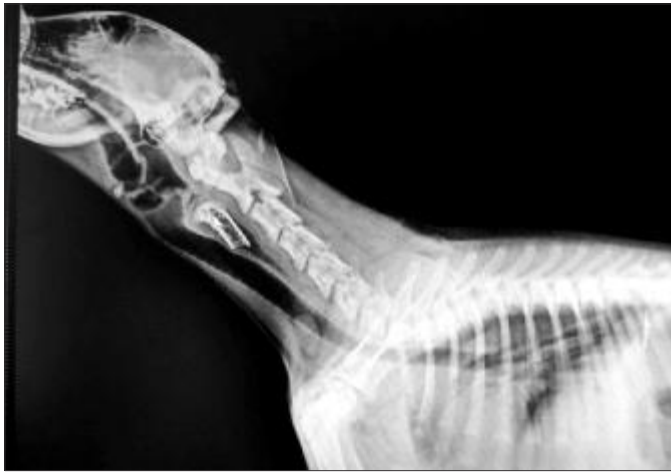

Fig. 1. Radiograph of neck lateral view - Foreign body (bone)



Fig. 2. Animal placed under C-arm guidance

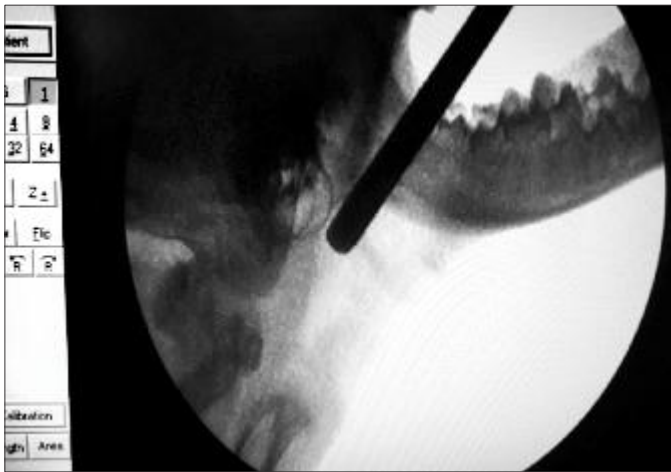


Fig. 3. C-arm fluoroscopic image after introduction of grasping forceps

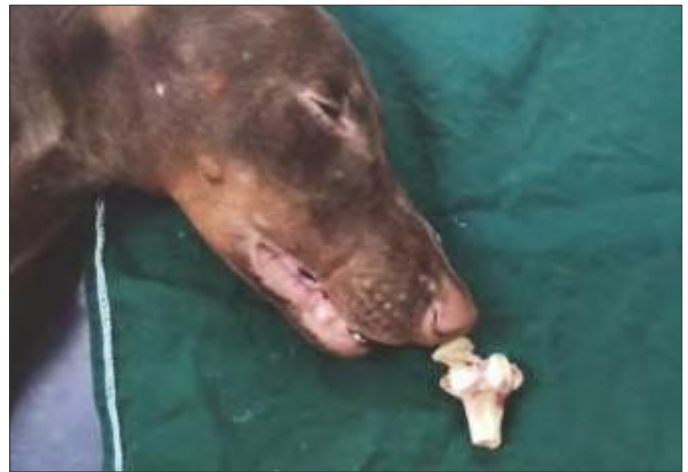

Fig. 4. Retrieved foreign body- Chicken bone

dynamic real time image helps to locate and retrieve the foreign body easily in this case and the same technique was suggested by Moore (2001) in which the removal was rapid and effective with no complications in dogs. Lodgment of objects in the esophagus can result in complications such as ulceration and esophagitis, esophageal perforation, pneumothorax, pneumomediastinum and aortic perforation (Ryan and Greene, 1975). None of the complications was encountered in present case and the animal returns to normalcy on the next day. This could be due to early presentation and non-invasive retrieval of foreign body.

Successful non-invasive fluoroscopic C-arm guided retrieval of esophageal foreign body in a Doberman dog was reported. Non-invasive fluoroscopic C-arm guided retrieval procedure provided real time image for better visualization and need less time with least complication than invasive surgical intervention. Early diagnosis and non-invasive removal of foreign body using C-arm fluoroscopy made animal uneventful recovery.

REFERENCES

- Deroy, C., Corcuff, J.B., Billen, F. and Hamaide, A. (2015). Removal of oesophageal foreign bodies: comparison between oesophagoscopy and oesophagotomy in 39 dogs. *J. Small Anim. Pract.* **56**: 613-617.
- Houlton, J.E.F., Herrtage, M.E., Taylor, P.M. and Watkins, S.B. (1985). Thoracic oesophageal foreign bodies in the dog: a review of ninety cases. *J. Small Anim. Pract.* **26**(9): 521-536.
- Leib, M.S. and Sartor, L.L. (2008). Esophageal foreign body obstruction caused by a dental chew treat in 31 dogs (2000-2006). *J. Am. Vet. Med. Assoc.* **232**(7): 1021-1025.
- Luthi, C. and Neiger, R. (1998). Esophageal foreign bodies in dogs: 51 cases (1992-1997). *Eur. J. Comp. Gastroenterol.* **3**(2): 7-11.
- Moore, A.H. (2001). Removal of oesophageal foreign bodies in dogs: use of the fluoroscopic method and outcome. *J. Small Ani. Pract.* **42**(5): 227-230.
- Pandyan, D., Nandakumar, N., Qayyumi, B.N. and Kumar, S. (2013). C-arm fluoroscopy: a reliable modality for retrieval of foreign bodies in the maxillofacial region. *J. Contemp. Dent. Pract.* **14**(6): 1193-1196.
- Rosin, E. (1973). Surgery of the canine esophagus. *Vet. Clin. North Amer.* **2**(1): 17-27.
- Ryan, W.W. and Greene, R.W. (1975). Conservative management of esophageal foreign bodies and their complications: a review of 66 cases in dogs and cats. *J. Amer. Ani. Hosp. Assoc.* **6**: 243-249.
- Thompson, H.C., Cortes, Y., Gannon, K., Bailey, D. and Freer, S. (2012). Esophageal foreign bodies in dogs: 34 cases (2004-2009). *J. Vet. Emerg. Critic. Care.* **22**: 253-261.
- Thrall, D.E. (2013). Textbook of Veterinary Diagnostic Radiology. (6th Edn.), Elsevier Health Sciences, St. Louis, Missouri. pp. 511-513.