

COMPARATIVE EVALUATION OF SKELETAL MUSCLE ENZYMES IN MALE BUFFALO CALVES SUBJECTED TO ULTRASOUND GUIDED AND CONVENTIONAL TUBE CYSTOSTOMY

ANKIT DANGI, SANDEEP KUMAR*, MANEESH SHARMA¹, RAJESH KUMAR²,
R.N. CHAUDHARY and RAM NIWAS

Department of Veterinary Surgery and Radiology, ¹Department of Veterinary Clinical Complex,

²Department of Veterinary Physiology and Biochemistry, College of Veterinary Sciences,
Lala Lajpat Rai University of Veterinary and Animal Sciences, Hisar-125004, India

Received: 16.04.2022; Accepted: 30.08.2022

ABSTRACT

The present study was carried out in twelve clinical cases of male buffalo calves having history of retention of urine. Buffalo calves having intact urinary bladder on ultrasound examination were included in study and were randomly divided into two groups comprising of six animals in each group. In group I, ultrasound guided tube cystostomy and in group II conventional tube cystostomy was done. Blood samples were taken preoperatively, after surgery, 6 hours, 24 hours, 3rd and 14th day after surgery for biochemical enzymes study. In biochemical examination CK, AST and LDH were found to be significantly varying in between the groups at different time interval while ALT and ALP showed no significant variations during the study.

Keywords: Buffalo, Creatine kinase, Lactate dehydrogenase, Male calves, Ultrasound guided tube cystostomy

How to cite: Dangi, A., Kumar, S., Sharma, M., Kumar, R., Chaudhary, R.N. and Niwas, R. (2023). Comparative evaluation of biochemical enzymes in male buffalo calves subjected to ultrasound guided and conventional tube cystostomy. *The Haryana Veterinarian* 62(SI): 31-33.

Urinary obstruction in young male buffalo calves is a major complication in growing calves during or just after end of winter season (Amarpal *et al.*, 2004). Tube cystostomy along with medical dissolution of uroliths is considered as an effective technique for resolution of urine retention in small ruminants (Ewoldt *et al.*, 2008). Ultrasound-guided suprapubic cystostomy using reusable trocar or selected surgical blade is simple, safe, effective and associated with minimal complications in male buffalo calves (Niwas *et al.*, 2021). Serum levels of skeletal muscle enzymes or proteins are markers of the functional status of muscle tissue and vary widely in both pathological and physiological conditions. Creatine kinase, lactate dehydrogenase, myoglobin, troponin and aspartate aminotransferase are the most useful serum markers of muscle injury (Brancaccio *et al.*, 2010). Therefore, the present study was carried out for comparative evaluation of skeleton muscle enzyme evaluation in ultrasound guided and conventional tube cystostomy for surgical management of urine retention in male buffalo calves.

MATERIALS AND METHODS

The present study was conducted on twelve clinical cases of male buffalo calves suffering from urinary retention but having intact urinary bladder presented to Veterinary Clinical Complex, Lala Lajpat Rai University of Veterinary and Animal Sciences, Hisar, Haryana. The calves of age upto four months and having illness from 1-4 days were randomly divided into two groups comprising of six in

each group. In group I ultrasound guided tube cystostomy and in group II conventional tube cystostomy was done. Ultrasonography was carried out in a dark, quiet room using a real time; B-mode Siemens Acuson S2000 ultrasound machine (Siemens Healthcare Pvt. Ltd.) equipped with convex (3.5 - 6.5 MHz) transducer.

All the calves, were given mild sedation using inj. Xylazine hydrochloride @ 0.05 mg/kg, IM. For ultrasound guided tube cystostomy, a stab incision was given on the skin and muscles in the parapenile region (near the rudimentary teat) after infiltrating 1ml of 2% lignocaine hydrochloride. The Foley's catheter (F 18) was pushed inside the urinary bladder with the help of a AI gun plunger as stylet through this incision. The whole procedure was done under ultrasound guidance. Once, the urine starts coming from the Foley's catheter, the bulb was inflated with recommended amount of normal saline solution and stylet was pulled out. For conventional tube cystostomy 3-4 cm long incision was made on the skin after infiltrating 4-5 ml of local anaesthesia. The muscles and peritoneum were dissected. The intact urinary bladder was palpated and the Foley's catheter (F 18) was pushed inside the urinary bladder with the help of AI gun plunger as stylet as described above. The abdominal wound was sutured in routine manner. Post operatively all the animals were prescribed with Meloxicam @ 0.3 mg/kg body weight and ceftriaxone tazobactam @ 10 mg/kg body weight intramuscular for 5 days. Ammonium chloride @ 500 mg/kg body weight as urine acidifier was given orally for two weeks. The wound

*Corresponding author: drskgvet@gmail.com

was dressed by liquid povidone-iodine solution and fly repellent spray twice daily till the healing of the wound. For the estimation of biochemical enzyme studies, 3ml blood was collected preoperatively, after surgery, 6 hours, 24 hours, 3rd day and 14th day. Serum biochemical analysis was estimated using automatic biochemistry analyzer (EM 200). Two way ANOVA test was used to determine significant difference between groups and at different time intervals.

RESULTS AND DISCUSSION

Detailed values of enzyme estimation are given in Table 1 and 2. Creatine kinase (CK) is a significant and early marker for muscle injury which increased significantly post-operatively and six hours after surgery in group II with significantly higher values in group II (Fig. 1). Lactate dehydrogenase (LDH) increased after both the surgical procedures and then gradually decreased to reach near base value but it was significantly higher after 6 hours and 24 hours in conventional tube cystostomy than the ultrasound guided tube cystostomy group (Fig. 2). There was significant difference within the group II but not in group I for the CK and LDH. CK elevation is more specific than that of LDH for soft tissue injury of the extremities (95.0%) and highly specific for infection (92.9%) while the CK value returned to normal faster than LDH values in patients with soft tissue injury (Matsumoto *et al.*, 1969). Measurement of serum CK activity is an important indicator of the occurrence of muscle cell necrosis and tissue damage due to disease or trauma (Brancaccio *et al.*, 2007). Creatine kinase (CK) and lactate dehydrogenase (LDH) are fragments of the myosin heavy chain (i.e., troponin I and myoglobin) and are related to muscle damage, this is because these molecules are cytoplasmatic and do not have the capacity to cross the sarcoplasmic membrane barrier (Willoughby *et al.*, 2003). For this reason, increased serum concentrations of these molecules are used as an indicator of damage to muscle membrane and other tissue structures (Foschini and Prestes, 2007). Similar findings have been observed in the present study.

Preoperatively the values of aspartate aminotransferase (AST) and alanine aminotransferase (ALT) were within the normal reference range in both the groups, which increased further just after surgery and then decreased back near to base value by 14th day. Similar findings were also reported by Kumar (2020) for the buffalo calves affected with urolithiasis. A significantly ($p < 0.05$) higher AST values were recorded for conventional tube cystostomy after surgery in comparison to ultrasound guided tube cystostomy. There is more significant variation in group II as compare to group I for AST and ALT enzymes. When

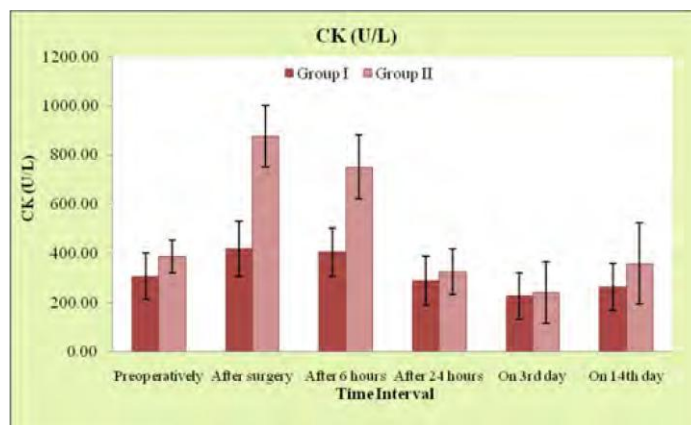


Fig. 1. Mean \pm SE values of Creatine kinase (CK) (IU/L) at different time intervals in male buffalo calves of both the groups suffering from obstructive urolithiasis

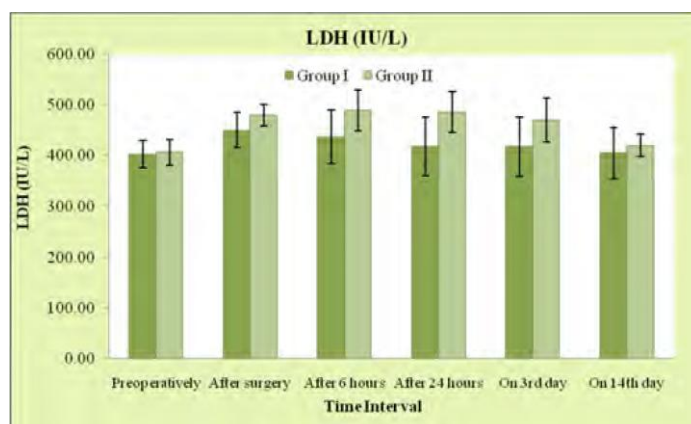


Fig. 2. Mean \pm SE values of Lactate Dehydrogenase (LDH) (IU/L) at different time intervals in male buffalo calves of both the groups suffering from obstructive urolithiasis

muscle is damaged by any injury or trauma, AST and ALT are released from the muscle and their concentration in the blood increases. AST is present in cytosolic and mitochondrial isoenzymes and is found in the liver, cardiac muscle, skeletal muscle, kidneys, brain, pancreas, lungs, leucocytes, and red cells. It is less sensitive and specific for the liver. On the other hand, ALT is a cytosolic enzyme which is more specific to the liver due to the high concentration in liver tissue (Sharon, 2016). Muscle damage lead to cellular protein leakage, and increased serum activity of many enzymes specially creatine kinase, lactate dehydrogenase and aspartate amino transferase (AST), which have been used as biochemical indicators of tissue damage (Siegel *et al.*, 1980). Similar findings have been observed in the present study. The preoperative value of alkaline phosphatase (ALP) was towards the higher side of normal reference range in both the groups which decreased thereafter till the end of observation with more significant variation in group II. Alkaline phosphatase plays an integral role in metabolism within the liver and development within the skeleton system and has less sensitivity for soft tissue damage (Lowe *et al.*, 2021). Similar observations have been found

Table 1

Mean \pm SE values of enzyme parameters in buffalo calves of group I at different time intervals

| Parameters | Preoperatively | After surgery | After 6 hours | After 24 hours | On 3 rd day | On 14 th day |
|------------|----------------------------------|----------------------------------|---------------------------------|---------------------------------|--------------------------------|--------------------------------|
| CK (IU/L) | 307.72 \pm 94.62 | 419.33 \pm 110.51 ^a | 406 \pm 96.85 ^a | 290.28 \pm 98.54 | 227.78 \pm 94.93 | 265.3 \pm 96.45 |
| LDH (IU/L) | 402.45 \pm 26.93 | 449.95 \pm 34.94 | 432.48 \pm 50.37 ^a | 417.98 \pm 57.14 ^a | 418 \pm 58.51 | 404.65 \pm 51.33 |
| AST (IU/L) | 82.28 \pm 3.45 | 94.77 \pm 7.03 ^a | 97.33 \pm 3.67 | 91.80 \pm 6.51 | 87.05 \pm 4.40 | 87.92 \pm 6.19 |
| ALT (IU/L) | 25.63 \pm 1.59 ^{AB} | 28.02 \pm 2.69 ^A | 27.53 \pm 4.13 ^{AB} | 25.12 \pm 3.43 ^{AB} | 22.1 \pm 2.33 ^B | 23.27 \pm 3.51 ^{AB} |
| ALP (IU/L) | 120.08 \pm 13.98 ^{AB} | 126.2 \pm 9.44 ^A | 111.42 \pm 12.6 ^{AB} | 104.12 \pm 9.78 ^{AB} | 95.65 \pm 8.64 ^{AB} | 88.5 \pm 9.19 ^B |

Mean with different superscripts vary significantly (P<0.05). Superscript A, B represents difference with in groups. Superscripts a, b represents difference in between groups.

Table 2

Mean \pm SE values of enzyme parameters in buffalo calves of group II at different time intervals

| Parameters | Preoperatively | After surgery | After 6 hours | After 24 hours | On 3 rd day | On 14 th day |
|------------|----------------------------------|-----------------------------------|-----------------------------------|----------------------------------|----------------------------------|----------------------------------|
| CK (IU/L) | 388 \pm 66.7 ^A | 876.82 \pm 126.16 ^{bb} | 751.22 \pm 131.65 ^{Bb} | 326.62 \pm 92.97 ^A | 241.65 \pm 124.38 ^A | 358.93 \pm 164.25 ^A |
| LDH (IU/L) | 406.22 \pm 25.44 ^A | 480.07 \pm 21.17 ^B | 489.42 \pm 40.11 ^{Bb} | 485.82 \pm 40.77 ^{Bb} | 470.58 \pm 43.45 ^{AB} | 419.85 \pm 22.09 ^A |
| AST (IU/L) | 88.27 \pm 5.89 ^{AC} | 106.03 \pm 4.83 ^{Bb} | 101.13 \pm 6.62 ^{BC} | 95.47 \pm 5.47 ^{ABC} | 92.90 \pm 4.18 ^{CA} | 86.80 \pm 4.34 ^A |
| ALT (IU/L) | 29.28 \pm 4.52 ^A | 37.25 \pm 5.78 ^B | 33.33 \pm 6.54 ^{AB} | 32.28 \pm 5.06 ^{AB} | 29.17 \pm 3.3 ^{AB} | 28.33 \pm 2.78 ^A |
| ALP (IU/L) | 123.35 \pm 13.3 ^{BCD} | 139.4 \pm 11.8 ^A | 121.35 \pm 13.33 ^{BC} | 115.15 \pm 10.4 ^{AB} | 99.77 \pm 8.37 ^{CB} | 89.77 \pm 9.19 ^D |

Mean with different superscripts vary significantly (P<0.05). Superscripts A, B, represent difference with in groups. Superscripts a, b represents difference in between groups.

in the present study.

On basis of present study it can be concluded that creatine kinase (CK) lactate dehydrogenase (LDH) and aspartate aminotransferase (AST) can be used to as a trauma marker for muscle injury during tube cystostomy which comes to normal range as the muscle injury subsides with time and creatine kinase (CK) is more specific and early maker for muscle trauma in buffalo calves.

REFERENCES

- Amarpal, Kinjavdekar, P., Aithal, H.P., Pawde, A.M., Singh, T. and Pratap, K. (2004). Incidence of urolithiasis: A retrospective study of five years. *Indian J. Ani. Sci.* **72**(2): 175-177.
- Brancaccio, P., Maffulli, N. and Limongelli, F.M. (2007). Creatine kinase monitoring in sport medicine. *British Medical Bulletin.* **81**(1): 209-230.
- Brancaccio, P., Lippi, G. and Maffulli, N. (2010). Biochemical markers of muscular damage. *Clin. Chem. Lab. Med.* **48**(6): 757-67.
- Ewoldt, J.M., Jones, M.L. and Miesner, M.D. (2008). Surgery of obstructive urolithiasis in ruminants. *Vet. Clinics N. America: Food Ani.* **24**: 455-465.
- Foschini, D. and Prestes, J. (2007). Acute hormonal and immune responses after a bi-set strength training. *Fit. Perform J.* **6**: 38-44.
- Kumar, A. (2020). Efficacy of ammonium chloride and Walpole's solution for the treatment of obstructive urolithiasis in male buffalo calves. M.V.Sc. thesis submitted to Lala Lajpat Rai University of Veterinary and Animal Sciences, Hisar (Haryana).
- Lowe, D., Sanvictores, T. and John, S. (2021). Alkaline Phosphatase. In: StatPearls [Internet]. Treasure Island (FL): Stat Pearls Publishing; 2022 Jan. Available from: <https://www.ncbi.nlm.nih.gov/books/NBK459201>.
- Matsumoto, T., Steven, R.W., Roger, V.M. and Gary, M. (1969). Serum creatine phosphokinase in soft tissue injuries. *Arch Surg.* **99**(4): 535-536.
- Niwas, R., Saharan, S., Priyanka and Kumar, S. (2021). Ultrasound guided tube cystotomy in buffalo calves. *Pharma Innovation J.* **10**(1): 42-45.
- Sharon, G.B. (2016). Nutraceuticals in hepatic diseases. *Nutraceuticals* (2nd Edn.), pp. 87-89.
- Siegel, A.J., Silverman, L.M. and Lopez, R.E. (1980). Creatine kinase elevations in marathon runners: relationship to training and competition. *Yale J. Biol. Med.* **53**: 275-279.
- Willoughby, D.S., McFarlin, B. and Bois, C. (2003). Interleukin-6 expression after repeated bouts of eccentric exercise. *Int. J. Sports Med.* **24**: 15-21.