

EVALUATION OF POSITIVE PROFILE END THREADED INTRAMEDULLARY PINS FOR THE REPAIR OF FEMUR FRACTURES IN DOGS

BALKRISHAN YADAV, M. C. PARASHAR*, Y.P. SINGH and SATYAVEER SINGH

Department of Veterinary Surgery and Radiology,
Post Graduate Institute of Veterinary Education and Research (PGIVER), Jaipur-302031, India

Received: 27.05.2022; Accepted: 01.08.2022

ABSTRACT

The aim of the study was to evaluate the positive profile end threaded intramedullary pins for the repair of femur fractures in dogs. Six dogs (n=6) with seven fractures of femur were included in the study. All the fractures were stabilized by open reduction and internal fixation with positive profile end threaded intramedullary pins under general anaesthesia followed by application of modified Robert Jones bandage. The average period of earliest weight bearing was 4.5 ± 0.67 days. At 30th and 60th postoperative day, the average grade of lameness was 1.67 ± 0.21 and 0.83 ± 0.30 , respectively. At the time of complete weight bearing grades of radiographic healing in all animals ranged from 1-2 with a mean of 1.43 ± 0.20 . The implant was removed in four cases by 60th postoperative day. Post-operative complications included; seroma formation at the point of exit of pin (n=4), Proximal migration of pin (n=1) and mild osteomyelitis (n=1). The study concludes that the positive profile end threaded intramedullary pin provides rigid fixation, early weight bearing and satisfactory healing. Minor complications of collapsing of proximal fragment, pin migration and seroma formation at the proximal pin insertion site were also recorded.

Keywords: End threaded, Femur, Fracture, Intramedullary pin, Positive profile

How to cite: Yadav, B., Parashar, M.C., Singh, Y.P. and Singh, S. (2023). Evaluation of positive profile end threaded intramedullary pins for the repair of femur fractures in dogs. *The Haryana Veterinarian* 62(SI): 61-64.

Orthopedic affections constitute a major problem in the small animal practice and most of these affections are related to long bone diaphyseal fractures such as femur, humerus, and tibia bones (Piermattei *et al.*, 2006). Femur fractures are generally not amenable to conservative repair with external coaptation, and some kind of internal fixation is recommended (Piermattei and Flo, 1997). Intramedullary pinning is one of the most commonly used techniques in veterinary orthopaedics for the repair of long bone fractures (Kaur *et al.*, 2015). Unthreaded intramedullary pins alone cannot provide adequate traction and rotational stability as they are weak against rotational and shearing forces (DeYoung and Probst, 1993). End threaded intramedullary negative profile pins are the pins which can penetrate into the cancellous part of distal fragment and provide stability against the bending forces and also prevents migration of the pin, but the strength of this implant at the pin- thread junction is weak and prone to breakage if the junction is at the fracture site. The weak pin-thread junctions are not seen in positive profile end threaded intramedullary pins as the threads are raised above the core diameter of the pin (Chanana *et al.*, 2018). The aim of the present study was to evaluate the positive profile end threaded intramedullary pins for fixation of femur fractures in dogs.

MATERIALS AND METHODS

The study was conducted on six dogs (n=6) with seven fractures of femur presented to the VCC, Post Graduate Institute of Veterinary Education & Research,

Jaipur. The aetiology and signalment of the animals were recorded. Physical examination and radiography was done to diagnose the type of fracture. All the dogs were stabilized hemodynamically by administration of intravenous fluids besides analgesics and antibiotics. The fracture site was temporarily immobilized with modified Robert Jones bandage till surgery.

All the dogs were pre-medicated with a combination of inj. Atropine Sulphate @ 0.04 mg/kg body weight (b.wt.), inj. Butorphanol @ 0.2 mg/kg b.wt. and inj. Ceftriaxone @ 25 mg/kg b.wt. intramuscularly. The induction of anaesthesia was achieved with inj. Propofol @ 4 mg/kg b.wt. slow IV followed by intubation with endotracheal tubes of suitable size and inj. Diazepam @ 0.5 mg/kg b.wt. was given intravenously. The anaesthesia was maintained with 1-2% Isoflurane in oxygen.

For the repair of fracture, the fragments were exposed in routine manner (Piermattei and Greeley, 1979; Fig. 1). A pilot hole was made from fracture site using Steinmann pin. The positive profile end threaded intramedullary pin was inserted in a retrograde manner using a Jacob's chuck (Fig. 2). Reduction was maintained with the bone holding forceps while the positive profile end threaded intramedullary pin was driven into the distal fragment. Ancillary support with 2 and 3 cerclage wires in 3 and 2 cases, respectively, was given in long oblique fractures. Seating was achieved, by clockwise rotating the positive profile end threaded pin so that it may interdigitate with the cancellous bone (Fig. 3). After seating the part of the pin outside the proximal fragment was cut as short as

*Corresponding author: mukeshparashar77@gmail.com

possible using a pin cutter. The fracture site was closed as per the standard procedure.

Post-operatively, external support to the operated limb was provided using modified Robert Jones bandaging. The dogs were administered inj. Ceftriaxone+ Tazobactam sodium @ 20 mg/kg b.wt. twice daily for 5 consecutive days and inj. Meloxicam @ 0.2 mg/kg b.wt. on day one and 0.1 mg/kg b.wt. once daily for next 3 days, intramuscular post-operatively. Oral administration of calcium syrup was advised for one month in all the operated dogs. All the operated dogs were evaluated on 0th, 20th, 40th and 60th post-operative days. The dogs which were operated for correcting the femoral fractures were observed for limb function of affected limb (weight bearing status i.e. grading of lameness as described by Dymond *et al.*, 2010; Gonçalves *et al.*, 2016). The radiographic evaluation was included: the noting of presence of amount of periosteal reaction and callus formation at the fracture site as described by Hammer *et al.* (1985).

RESULTS AND DISCUSSION

In the present study, the male non-descript dogs were more {66.67% (n=4)} than the females. Non-descript males being, most common and having aggressive behaviour might have contributed to more number of fractures (Singh *et al.*, 2017), however, the breed of dogs may vary on the area of study (Kushwaha *et al.*, 2011). The mean age and weight of the dogs was 14±6.89 months and 15.67±3.24 Kg, respectively. Young dogs of less than one year of age are more prone to fractures due to their active and playful nature and lower bone strength (Kushwaha *et al.*, 2011; Singh *et al.*, 2017; Sodhi *et al.*, 2021). Most of the fractures reported were due to automobile accident {83.33% (n=5)} followed by fall from height (16.67%, (n=1). Accidental trauma or fall from height is the commonly reported causes of femur fractures in dogs (Priyanka *et al.*, 2019). The right side limb (50%) was more affected than the left side (33.33%) with one being bilateral (16.67%). Radiographically, the most common location of femur fractures was mid shaft (85.71%, (n=6) with one fracture being in proximal third region. Transverse and oblique fractures each were observed in 42.86%, and comminuted in 14.28% cases (Fig. 4). Transverse and oblique fractures followed by comminuted fracture are commonly reported in femur bones (Kushwaha *et al.*, 2011; Singh *et al.*, 2017).

Immediate post-operative radiographs showed appropriate reduction and apposition of fracture fragments with satisfactory implant placement in all the cases. Earliest weight bearing of the affected hind limb was noticed in less than 5 days in 66.67% dogs. The average

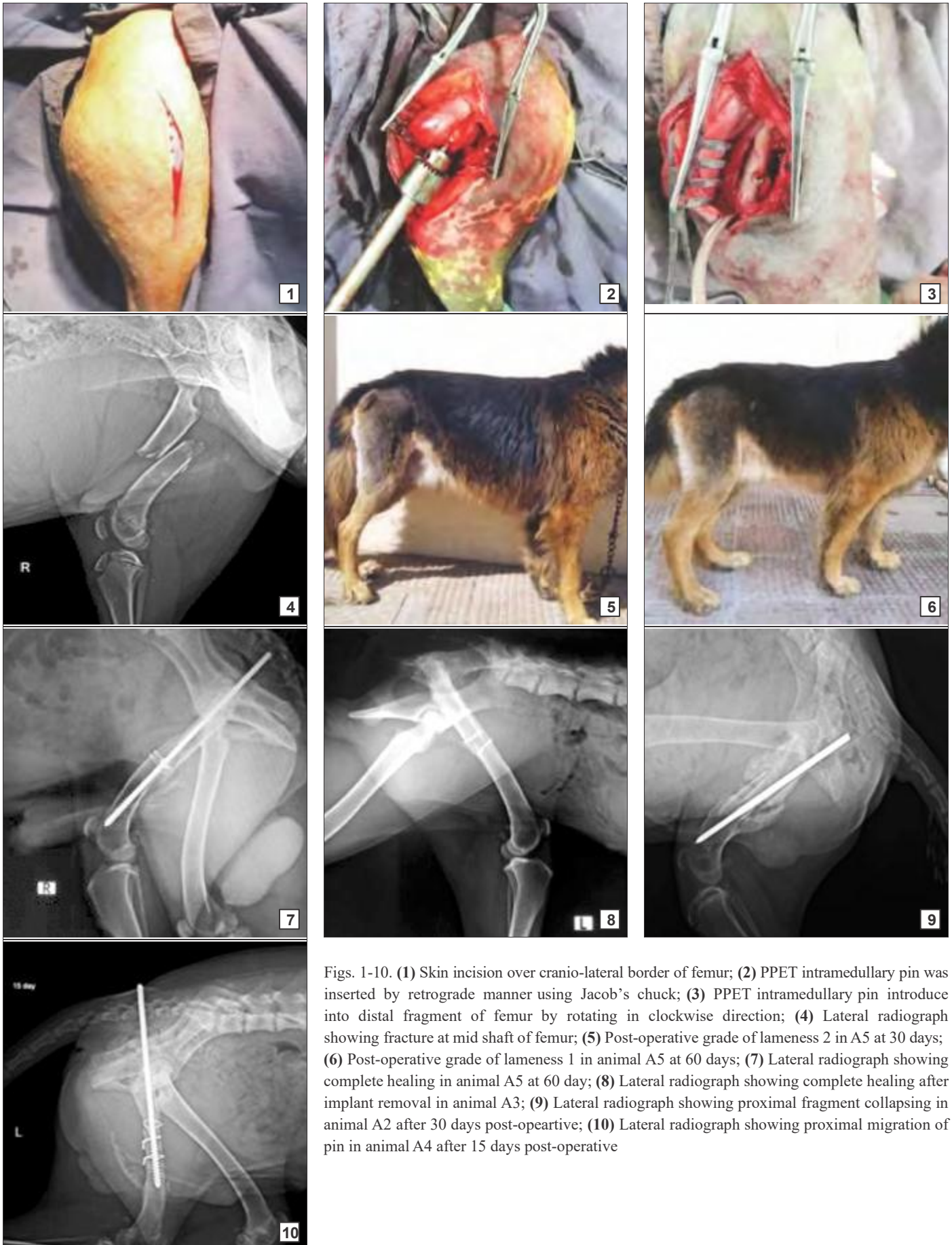
Table 1
First weight bearing in dogs and grade of lameness

Case. No.	First weight Bearing (days)	Grade of lameness		
		Pre -operative	Post-operative	
			Day 30	Day 60
1.	7	4	2	1
2.	4	4	1	0
3.	3	4	1	0
4.	6	4	2	1
5.	4	4	2	1
6.	3	R	2	2
7.	-	-	-	-
Mean±SE	4.5±0.67	3.33±0.67	1.67±0.21	0.83±0.30

period of earliest weight bearing was found to be 4.5±0.67 days. Early weight bearing is common in fracture repaired with end threaded pins (Singh *et al.*, 2017) due to rigid fixation in the distal fragment. At 30th and 60th day post-operative, the grade of lameness in all the dogs ranged from 1-2 (Fig. 5) with a mean of 1.67±0.21 and 0-2 (Fig. 6) with a mean of 0.83±0.30, respectively (Table 1). The final limb function outcome was found excellent, good and fair 57.14%, 14.28% and 28.57% cases, respectively. The average period in which the excellent limb function achieved was 7.57±0.37 weeks.

All the 7 fracture cases were evaluated for the progress of radiographic fracture healing achieved during the study period. Complete periosteal reaction was recorded in 57.14% and mild in 42.86% cases. Chanana *et al.* (2018) opined that, use of positive profile end threaded pins provide 30-40% unoccupied medullary cavity at the fracture site, which allow the medullary circulation to regenerate and might aid in early healing. Complete union, moderate bridging and mild bridging were seen in the final radiographic healing in 57.14%, 14.28% and 28.57% cases respectively. The average time taken for complete union was 9.43±0.84 weeks. Rahn *et al.* (1971) reported that direct bone healing occurred under conditions of stable injuries, rigid internal fixation, fracture compression and where there was complete apposition of fracture fragments. At the time of complete weight bearing, the grades of radiographic healing ranged from 1-2 with a mean of 1.43±0.20 (Fig. 7). The implant was removed in four cases by the 60th post-operative day (Fig. 8, Table 2).

The seroma formation at the point of insertion of positive profile end threaded intramedullary pin was observed in four cases. In one case the end threaded pin lead to collapsing of proximal fragment (especially in mid shaft fractures), as the proximal portion of the pin is smooth (Fig. 9) and in one case the dog showed early weight bearing leading to appearance of proximal



Figs. 1-10. (1) Skin incision over cranio-lateral border of femur; (2) PPET intramedullary pin was inserted by retrograde manner using Jacob's chuck; (3) PPET intramedullary pin introduce into distal fragment of femur by rotating in clockwise direction; (4) Lateral radiograph showing fracture at mid shaft of femur; (5) Post-operative grade of lameness 2 in A5 at 30 days; (6) Post-operative grade of lameness 1 in animal A5 at 60 days; (7) Lateral radiograph showing complete healing in animal A5 at 60 day; (8) Lateral radiograph showing complete healing after implant removal in animal A3; (9) Lateral radiograph showing proximal fragment collapsing in animal A2 after 30 days post-operative; (10) Lateral radiograph showing proximal migration of pin in animal A4 after 15 days post-operative

Table 2
Radiographic observations

Case no.	Reduction of fracture fragments	Position of implant	Initial periosteal reaction (2-4 weeks)	Radiographic healing grade	Radiographic healing outcome	Limb function outcome
1.	Slight overriding	Good	Mild	1	Complete union (13 weeks)	Excellent (7weeks)
2.	Slight overriding	Good	Full	1	Complete union (12 weeks)	Excellent (6weeks)
3.	Good	Excellent	Mild	2	Moderate bridging (8 weeks)	Excellent (8weeks)
4.	Excellent	Good	Full	2	Mild bridging (9 weeks)	Good (9weeks)
5.	Slight overriding	Excellent	Mild	1	Complete union (9 weeks)	Excellent (8weeks)
6.	Good	Excellent	Full	1	Complete union (8 weeks)	Fair (8weeks)
7.	Slight overriding	Good	Full	1	Complete union (7 weeks)	Fair (7weeks)
Mean ±SE				1.43±0.20	9.43±0.84 weeks	7.57±0.37 weeks

migration of pin (Fig. 10) during this study. Singh *et al.* (2022) observed proximal migration of end threaded pin in one case. Large amount of external callus was noticed in one dog in the present study which could be due to collapsing of fragments. Piermattei *et al.* (2006) stated that, the amount of callus formed at the fracture site is inversely proportional to degree of stability at the fracture site. However, young animals show excess callus at the fracture site though the fracture fixation was rigid. Singh *et al.* (2022) stated that, fracture healed by secondary bone healing with visible moderate to large amount of callus formation.

The end threaded intramedullary pin could be effectively used in internal fixation of diaphyseal fracture of long bones in dogs (Parashar *et al.*, 2020) by preventing migration due to gripping the cancellous bone (Altunatmaz *et al.*, 2012, Chanana *et al.*, 2018).

CONCLUSIONS

The positive profile end threaded intramedullary pin provides rigid fixation and early weight bearing and satisfactory healing. Minor complications of collapsing of proximal fragment, pin migration and seroma formation at the proximal pin insertion site are recorded with positive profile end threaded intramedullary pin.

REFERENCES

- Altunatmaz, K., Ozsoy, S., Mutlu, Z., Devcioglu, Y. and Guzel, O. (2012). Use of intramedullary fully threaded pins in the fixation of feline and canine humeral, femoral and tibial fractures. *Vet. Compar. Orthopaed. Traumatol.* **25**: 321-325.
- Chanana, M., Kumar, A., Tyagi, S.P., Singla, A.K., Sharma, A. and Farooq, U.B. (2018). End-threaded intramedullary positive profile screw ended self-tapping pin (Admit pin) - A cost-effective novel implant for fixing canine long bone fractures. *Vet. World.* **11**(2): 181-185.
- DeYoung, D.J. and Probst, C.W. (1993). Methods of internal fracture fixation. In: Slatter, DH (Ed.): Textbook of Small Animal Surgery. Philadelphia, WB Saunders, pp. 1954-1962.
- Dymond, N.L., Goldsmid, S.E. and Simpson, D.J. (2010). Tibial tuberosity advancement in 92 canine stifles: Initial results, clinical outcome and owner evaluation. *Austral. Vet. J.* **88**(10): 381-385.
- Gonçalves, L.C.V.B., Simões, A.D.G.A., Millis, D.L. and Matos, A.J.F.D. (2016). Development of a scale to evaluate mobility in dogs. *Ciência Rural.* **46**(12): 2210-2215.
- Hammer, R.R.R., Hammerby, S. and Lindholm, B. (1985). Accuracy of radiologic assessment of tibial shaft fracture union in humans. *Clinic. Orthoped. Rel. Res.* **199**: 233-238.
- Kaur, A., Kumar, A., Kumar, D., Mohindroo, J. and Saini, N.S. (2015). Feasibility of C-arm guided closed intramedullary pinning for the stabilization of canine long bone fractures. *Vet. World.* **8**(12): 1410-1415.
- Kushwaha, R.B., Gupta, A.K., Bhadwal, M.S., Kumar, S. and Tripathi, A.K. (2011). Incidence of fractures and their management in animals: a clinical study of 77 cases. *Ind. J. Vet. Surg.* **32**(1): 54-56.
- Parashar, M.C., Singh, S., Singh, Y.P. and Kumar, V. (2020). End threaded intramedullary pinning for the management of femoral fracture in a dog. *Livestock Res. Intern.* **08**(01): 31-33.
- Piermattei, D.L. and Greeley, R.G. (1979). An atlas of surgical approaches to the bones of the dogs and cats. (2nd Edn.), W B Saunders, Philadelphia, p. 72.
- Piermattei, D., Flo, G. and De Camp, C. (2006). Fractures: Classification, Diagnosis, and Treatment. In: Brinker, Piermattei, and Flo's Handbook of Small Animal Orthopedics and Fracture Repair. (4th Edn.), Saunders Elsevier, Missouri, USA. pp. 25-159.
- Piermattei, D.L. and Flo, G.L. (1997) Fractures of the femur and patella, In Handbook of Small Animal Orthopedics and Fracture Repair, By Brinker, Piermattei and (Flo 3rd Edn.), WB Sanders, Philadelphia, pp. 469-15.
- Priyanka, Singh, T., Mohindroo, J., Verma, P., Udheiya, R. and Umeshwori, N. (2019). Evaluation of intramedullary pinning technique for management of tibia fractures in dogs. *Pharma Innov. J.* **8**(2): 291-297.
- Rahn, B.A., Gallinaro, P. and Perren, S.M. (1971). Primary bone healing. *J. Bone Join. Surg. Amer.* **53**: 783.
- Singh, S., Kumar, A., Kumar, A., Tyagi, S.P. and Sharma, M. (2022). Intramedullary implant fixation for management of diaphyseal fractures of humerus in dogs. *The Haryana Veterinarian* **61**(SI): 9-13.
- Singh, D., Singh, R., Chandrapuria, V.P. and Vaish, R. (2017). Occurrence pattern of different types of fracture in bovine, caprine and canine. *J. Anim. Res.* **7**(4): 745-749.
- Sodhi, H.S., Kumar, A., Anand, A., Sangwan, V. and Singh, O. (2021). Comparison of titanium elastic nailing and end-threaded intramedullary pinning for distal femoral fractures in young dogs. *Indian J. Anim. Res.* **B-4454**: 1-8.