

INCIDENCE OF ANTEBRACHIAL ANGULAR LIMB DEFORMITIES IN DOGS

R.MAHESH*, S.AYYAPPAN, MOHAMED SHAFIUZAMA, H. PUSHKIN RAJ and A. VELAVAN

Department of Veterinary Surgery and Radiology
Madras Veterinary College, TANUVAS, Chennai-600007, India

Received: 05.07.2022; Accepted: 06.10.2022

ABSTRACT

A retrospective study was carried out on the incidence of antebrachial angular limb deformities in dogs presented to Small Animal Orthopaedic out-patient unit, Madras Veterinary College Teaching Hospital (MVCTH), Chennai, over a period of two years (April 2020 to May 2022). A total of 121 (0.7%) dogs with antebrachial angular limb deformities were reported out of 17,187 canine orthopaedic cases. The most commonly represented dogs were non-descript (n= 45, 37.2%) followed by Chippipari (n= 33, 27.3%), German Shepherd (n= 12, 9.91%), Labrador Retriever (n= 7, 5.8%), Rajapalayam (n= 6, 4.95%), Great Dane (n= 4, 3.31%), Doberman (n= 3, 2.48%), Bully Kutta (n=2, 1.65%), Mudhol Hound (n=2, 1.65%), Spitz (n=2, 1.65%), Dalmatian (n=1, 0.82%), Golden retriever (n=1, 0.82%), Saint Bernard (n=1, 0.82%), Shih Tzu (n=1, 0.82%) and Rottweiler (n=1, 0.82%) in the present study. Male dogs (66.94%) showed higher incidence of antebrachial angular limb deformities than female dogs (33.06%). The etiological factors for antebrachial angular limb deformity were found to be premature closure of the distal physis of radius and ulna (46.23%), hypertrophic osteodystrophy (HOD) (27.27%), malunion of radius and ulna (18.2%) and retained cartilaginous cores of ulna (8.3%). During the study, a higher incidence of carpal valgus (70.25%), followed by radius procurvatum and carpus valgus (14.05%), radius procurvatum (11.57%), carpus varus (2.48%) and radius recurvatum (1.65%) were recorded. In conclusion, male and skeletally immature, non-descript dogs with bilateral carpus valgus were found to be having higher incidence of antebrachial angular limb deformities in the present study.

Keywords: Antebrachial limb deformities, Carpus valgus, Radius procurvatum, Hypertrophic Osteodystrophy

How to cite: Mahesh, R., Ayyappan, S., Shafiuzama, M., Raj, H.P. and Velavan, A. (2023). Incidence of antebrachial angular limb deformities in dogs. *The Haryana Veterinarian* 62(SI): 65-67.

Antebrachial limb deformity in dogs is induced by ulnar or radial physal development that is delayed, decreased or non-existent (Latte, 1998). Secondary causes of these deformities include trauma and chondrodysplasia (Weigel, 1987), genetic predisposition, metabolic diseases, hyperparathyroidism and rickets (Hazewinkel, 1989), multiple cartilaginous exostoses, hypertrophic osteodystrophy, malunion of antebrachium fractures, joint contracture, and polyarthritis. The main objective of this study is to report incidence of antebrachial angular limb deformities in dogs.

MATERIALS AND METHODS

A review of clinical cases with antebrachial angular limb deformities in dogs presented to the Small Animal Orthopaedic out-patient Unit of Madras Veterinary College Teaching Hospital from April 2020 to May 2022 was carried out in this study. The information regarding the age, breed, sex, etiological factors and type of antebrachial angular limb deformity were recorded. All the cases underwent thorough clinical, orthopaedic and radiographic examination.

RESULTS AND DISCUSSION

In the present study, a total of 121 (0.7%) antebrachial angular limb deformities were recorded out of 17,187 canine orthopaedic cases brought to the Small Animal Orthopaedic out-patient Unit of Madras Veterinary College Teaching Hospital and the occurrence of antebrachial angular

limb deformity was observed more in non-descript dogs (n=45, 37.2%) followed by Chippipari (n=33, 27.3%), German Shepherd (n=12, 9.91%), Labrador Retriever (n=7, 5.8%), Rajapalayam (n=6, 4.95%), Great Dane (n=4, 3.31%) and Doberman (n=3, 2.48%), Bully Kutta (n=2, 1.65%), Mudhol Hound (n=2, 1.65%), Spitz (n=2, 1.65%), Dalmatian (n=1, 0.82%), Golden retriever (n=1, 0.82%), Saint Bernard (n=1, 0.82%), Shih Tzu (n=1, 0.82%) and Rottweiler (n=1, 0.82%) (Fig. 1). The higher incidence of antebrachial limb deformity in non-descript dogs might be due to the higher population and nutritional factors like imbalance in calcium and phosphorous levels compared to other breeds (Thyese *et al.*, 2005). The highest incidence of antebrachial angular limb deformity of dogs recorded in the age group of 2-6 months (n=94, 77.68%), followed by 7-12 months (n=20, 16.53%) and more than one year (n=7, 5.79%) in the present study. This indicated that the antebrachial angular limb deformity is mostly observed in growing period (Fig. 2). Male dogs (81, 66.94%) showed higher incidence of antebrachial angular limb deformities than female dogs (n=40, 33.06%) (Fig. 3). Langley-Hobbs *et al.* (1996) reported thirty-four dogs with unilateral angular antebrachial growth deformity in their prospective evaluation from 1994-2002 and found Labrador (n=6, 18%) and Golden Retriever (4, 12%) as the most common breeds with gender distribution of (n=19, 56%) males and (n=15, 44%) female dog. The higher incidence of antebrachial angular deformities was recorded in bilateral (n=95, 78.51%) compared to unilateral limbs (n=26,

*Corresponding author: mahivet04@gmail.com

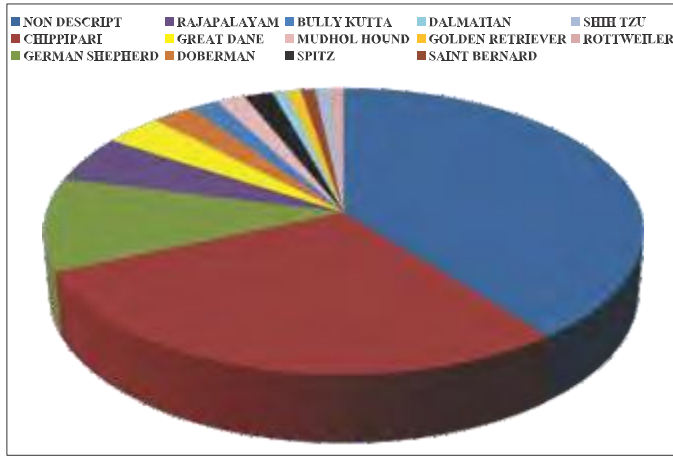


Fig. 1. Breed wise incidence of antebrachial angular limb deformities

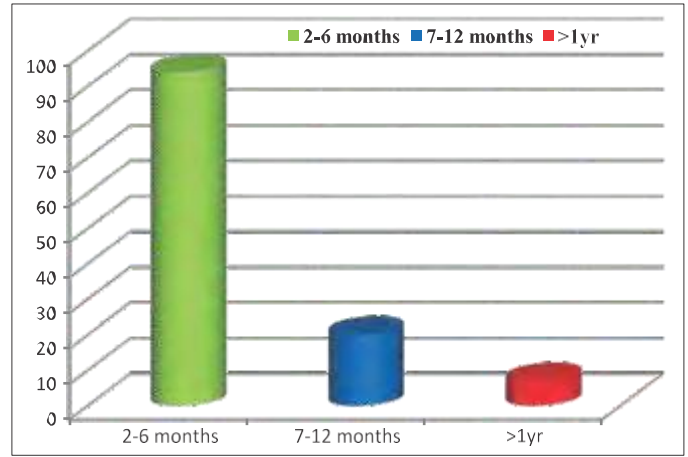


Fig. 2. Age wise incidence of antebrachial angular limb deformities

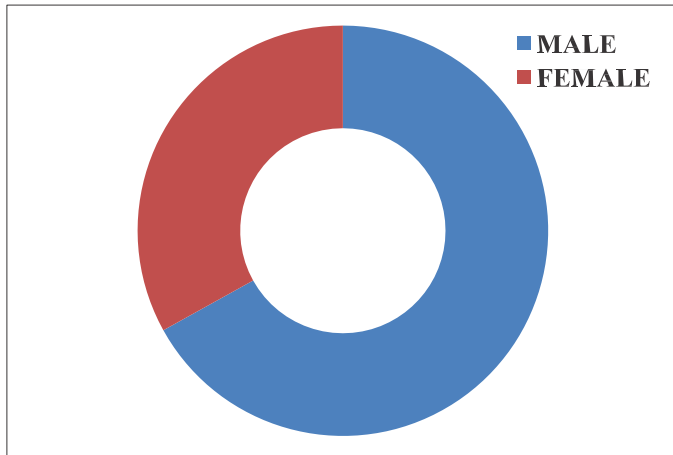


Fig. 3. Gender wise incidence of antebrachial angular limb deformities

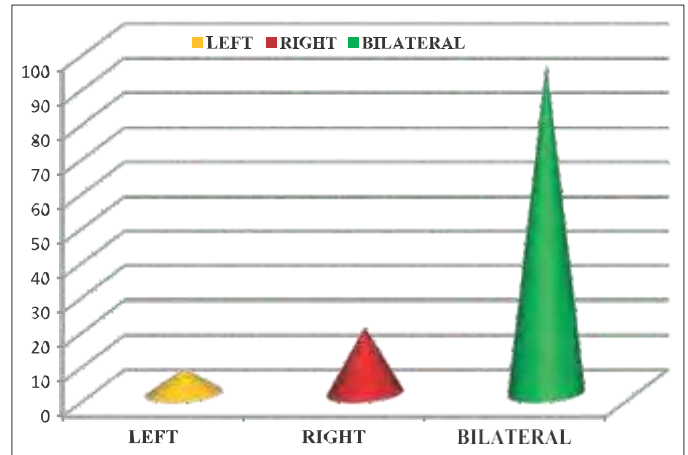


Fig. 4. Incidence of fore limb involved in antebrachial angular limb deformities

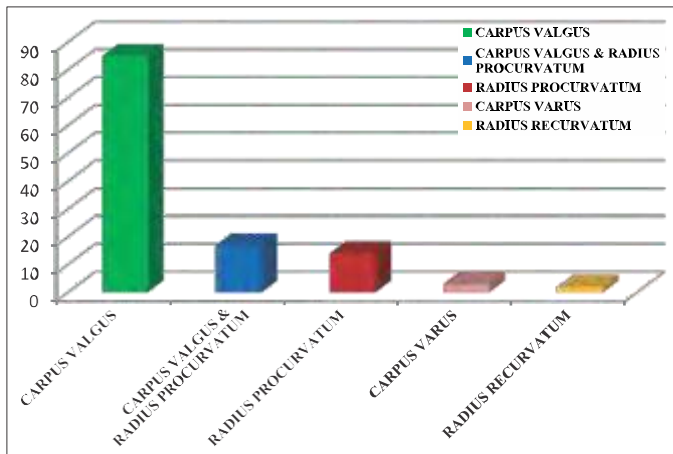


Fig. 5. Incidence of type of antebrachial angular limb deformities 21.49%) (Fig. 4).

Orthopaedic examination revealed grade II to III lameness with carpus valgus (n=85, 70.25%), carpus valgus and radius procurvatum (n=17, 14.05%), radius procurvatum (n=14, 11.57%), carpus varus (n=3, 2.48%) and radius recurvatum (n=2, 1.65%) (Fig. 5). Carrig (1983) mentioned that asynchronous growth of the radius and ulna was caused by premature closure of the distal

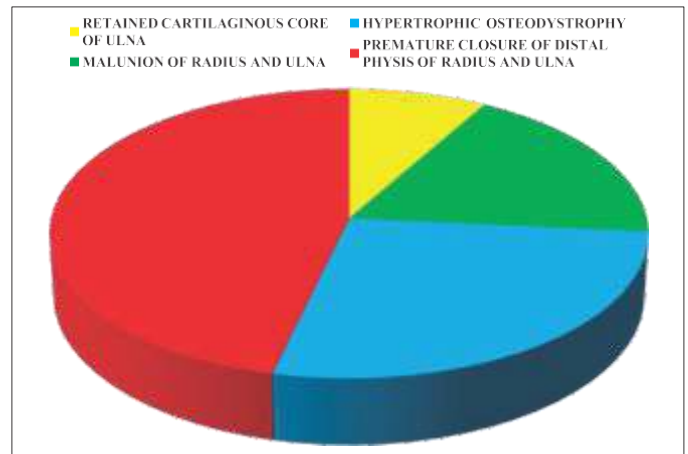


Fig. 6. Incidence of etiology for antebrachial angular limb deformities

radial and ulnar physes, or both, as well as premature proximal radial physal closure and radio-ulnar synostosis, which has been identified as a well-organized cause of antebrachial angular and rotational deformities in dogs. Johnson and Hulse (2002) stated that the synchronised growth of the radius and ulna in the dog is required for appropriate forelimb development. The radius obtains 40% of its length from the proximal physis and 60% from

the distal physis, whereas the distal physis contributes 85% of the ulnar length and the proximal physis just 15%. Piras *et al.* (2012) stated that the most prevalent aetio-pathogenesis of antebrachial abnormalities in dogs is growth retardation at the level of the distal radial and ulnar physes, which results in excessive radial procurvatum, external torsion, and distal radial valgus.

In the present study, radiographic examination revealed premature closure of distal physis of radius and ulna (n=56, 46.23%), hypertrophic osteodystrophy (n=33, 27.27%), malunion of radius and ulna (n=22, 18.2%) and retained cartilaginous core of ulna (n=10, 8.3%) were the etiological factors for antebrachial angular limb deformity (Fig. 6). Disturbances to the distal growth plate of the radius and ulna caused most of the antebrachial angular limb deformities in current study. Carrig (1983) mentioned that the distal ulnar physis is implicated in 75 percent of canine thoracic limb growth abnormalities, and a combination of limb shortening, radial procurvatum, external rotation, and carpal valgus are common in dogs as a result of ulnar growth retardation. Fox (1984) stated that as the distal ulnar physis in dogs is conical in shape, any lateral shearing forces to the limb are converted into compressive forces at the physis, causing the ulna to stop growing, acting as a “bow string” that restricts longitudinal growth of the radius, resulting in cranial bowing of the radius, radial shortening, and valgus deformity of the carpus. Balfour *et al.* (2000) opined that the most prevalent cause of radial growth deformation is premature closure of the distal ulnar physis. Shields-Henney and Gambardella (1989) reported that trauma is the most common cause of early closure of physis in dogs causing forelimb deformities.

Based on the data obtained in the present study, it can be concluded that there was a high incidence of antebrachial

angular limb deformities in non-descript male dogs below 6 months and the predominant antebrachial angular limb deformity was bilateral carpal valgus. Premature closure of distal physis of radius and ulna was the primary cause noticed for most of the antebrachial angular limb deformity in the present study.

REFERENCES

- Balfour, R.J., Boudrieau, R.J. and Gores, B.R. (2000). T-plate fixation of distal radial closing wedge osteotomies for treatment of angular limb deformities in 18 dogs. *Vet. Surg.* **29**: 207-217.
- Carrig, C.B. (1983). Growth abnormalities of the canine radius and ulna. *Vet. Clin. North Am. Small Anim. Pract.* **13**: 91-115.
- Fox, S.M. (1984). Premature closure of distal radial and ulnar physes in the dog. Part I. Pathogenesis and diagnosis. *Compend. Cont. Ed. Pract. Vet.* **6**: 128-139.
- Hazewinkel, H.A.W.(1989). Nutrition in relation to skeletal growth deformities. *J. Small Anim. Pract.* **30**: 625-630.
- Johnson, T.W. and Hulse, D.A. (2002). Radial and ulnar growth deformities. In: Small animal surgery, (2nd Edn.), Ed. Johnson and Hulse T.W., Mosby, Missouri. pp. 955-963.
- Langley-Hobbs, S.J., Carmichael, S., Pead, M.J. and Torrington, A.M. (1996). Management of antebrachial deformity and shortening secondary to a synostosis in a dog. *J. Small Anim. Pract.* **37**: 359-363.
- Latte, Y. (1998). 75 applications of ilizarov method (Part 2). *European J. Comp. Anim. Pract.* **8**: 64-81.
- Piras L.A., Peirone, B. and Fox, D.B. (2012). Effects of antebrachial torsion on the measurement of angulation in the frontal plane: a cadaveric radiographic analysis. *Vet. Comp. Orthop. Traumatol.* **25**: 89-94.
- Shields -Henney, L.H. and Gambardella, P.C. (1989). Premature closure of the ulnar physis in the dog: a retrospective clinical study. *J. Am. Anim. Hosp. Assoc.* **25**: 573-581.
- Theyse, L.F., Voorhout, G. and Hazewinkel, H.A. (2005). Prognostic factors in treating antebrachial growth deformities with a lengthening procedure using a circular external skeletal fixator system in dogs. *Vet. Surg.* **34**: 424-435.
- Weigel, J.P. (1987). Growth deformities. *Vet. Clin. North Am. Small Anim. Pract.* **17**: 905-921.