

GROSS AND RADIOGRAPHIC STUDIES ON ARTERIAL SUPPLY OF THIGH REGION IN GOAT

ADITYA KUMAR^{1*}, R.K. JAIN and PARVEEN KUMAR GAHLOT

Department of Veterinary Anatomy, College of Veterinary Sciences,
LalaLajpat Rai University of Veterinary and Animal Sciences, Hisar-125004, India

¹Department of Veterinary Anatomy, College of Veterinary and Animal Sciences,
SardarVallabh Bhai Patel University of Agriculture and Technology, Meerut-250110, India

Received: 07.10.2021; Accepted: 29.12.2021

ABSTRACT

The pelvic limb of goat was supplied with the arterial blood through the branches of the external iliac artery. The external iliac artery gave rise to the deep circumflex iliac artery and deep femoral artery, thereafter continued as the femoral artery in femoral canal. In its course, femoral artery gave off lateral circumflex femoral artery, saphenous artery, descending genicular artery and caudal femoral artery and continued as popliteal artery between the two heads of the gastrocnemius muscle.

Keywords: External iliac artery, Goat, Radiography

How to cite: Kumar, A., Jain, R.K. and Gahlot, P.K. (2023). Gross and radiographic studies on arterial supply of thigh region in goat. *The Haryana Veterinarian* 62(SI): 68-71.

Goat is known as 'Poor man's cow' in India and contribute to the livelihood security of the small and marginal farmers of the country. Any abnormality or obstruction of circulation of blood vessels of limbs may affects physical and productive efficiency of the goat. Accurate knowledge of normal topographic anatomy of blood vessels of limbs is essential for any clinical or surgical procedure on the area involved. As in mastectomy in goat, the ligation of external pudendal artery along with other vessels were essential to avoid hemorrhage which might be life threatening (Adam *et al.*, 2016). Femoral artery pulse strength was negatively associated with severity of mitral valve prolapse in dog (Tarnow *et al.*, 2004).

MATERIALS AND METHODS

The study was conducted on pelvic limbs of 4 adult goats collected from local abattoir soon after the slaughter. The external iliac artery was exposed and cannulated. The ligatures were applied around vessel to prevent the back flow of the solution. The arterial system was thoroughly flushed by injecting lukewarm normal saline solution. After thorough flushing, a radio-opaque suspension (20% w/v lead oxide in liquid soap solution) was injected through the cannula with steady digital pressure. After satisfactory filling, the limbs were radiographed in different views to reveal the course and branching pattern of the arteries. After that the specimens were kept in deep freeze for 48 hours to settle down the radio-opaque material. Then the limbs were dissected to confirm the radiographic observations. The dissected vessels were highlighted with the red enamel paint for photographic purpose.

*Corresponding author: dradityakumar10@gmail.com

RESULTS AND DISCUSSION

The blood vessels of pelvic limb in goat came primarily from the external iliac artery and to a lesser extent from the internal iliac artery.

The external iliac artery:

In present findings, the pelvic limb of goat was supplied with the arterial blood through the branches of the external iliac artery (Figs. 1, 2, 3, 6 and 7). Similar observation had been recorded in domestic mammals (Konig and Liebich, 2020). The external iliac artery of goat arose from the abdominal aorta at the level of sixth lumbar vertebra. Similar site of origin was reported in ox (Ghoshal, 1975 and Nickel *et al.*, 1981) and in buffalo (Singh, 1978). In dog, this vessel arose from the lateral surface of aorta ventral to the intervertebral disc between the sixth and seventh lumbar vertebrae (Evans and Lahunta, 2013) or at the level of sixth lumbar vertebra (Nickel *et al.*, 1981). In horse, this vessel arose ventral to the fifth lumbar vertebra (Ghoshal, 1975) or ventral to the fourth to fifth lumbar vertebra (Nickel *et al.*, 1981). The external iliac artery of goat coursed downward and backward over the sub-lumbar muscles and then craniomedial to the body of the ilium and gave rise to the deep circumflex iliac artery and deep femoral artery. The vessel then entered into the femoral canal as the femoral artery. Similar observation had been recorded in ox (Ghoshal, 1975). However, caudal abdominal artery also originated from external iliac artery along with deep circumflex iliac artery and deep femoral artery in sheep and ox (Nickel *et al.*, 1981). Whereas, Sisson and Grossman (1953) reported that it issued the circumflex iliac artery and external spermatic or cremaster

artery in ox and horse. In buffalo, the external iliac artery gave rise to the circumflex iliac artery, rami musculares and deep femoral artery (Singh, 1978). In horse, it gave rise to the deep circumflex iliac artery, cremasteric artery in male or uterine artery in female and deep femoral artery (Ghoshal, 1975), whereas Nickel *et al.* (1981) reported that this vessel gave rise to the deep circumflex iliac artery, cremasteric artery in male and uterine artery in female, caudal abdominal artery and deep femoral artery. Nickel *et al.* (1981) further reported that occasionally the pudendoepigastric trunk might also arise from the external iliac artery in this species. In dog, external iliac artery gave rise to the deep femoral artery and caudal abdominal artery (Evans and Lahunta, 2013 and Nickel *et al.*, 1981).

The deep circumflex iliac artery:

The deep circumflex iliac artery in goat was the first branch of external iliac artery and originated from the ventral surface of external iliac artery near the origin of later from abdominal aorta (Figs. 1 and 2). The origin of this vessel in horse was reported from the angle of origin of the external iliac artery (Nickel *et al.*, 1981). Ghoshal (1975) stated that it might arise have directly from the abdominal aorta in this species. However, in dog it arose directly from the abdominal aorta at the level of sixth lumbar vertebra (Evans and Lahunta, 2013). Nickel *et al.* (1981) stated that occasionally even in dog this vessel originated from the external iliac artery. The deep circumflex iliac artery of goat divided into the cranial and caudal branches. Similar observation had been reported in ox (Ghoshal, 1975; Nickel *et al.*, 1981), horse and dog (Nickel *et al.*, 1981), dog (Evans and Lahunta, 2013) and pampas deer (Vazquez *et al.*, 2017).

The deep femoral artery:

The deep femoral artery was a very stout branch which emanated from the medial face of the external iliac artery (Figs. 1, 3 and 6). Similar origin of deep femoral artery was reported in sheep, ox, horse and dog (Nickel *et al.*, 1981). Sisson and Grossman (1953) described in ox, horse and dog that the deep femoral artery originated from the femoral artery either by a common trunk with the prepubic artery or a little distal to it. In dog, it originated from the caudomedial surface of the external iliac artery (Evans and Lahunta, 2013). The deep femoral artery of goat gave off the pudendo-epigastric trunk and then continued as the medial circumflex femoral artery (Fig. 7) as earlier reported in ox and horse (Ghoshal, 1975 and Nickel *et al.*, 1981), dog (Evans and Lahunta, 2013) and buffalo (Singh, 1978). Sisson and Grossman (1953)

reported in ox that the deep femoral artery after a short course gave rise to the prepubic artery. Budras and Habel (2011) reported in bovine that the deep femoral artery originated along with the pudendoepigastric trunk from the external iliac artery.

The pudendoepigastric trunk:

The pudendoepigastric trunk in goat arose from the ventral face of the deep femoral artery close to the origin of later artery (Fig. 3). Similar origin was reported in sheep, ox, horse and dog (Nickel *et al.*, 1981). Sisson and Grossman (1953) and Budras and Habel (2011) reported in bovine that the pudendoepigastric trunk arose usually by a common trunk with deep femoral artery. (Nickel *et al.*, 1981) reported that this vessel might occasionally arise from the external iliac artery in horse. The pudendoepigastric trunk in goat divided into the caudal epigastric artery and external pudendal artery (Figs. 1 & 3). Similar observation had been recorded in ox, horse (Ghoshal, 1975; Nickel *et al.*, 1981) and dog (Evans and Lahunta, 2013).

The femoral artery:

The femoral artery of goat was the continuation of the external iliac artery after the latter gave off the deep femoral artery (Figs. 1, 3, 4, 5, 6 & 7) as reported earlier in buffalo (Singh, 1978) and horse (Ghoshal, 1975). Ghoshal (1975) and Nickel *et al.* (1981) in ox and Evans and Lahunta (2013) and Nickel *et al.* (1981) in dog stated that it was the continuation of the external iliac artery as the later gained the lacuna vasorum. Femoral artery of goat entered the femoral canal between the two heads of sartorius muscle and descended in the femoral canal cranial to the femoral vein and caudal to the saphenous nerve. It continued further to the popliteal region where it coursed between the two heads of the gastrocnemius muscle as the popliteal artery (Figs. 5 and 7) as earlier reported in ox (Mansour *et al.*, 2018). In its course, it gave off lateral circumflex femoral artery, saphenous artery, descending genicular artery and caudal femoral artery. Similar branching pattern had been reported in ox (Ghoshal, 1975; Nickel *et al.*, 1981). In horse, the femoral artery gave rise to the lateral circumflex femoral artery, saphenous artery, descending genicular artery and three muscular branches viz. proximal, middle and distal caudal femoral arteries (Nickel *et al.*, 1981). They further reported that the superficial circumflex iliac artery was given off the femoral artery in addition to the above branches in dog. However, Evans and Lahunta (2013) reported that the femoral artery in dog gave rise to the superficial circumflex iliac artery, lateral circumflex femoral artery,

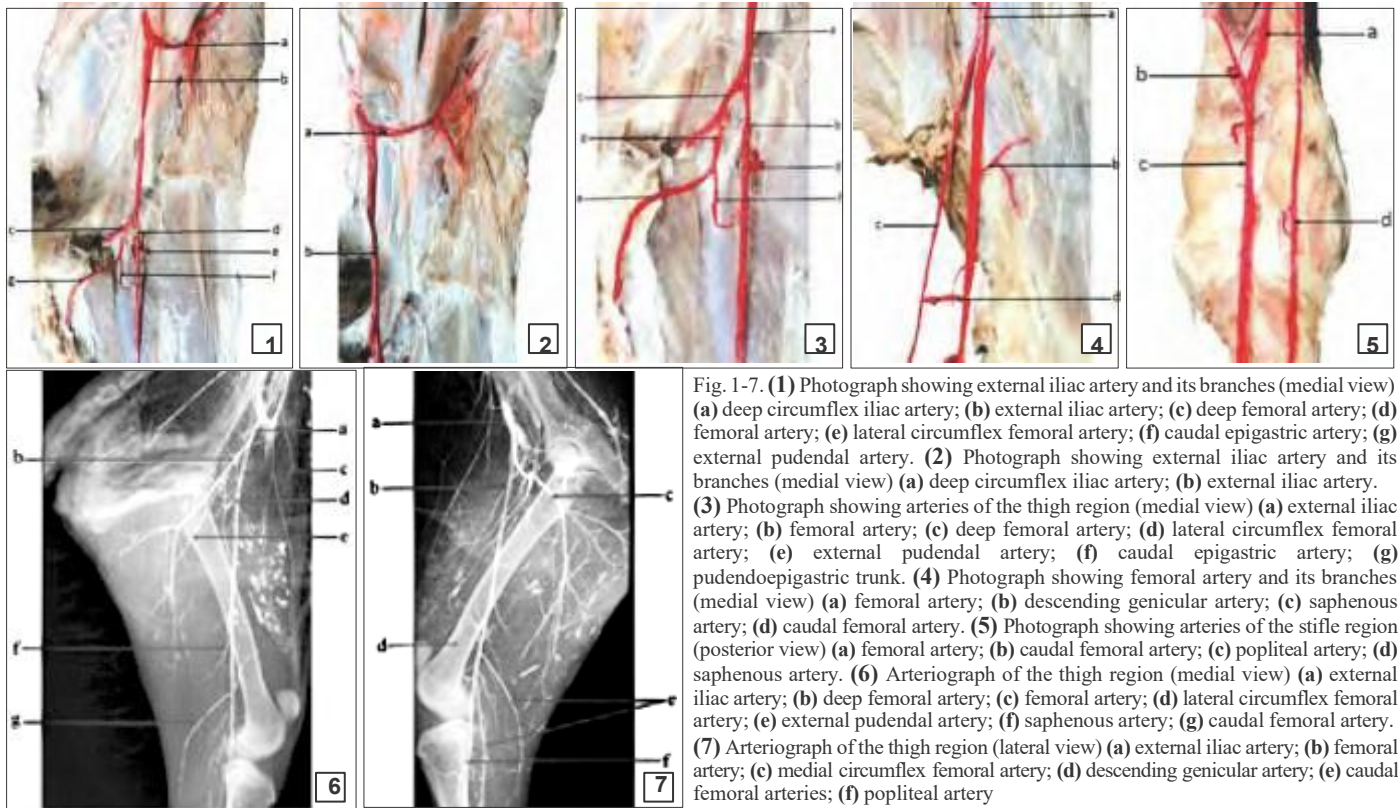


Fig. 1-7. (1) Photograph showing external iliac artery and its branches (medial view) (a) deep circumflex iliac artery; (b) external iliac artery; (c) deep femoral artery; (d) femoral artery; (e) lateral circumflex femoral artery; (f) caudal epigastric artery; (g) external pudendal artery. (2) Photograph showing external iliac artery and its branches (medial view) (a) deep circumflex iliac artery; (b) external iliac artery. (3) Photograph showing arteries of the thigh region (medial view) (a) external iliac artery; (b) femoral artery; (c) deep femoral artery; (d) lateral circumflex femoral artery; (e) external pudendal artery; (f) caudal epigastric artery; (g) pudendopigastria trunk. (4) Photograph showing femoral artery and its branches (medial view) (a) femoral artery; (b) descending genicular artery; (c) saphenous artery; (d) caudal femoral artery. (5) Photograph showing arteries of the stifle region (posterior view) (a) femoral artery; (b) caudal femoral artery; (c) popliteal artery; (d) saphenous artery. (6) Arteriograph of the thigh region (medial view) (a) external iliac artery; (b) deep femoral artery; (c) femoral artery; (d) lateral circumflex femoral artery; (e) external pudendal artery; (f) saphenous artery; (g) caudal femoral artery. (7) Arteriograph of the thigh region (lateral view) (a) external iliac artery; (b) femoral artery; (c) medial circumflex femoral artery; (d) descending genicular artery; (e) caudal femoral arteries; (f) popliteal artery

muscular branches, proximal caudal femoral artery saphenous artery, descending genicular artery, middle caudal femoral artery and distal caudal femoral artery.

The lateral circumflex femoral artery:

The lateral circumflex femoral artery in goat arose from the anterior face of the femoral artery within the femoral canal (Figs. 1, 3 and 6). Ghoshal (1975) stated that in ox and horse, this vessel was formerly called as cranial femoral artery. The lateral circumflex femoral artery of goat divided into the ascending and descending branches (Fig. 6). Similar branching pattern was reported in buffalo (Singh, 1978). However, the lateral circumflex femoral artery in ox divided into the ascending, descending and transverse branches (Ghoshal, 1975; Nickel *et al.*, 1981). Nickel *et al.* (1981) reported that the ascending branch was not present in horse.

The saphenous artery:

The saphenous artery of goat arose at the distal end of the femoral canal (Figs. 4, 5 and 6) as earlier reported in ox, horse and dog (Nickel *et al.*, 1981) and in camel (Jain *et al.*, 1996). In ox, the saphenous artery arose at the level of middle two third of the thigh (Ghoshal, 1975). This vessel in buffalo arose at the level of middle of the thigh (Singh, 1978). However, in dog it arose from the femoral artery just before the later disappeared under the semimembranosus muscle (Evans and Lahunta, 2013). The saphenous artery

in goat continued distally and divided into medial plantar artery and lateral plantar artery at the level of the sustentaculum tali.

The descending genicular artery:

The descending genicular artery in goat arose together with a muscular branch from the cranial aspect of the femoral artery. (Figs. 4 and 7). Similar origin had been recorded in dog (Evans and Lahunta, 2013). However, Nickel *et al.* (1981) reported in sheep, ox, horse and dog that it arose from the femoral artery a short distance before the origin of the saphenous artery. In ox and horse, it arose from the femoral artery at the level of distal one third of the thigh (Ghoshal, 1975). It originated from the cranial face of the femoral artery at the level of the insertion of the adductor muscle in buffalo (Singh, 1978) and in camel (Jain *et al.*, 1996).

The caudal femoral artery:

The caudal femoral artery of goat arose in caudal direction from femoral artery and was the most distal branch of the femoral artery before its transition into popliteal artery (Figs. 4, 5, 6 and 7). Similar description was given in sheep, goat, ox and horse (Ghoshal, 1975), ox (Sisson and Grossman, 1953; Ghoshal, 1975), horse (Sisson and Grossman, 1953; Ghoshal, 1975), buffalo (Singh, 1978), in camel (Jain *et al.*, 1996) and in alpaca (Angulo *et al.*, 2013). However, distal caudal femoral

artery was the last branch of the femoral artery in dog before its transition into popliteal artery (Evans and Lahunta, 2013).

REFERENCES

- Adam, Z.A., Ragab, G.A., Awaad, A.S., Tawfiek, M.G. and Abdel Maksoud, M.K.M. (2016). Anatomical and radiographical studies on the arterial supply of the udder in goat and their surgical importance. *Beni-Suef Univ. J. Basic Appl. Sci.* **5(3)**: 291-298.
- Angulo, A.J., Sato, S.A., Navarrete, Z.M. and Cisneros, S.J. (2013). Arterial supply of the pelvic limb of the alpaca (*Vicugna pacos*). *Rev. Inv. Vet. Peru.* **24(1)**: 1-15
- Budras, K.D. and Habel, R.E. (2011). Bovine Anatomy (2nd Edn.), Schlutersche Verlagsgesellschaft MBH & Co. KG, Germany.
- Evans, H.E. and de Lahunta, A. (2013). Miller's anatomy of the dog (4th Edn.), Elsevier Saunders, Missouri, pp. 487-493.
- Ghoshal, N.G. (1975). In: The anatomy of the domestic animals (5th Edn.), Sisson and Grossman, Vol. 1 & 2, W.B Saunders Co., Philadelphia, USA. pp. 182-225.
- Jain, R.K., Dhingra, L.D. and Nagpal, S.K. (1996). The femoral artery and its branching pattern in camel (*Camelus dromedarius*). *J. Cam. Prac. Res.* **6**: 27-31.
- Konig, H.E. and Liebich, H.G. (2020). Veterinary anatomy of domestic animals (7th Edn.), Georg Thieme Verlag Stuttgart, New York, p. 490.
- Mansour, M., Wilhite, R. and Rowe, J. (2018). Guide to ruminant anatomy (1st Edn.), Willey Blackwell, USA, pp. 238-241.
- Nickel, R., Schummer, A. and Seiferle, E. (1981). The anatomy of the domestic animals (1st Edn.), Vol. 3, Verlag Paul Parey, Berlin and Hamburg, pp. 133-145.
- Singh, S.R. (1978). Gross anatomical and radiological investigations of blood vessels of pelvic limb of buffalo (*Bubalus bubalis*). M.V.Sc. thesis submitted to Haryana Agriculture University, Hisar, Haryana.
- Sisson, S. and Grossman, J.D. (1953). The anatomy of the domestic animals (4th Edn.), W.B. Saunders Co., Philadelphia, USA. pp. 581-605.
- Tarnow, I., Olsen, L.H., Jensen, M.B., Pedersen, K.M. and Pederson, H.D. (2004). Determinants of weak femoral artery pulse in dogs with mitral valve prolapse. *Res. Vet. Sci.* **76(2)**: 113-120.
- Vazquez, N., Rios, C., Sorriba, V. and Perez, W. (2018). Arterial distribution to the pelvic cavity and pelvic limb in the pampas deer (*Ozotoceros bezo articus*). *Anat. Histol. Embryol.* **47(2)**: 133-139.

CONTRIBUTORS MAY NOTE

- Research/Clinical articles are invited for next issue from the Scientists/Veterinarians engaged in Veterinary Profession.
- Please follow strictly the format of 'The Haryana Veterinarian' for manuscript writing/submission.
- Please pay processing fee of Rs. 1000/- online in the account of Dean, College of Veterinary Sciences, along with each article.
- After revision, please return the revised manuscript and rebuttal at the earliest.
- Please mention your article reference number in all correspondence for a quick response.
- We solicit your co-operation.
- All correspondence should be addressed to 'The Editor', Haryana Veterinarian, Department of Veterinary Parasitology, College of Veterinary Sciences, LUVAS, Hisar-125004.

Editors