

COMPARATIVE EVALUATION OF OXIDATIVE STRESS PARAMETERS FOR UROLITHIASIS MANAGEMENT IN MALE BUFFALO CALVES BY ULTRASOUND GUIDED AND CONVENTIONAL TUBE CYSTOSTOMY SURGICAL TECHNIQUE

ANKIT DANGI, SANDEEP KUMAR*, RAJESH KUMAR¹, R.N. CHAUDHARY and LOKENDER SINGH¹

Department of Veterinary Surgery and Radiology,

¹Department of Veterinary Physiology and Biochemistry, College of Veterinary Sciences, Lala Lajpat Rai University of Veterinary and Animal Sciences (LUVAS), Hisar-125004, India

Received: 13.10.2021; Accepted: 02.12.2021

ABSTRACT

Twelve male buffalo calves had been taken with history of complete urine retention in the present study but having intact urinary bladder confirmed by ultrasonography. In group I and II six animals were taken and in group I ultrasound guided and in group II conventional tube cystostomy was done. The blood samples were evaluated for oxidative stress Malondialdehyde (MDA) and reduced Glutathione (GSH) preoperatively, after surgery, at 6 hours, 24 hours, 3rd and 14th day. Both MDA and GSH varied significantly after 6 and 24 hours, however, MDA also varied on 3rd day in between the groups and more significant variation was found in group II at different time intervals within the group showing less oxidative stress in group I. Oxidative stress was less in ultrasound guided tube cystostomy may be because of it is less invasive surgical technique in comparison to conventional tube cystostomy.

Keywords: Male buffalo calves, Oxidative stress, Ultrasound guided tube cystostomy

How to cite: Dangi, A., Kumar, S., Kumar, R., Chaudhary, R.N. and Singh, L. (2023). Comparative evaluation of oxidative stress parameters for urolithiasis management in male buffalo calves by ultrasound guided and conventional tube cystostomy surgical technique. *Haryana Vet.* 62(SI): 78-80.

Urolithiasis is disease of great economic importance in young male buffalo calves in Haryana state because its leads to mortality and economical loss to animal owners by decreasing breeding value of animal. Medical dissolution of calculi with tube cystostomy technique is effective treatment for the management of urine retention in small ruminants (Ewoldt *et al.*, 2006). Ultrasound guided tube cystostomy is a non-invasive, safe and reliable technique with minimal complications for urolithiasis management in male buffalo calves (Niwas *et al.*, 2021). Constable *et al.* (2017) found that multiple factors are responsible for the renal epithelium damage like free radicals and any type of bacterial infection etc. Gawel *et al.* (2004) found that lipid peroxidation plays an important role in initial stage of stone formation. Thakur (2019) found that there is elevation of multiple oxidative stress parameters in urolithiasis affected male buffalo calves.

The imbalance between the antioxidants and pro-oxidants can be qualified and quantified by measuring the activities of anti-oxidative enzymes such as superoxide dismutase, glutathione peroxidase, catalase, redox state of reduced glutathione (GSH), MDA and the products of lipid peroxidation (Thamiselven *et al.*, 2000). Therefore, present study was carried out for evaluation of oxidative stress parameters in urolithiasis affected male buffalo calves treated by ultrasound guided and conventional tube cystostomy surgical technique.

*Corresponding: drskgvvet@gmail.com

MATERIALS AND METHODS

Twelve clinical cases of male buffalo calves presented to Department of Veterinary Surgery and Radiology; LUVAS with history of complete retention of urine. All the animals had intact urinary bladder, confirmed by ultrasonography divided equal into two groups having six animals in each group. Ultrasound guided tube cystostomy was done in group I and conventional tube cystostomy was done in group II. Surgical procedure for both the technique was done by method of Dangi *et al.* (2022 a & b). Three ml blood samples were taken preoperatively, after surgery, 6 hour, 24 hour, 3rd and 14th day for oxidative stress parameters estimation which was measured in plasma. Malondialdehyde (MDA) production was determined in terms of membrane peroxidative damage in erythrocytes by the method of Ohkawa *et al.* (1979). Reduced glutathione (GSH) activity in plasma was measured by method of Beutler *et al.* (1963). Statistical analysis was conducted via SPSS 20 software. Two way ANOVA test was done in between the groups at different time intervals. Pair wise comparison was done using Duncan Test.

RESULTS AND DISCUSSION

The MDA and GSH values at different time interval in male buffalo calves with retention of urine are presented in Table 1. The values of MDA in group-II were significantly ($p < 0.05$) higher in comparison to the values in group-I after 6 hours, 24 hours and 3rd day. In group-II when compared within the group, MDA value recorded after 6 hours was

Table 1

Mean±SE values of MDA and GSH in buffalo calves of group I and II suffering from obstructive urolithiasis at different time intervals

Groups	Parameters	Preoperatively	After surgery	After 6 hours	After 24 hours	On 3rd day	On 14th day
Group I	MDA(μmol/L plasma)	7.97±1.14	8.28±1.55	8.62±1.23 ^a	6.88±1.51 ^a	5.97±1.22 ^a	5.28±1.02
Group II	MDA(μmol/L plasma)	8.08±1.12 ^A	10.37±1.3 ^{AB}	13.63±1.67 ^{BB}	11.37±1.34 ^{BA}	10.85±1.83 ^{BAB}	8.98±1.64 ^A
Group I	GSH(μmol/L plasma)	11.97±2.74	10.95±2.31	11.28±2.59 ^a	12.34±3.47 ^a	14.77±3.64	15.75±3.21
Group II	GSH(μmol/L plasma)	11.4±2.14 ^A	9.2±2.52 ^{AB}	6.35±1.24 ^{BB}	8.45±1.85 ^{BAB}	11.12±2.08 ^A	13.53±2.38 ^A

Mean with different superscripts vary significantly (P<0.05). Superscripts A, B, represents difference with in groups. Superscripts a, b represents difference in between groups.

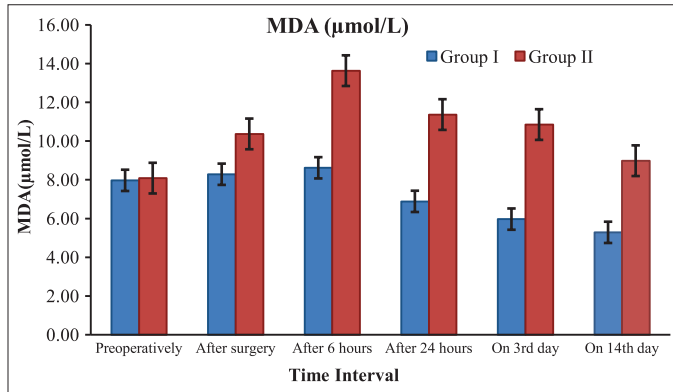


Fig. 1. Mean±SE values of Malondialdehyde (MDA) (μmol/L) at different time intervals in male buffalo calves of both the groups suffering from obstructive urolithiasis

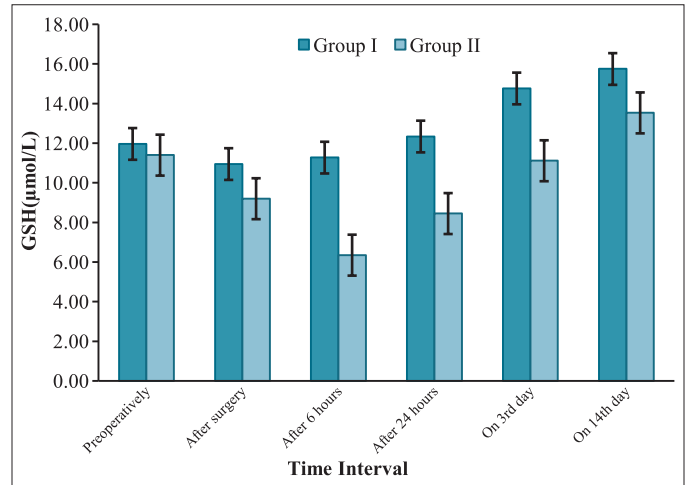


Fig. 2. Mean±SE values of Reduced Glutathione (GSH) (μmol/L) at different time intervals in male buffalo calves of both the groups suffering from obstructive urolithiasis

significantly higher than the preoperative and 14th day value (Fig. 1). GSH values recorded for group-II were significantly (p<0.05) lower in comparison to the values recorded for group-I after 6 hours and 24 hours when compared in between the groups. In group-II when compared within the group, the value recorded after 6 hours was significantly lower than the preoperative, 3rd and 14th day value (Fig. 2). No significant difference was found within the group-I for MDA and GSH value.

Oxidative stress is due to over production of various reactive nitrogen species and reactive oxygen species during inflammation, infection, trauma and stress. Panigrahi *et al.* (2017) concluded MDA, a product of lipid peroxidation process to be increased by induction of excessive reactive oxygen species by renal ischemia. The concentration of MDA in blood after 6 hours, 24 hours and 3rd day were significantly higher in conventional tube cystostomy group than that of ultrasound guided tube cystostomy group. An opposite trend of variation has been noticed with GSH levels. The concentration of reduced glutathione in both the groups was at low level in blood which indicated that during the urethral obstruction the calf was under stress and suffered with inflammation of tissue (bladder wall and urethra). These oxidative stress parameters gradually increased at different intervals and reached to peak level by the end of observation which

suggested the progressive recovery of the calf from the disease condition and thus a decrease in oxidative stress. However, GSH reduced significantly after 6 hours in conventional tube cystostomy group but non-significantly in ultrasound guided tube cystostomy group. The concentration of GSH in blood after 6 hours and 24 hours for the conventional method was significantly lower than that of ultrasound guided tube cystostomy. This can be related to more stress, inflammation, infection; trauma and pain in conventional/open method of tube cystostomy as compared to ultrasound guided tube cystostomy. The present findings are in agreement with Thakur (2019) who reported increased level of MDA value in urolithiasis affected male buffalo calves. Ceban *et al.* (2016) reported that treatment of urolithiasis patients leads to decrease in the oxidative stress. Ultrasonographic guided tube cystostomy has been considered a reliable and safe technique for urolithiasis affected male buffalo calves (Niwas *et al.*, 2021).

Increase in GSH and decrease in MDA at different time intervals after surgery was faster in ultrasound guided tube cystostomy group as compared to conventional tube cystostomy group. Thus, the study concludes that ultrasound

guided tube cystostomy produces less oxidative stress in comparison to conventional tube cystostomy in male buffalo calves for management of urolithiasis.

REFERENCES

- Beutler, E. (1963). Improved method for the determination of blood glutathione. *J. Lab. Clin. Med.* **61**: 882-888.
- Ceban, E., Banov, P., Galescu, A. and Botnari, V. (2016). Oxidative stress and antioxidant status in patients with complicated urolithiasis. *J. Med. Life.* **9(3)**: 259-262.
- Constable, P.D., Hinchcliff, K.W., Done, S.H. and Grunberg, W. (2017). *Veterinary Medicine: A Textbook of the Diseases of Cattle, Sheep, Goats and Horses*, (11th Edn.), WB Saunders Co, Philadelphia, PA, USA. pp. 386-414.
- Dangi, A., Kumar, S., Chaudhary, R.N., Niwas, R. and Bangar, Y. (2022a). Comparative study of ultrasound guided and conventional tube cystostomy procedure for managing urine retention in male buffalo calves. *Haryana Vet.* **61(2)**: 261-264.
- Dangi, A., Kumar, S., Sharma, M., Chaudhary, R.N. and Niwas, R. (2022b). Study of urine analysis in ultrasound guided and conventional tube cystostomy for surgical management of urine retention in male buffalo calves. *Pharma Innovation.* **SP-11(5)**: 1700-1703.
- Ewoltdt, J.M., Anderson, D.E., Miesner, M.D. and Saville, W.J. (2006). Short and long term outcome and factors predicting survival after surgical tube cystostomy for treatment of obstructive urolithiasis in small ruminants. *Vet. Surg.* **35(5)**: 417-422.
- Gawel, S., Wardas, M., Niedworok, E. and Wardas, P. (2004). MDA as a lipid peroxidation marker. *Wiad. Lek.* **57**: 453-455.
- Niwas, R., Saharan, S., Priyanka and Kumar, S. (2021). Ultrasound guided tube cystostomy in buffalo calves. *Pharma. Innovation.* **10(1)**: 42-45.
- Ohkawa, H., Ohishi, N. and Yagi, K. (1979). Assay for lipid peroxides in animal tissues by thiobarbituric acid reaction. *Anal Biochem.* **95(2)**: 351-8.
- Panigrahi, P.N., Dey, S., Sahoo, M. and Dan, A. (2017). Antiurolithiatic and antioxidant efficacy of *Musa paradisiacal* pseudostem on ethylene glycol-induced nephrolithiasis in rat. *Indian J. Pharm.* **49(1)**: 77-83.
- Thakur, N., Choudhary, S.G., Chethan and Dey, S. (2019). Urokinase alteration and its correlation with disease severity and oxidative /nitrosative stress in buffalo calves with obstructive urolithiasis. *Res. Vet. Sci.* **127**: 18-26.
- Thamilselvan, S., Byer, K.J., Hackett, R.L. and Khan, S.R. (2000). Free radical scavengers, catalase and superoxide dismutase provide protection from oxalate-associated injury to LLC-PK 1 and MDCK cells. *J. Urol.* **154(1)**: 224-229.

CONTRIBUTORS MAY NOTE

- Research/Clinical articles are invited for next issue from the Scientists/Veterinarians engaged in Veterinary Profession.
- Please follow strictly the format of 'The Haryana Veterinarian' for manuscript writing/submission.
- Please pay processing fee of Rs. 1000/- online in the account of Dean, College of Veterinary Sciences, along with each article.
- After revision, please return the revised manuscript and rebuttal at the earliest.
- Please mention your article reference number in all correspondence for a quick response.
- We solicit your co-operation.
- All correspondence should be addressed to 'The Editor', Haryana Veterinarian, Department of Veterinary Parasitology, College of Veterinary Sciences, LUVAS, Hisar-125004.

Editors