

**SURGICAL RETRIVAL OF GASTROINTESTINAL FOREIGN BODIES IN DOGS- A REPORT OF FIVE CASES**SANDEEP SAHARAN, DINESH<sup>1</sup>, ANJU POONIA\*<sup>1</sup>, RAM NIWAS<sup>1</sup>, SANDEEP KUMAR<sup>1</sup>,  
PRIYANKA<sup>1</sup> and AMIT KUMAR<sup>1</sup>Veterinary Clinical Complex, <sup>1</sup>Department of Veterinary Surgery and Radiology,  
College of Veterinary Sciences, LUVAS, Hisar, Haryana

Received: 08.04.2022; Accepted: 18.07.2022

**SUMMARY**

A total of five clinical cases of gastro-intestinal tract obstruction in dogs were brought to Veterinary Clinical Complex, LUVAS, Hisar with the history of frequent vomiting, restlessness, blood-tinged scanty loose faeces with dyschezia and obstipation, anorexia, debility, depression and abdominal distension. Clinical examination revealed pain in three out of five dogs on palpation. In one case round hard ball like structure was felt in stomach. Radiography was performed for the diagnosis and one case was confirmed by ultrasonography. Surgical management was done in all cases and foreign bodies were retrieved. All the dogs recovered uneventfully.

**Keywords:** Enterotomy, Foreign body, Gastro intestinal, Gastrotomy, Radiography, Ultrasonography.

**How to cite:** Saharan, S., Dinesh, Poonia, A., Niwas, R., Kumar, S., Priyanka and Kumar, A. (2023). Surgical retrieval of gastrointestinal foreign bodies in dogs- a report of five cases. *Haryana Vet.* 62(SI): 108-109.

The incidence of ingestion of foreign body is quite common in dogs due to indiscriminate feeding habits and worm load may lead to allotriophagia. Due to indiscriminate eating habits, ingested foreign bodies pass uneventfully through the gastrointestinal tract results in to variable symptoms. The common clinical signs during foreign body ingestion are salivation, retching, gagging, vomiting, regurgitation, anorexia, pain, respiratory distress and restlessness (Gianella *et al.*, 2009). Pet animals with gastrointestinal foreign bodies may present a variety of clinical signs depending on the location, the degree and the duration of the obstruction (Hayes, 2009). Therefore, early diagnosis and immediate surgical intervention is required to remove such foreign bodies to avoid further complications.

Five male dogs of varying age groups (9 months to 8 years) were brought with the history of frequent vomiting, restlessness, blood-tinged scanty loose faeces with dyschezia and obstipation, anorexia, debility, depression and abdominal distension to the VCC, LUVAS, Hisar. Clinical examination revealed pain in three out of five dogs on palpation. In one case round hard ball like structure was felt in stomach. Radiography was performed for the diagnosis while one case was confirmed with the help of ultrasonography. Lateral abdominal radiographs (three case) and Ventrolateral and lateral (one case) were obtained for confirmatory diagnosis. In four dogs radiopaque foreign body was clearly visible in the small intestine (Fig. 1,3,5,7). In one case where ultrasonography was performed for confirmation as radiographic findings were normal due to fully filled stomach and consistency of foreign body. On ultrasonography, a hyperechoic image of foreign body inside the gastric lumen was evident (Fig. 9).

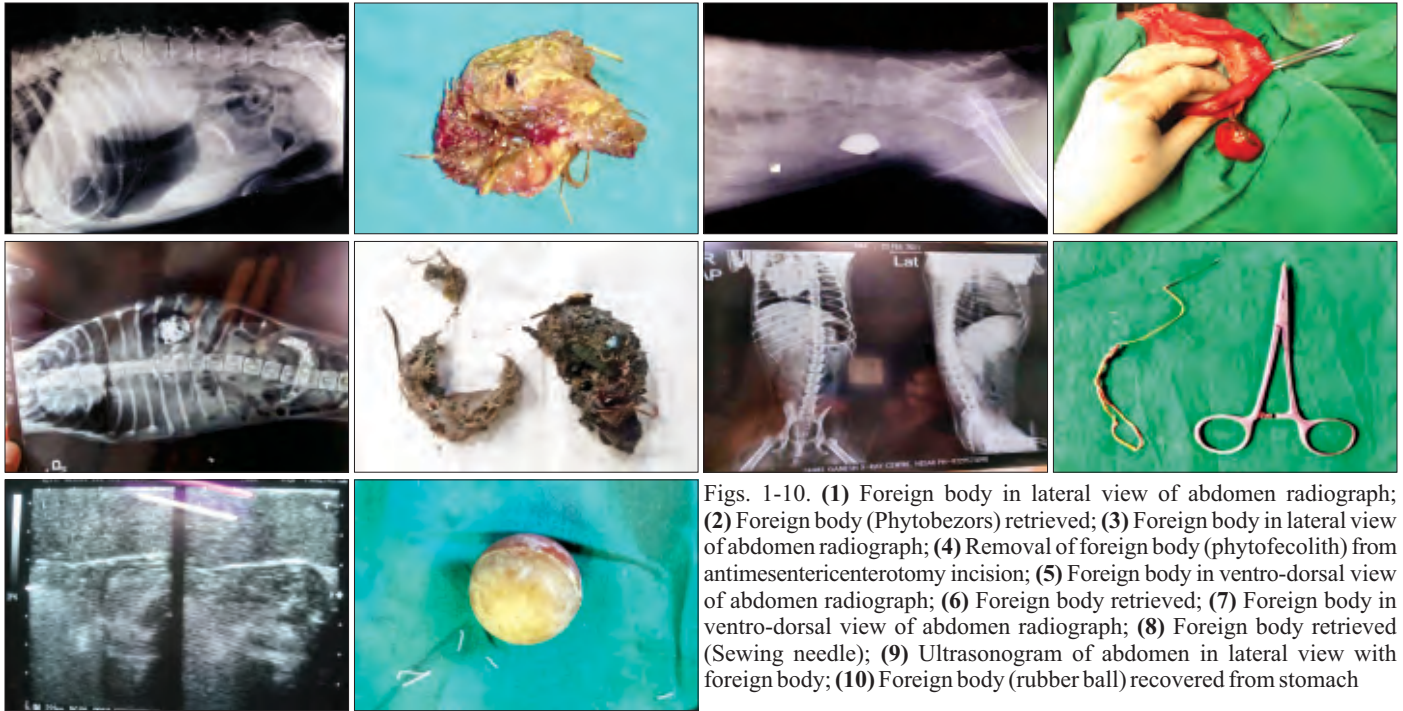
The ventral abdomen of dog was prepared for aseptic surgery and enterotomy was performed in four

cases; while, gastrotomy was performed in one case. The dogs were anaesthetized with balanced anaesthetic protocol using atropine @0.04 mg/kg b.wt. and xylazine @1mg/kg b.wt. intramuscular as preanaesthetic agent and induction of anaesthesia was done with propofol @4mg/kg b.wt. intravenous till effect, then maintained by isoflurane @1-2 % with 100% oxygen. Mid-ventral laparotomy was performed according to the location of foreign body. The obstructing foreign bodies were palpated and exteriorized from intestine after placing intestinal clamps on the antimesenteric border of intestine and at greater curvature of stomach after giving a longitudinal incision directly over the foreign body. The foreign bodies were removed from intestinal loops and gastric fundus (Fig. 2,4,6,8,10). The surgical incision was closed by two rows of inverting suture pattern using chromic catgut #3-0. The abdominal muscles were opposed with vicryl #1 in lockstitch manner whereas skin was opposed with silk #1 by horizontal suture mattress.

Post-operatively, all operated dogs were given: dextrose normal saline @60-80 mg/kg b.wt. i.v. o.d., ceftriaxone with tazobactam @20 mg/kg b.wt. i.m. b.i.d., metronidazole @20 mg/kg b.wt. i.v. o.d, ranitidine @2 mg/kg b.wt. i.m. o.d. and metaclopramide @0.5 mg/kg b.wt. i.m. o.d. for 5 days. Carprofen was given @4 mg/kg b.wt. i.m. o.d. at least for three days. Daily antiseptic dressing of surgical wound was done and skin sutures were removed on 12<sup>th</sup> post-operative day. Small quantity of liquid/semisolid diet of dog was offered 5-6 times per day on 3<sup>rd</sup> post-operative day and normal diet was given from 10<sup>th</sup> post-operative day. Uneventful recovery was observed in all the five cases.

Canines are quite curious and have a habit of playing and eating non-food items called as foreign body. Gastro intestinal foreign body in dogs is one of the common life threatening ailments. The course and onset of disease

\*Corresponding author: anjupooniavs@gmail.com



Figs. 1-10. (1) Foreign body in lateral view of abdomen radiograph; (2) Foreign body (Phytobezors) retrieved; (3) Foreign body in lateral view of abdomen radiograph; (4) Removal of foreign body (phytofocolith) from antimesentericenterotomy incision; (5) Foreign body in ventro-dorsal view of abdomen radiograph; (6) Foreign body retrieved; (7) Foreign body in ventro-dorsal view of abdomen radiograph; (8) Foreign body retrieved (Sewing needle); (9) Ultrasonogram of abdomen in lateral view with foreign body; (10) Foreign body (rubber ball) recovered from stomach

depends on where the obstruction develops and nature of obstruction, whether this is partial or complete (Tripathi *et al.*, 2010). These are found to be lodged anywhere in the gastrointestinal tract i.e. mouth cavity, oesophagus, stomach and intestine (Pillai *et al.*, 2006). In the present study four cases were having foreign body in the small intestine, while one case was having gastric foreign body. Approximately 50% of foreign objects passed to stomach, are retained in the stomach and causes vomiting (Leib, 1997). Mechanical obstruction is the most common indication for intestinal surgery in dogs (Rao *et al.*, 2010). Obstruction of the lumen might occur with foreign bodies (Singh *et al.*, 2004), intussusception (Wilson and Burt, 1974), impacted faecal material (Saini *et al.*, 2002) and intramural intestinal haematoma (Moore and Carpenter, 1984). The abdominal palpation gives some clue for the diagnosis. Radiography is commonly used in suspected gastrointestinal foreign bodies but plain abdominal radiographs may be unremarkable in many cases and abdominal ultrasonography may be required to confirm the diagnosis (Hobday *et al.*, 2014). Depending on the type and degree of obstruction, the intestinal foreign bodies can be managed by either medicinal treatment or surgical intervention. Diagnostic imaging like radiography, ultrasonography etc. provide the information about shape, size and location of foreign body. Radiolucent objects may require contrast radiography or endoscopy to confirm a diagnosis. Sewing needle, phytobezoars, rubber ball, phytofecoliths and plastic material were retrieved from these cases. One dog, on which gastrotomy was performed recovered one week earlier than the other dogs.

### CONCLUSION

In conclusion, gastrointestinal tract obstructions are

the emergencies which should be approached in early stages to prevent complications and mortality.

### REFERENCES

- Gianella, P., Pfammatter, N.S. and Burgener, I.A. (2009). Oesophageal and gastric endoscopic foreign body removal: complications and follow-up of 102 dogs. *J. Small Anim. Pract.* **50(12)**: 649-654.
- Hayes, G. (2009). Gastrointestinal foreign bodies in dogs and cats: a retrospective study of 208 cases. *J. Small Anim. Pract.* **50(11)**: 576-583.
- Hobday, M.M., Pachtlinger, G.E., Drobotz, K.J. and Syring, R.S. (2014). Linear versus non-linear gastrointestinal foreign bodies in 499 dogs: Clinical presentation, management and short term outcome. *J. Small Anim. Pract.* **55**: 560-565.
- Leib, M.S. (1997). Diseases of stomach. In: Practical Small Animal Internal Medicine. Leib, M.S. and Monroe, W.E. (Ed). W.B. Saunders Company, Philadelphia. pp. 653-684.
- Moore, R. and Carpenter, J. (1984). Intramural intestinal haematoma causing obstruction in three dogs. *J. Am. Vet. Med. Assoc.* **184**: 186-188.
- Pillai, S., Upadhye, S.V., Panchbhai, V.S., Patil, S.N., Dhakate, M.S., Raghuvanshi, D.S. and Dhoot, V.M. (2006). Oesophageal obstruction in a dog- A case report. *Indian. J. Field Vet.* **2**: 20-21.
- Rao, T.M., Bharathi, S. and Raghavender, K.B.P. (2010). Surgical correction of intestinal obstruction in dogs- A report of eight cases. *Intas Polivet.* **11**: 319-325.
- Singh, H.N., Jaiswal, S., Singh, S.V. and Singh, B. (2004). Successful surgical management of unusual intestinal obstruction by a feeding bottle nipple. *Indian J. Vet. Surg.* **25**: 59.
- Saini, N.S., Sobti V.K., Bansal, P.S., Mahajan, S.K. and Anand, A. (2002). A rare case of chronic intestinal obstruction in a dog. *Indian J. Vet. Surg.* **23**: 54.
- Tripathi, A.K., Soodan, J.S. and Kushwaha, R.B. (2010). Gastric foreign body syndrome in a golden retriever dog. *Intas Polivet.* **11(2)**: 305-306.
- Wilson, G.P. and Burt, J.K. (1974). Intussusception in the dog and cat: A review of 45 cases. *J. Am. Vet. Med. Assoc.* **164**: 515-518.