

SURGICAL MANAGEMENT OF VAGINAL FIBROLEIOMYOMA IN A HOLSTEIN FRIESIAN COW – A CASE REPORT

G. MONICA*, S. VIGNESHWARAN, M. THANGAPANDIYAN, N. PAZHANIVEL¹,
C. INBARAJ, T. RAMAD, CHANDRASEKARAN and A. VIJAYARAJAN
Veterinary Clinical Complex, Veterinary College and Research Institute, Udumalpet-642126, Tiruppur
¹Dept. of Veterinary Pathology, Madras Veterinary College, Chennai-600007, Tamil Nadu

Received: 08.07.2022; Accepted: 27.10.2022

SUMMARY

A Holstein Friesian cow at its sixth calving was presented with the history of progressive swelling on the posterior vagina and vulval lips along with maggot wound. The cow was previously treated for maggot wound infestation but the condition was not resolved. On clinical examination, the temperature, heart rate, respiratory rate were in normal range, highly inflamed irregular growth with necrotic tissues and maggots were observed on the vulval lips. On suggestion by Fine Needle Aspiration Cytology (FNAC), surgical correction was performed under standard protocol. Tissue sample was examined histopathologically and confirmed as vaginal fibroleiomyoma. The cow recovered uneventfully post-surgery.

Keywords: Cow, Histopathology, Immunohistochemistry, Vaginal fibroleiomyoma

How to cite: Monica, G., Vigneshwaran, S., Thangapandiyam, M., Pazhanivel, N., Inbaraj, C., Ramad, T., Chandrasekaran and Vijayarajan, A. (2023). Surgical management of vaginal fibroleiomyoma in a holstein friesian cow- A case report. *Haryana Vet.* 62(SI): 141-143.

Tumors of the bovine vagina include fibroma, fibrosarcoma, leiomyoma, hemangioma, lymphosarcoma and carcinoma (Roberts, 1971). These tumors do not cause infertility but may be a cause of dystocia during parturition and interfere with the normal physiology when there is space occupying lesion causing urinary obstruction. In animals, a few reports of spontaneous fibroleiomyoma arising from the vagina or other parts of the genital tract of animals have been described by Cooper and Valentine (2002). The present case study describes surgical management of vaginal fibroleiomyoma in a Holstein Friesian cow along with histopathological changes and immunohistochemical expression.

A Holstein Friesian cow was brought with the history of progressive swelling on the posterior vagina and vulval lips along with maggot wound. On enquiry, the cow calved 2 months ago by assisted delivery following which the swelling developed gradually along with maggot infestation. The cow was previously treated for maggot wound since two weeks by topical spray but the condition was not resolved. On clinical examination, temperature, heart rate, respiratory rate were in normal range. Examination of reproductive tract revealed highly inflamed irregular growth noticed on the posterior part of vagina extending upto vulval lips accompanied by necrosis and swelling along with maggots noticed on the surface (Fig. 1). Fine needle aspiration cytology using Leishman-Giemsa staining technique revealed presence of irregular shaped Fibrocytes suggestive of vaginal fibroma.

Epidural anesthesia was achieved by using 2% Lignocaine at the sacrococcygeal junction. The tumor mass

was circumscribed carefully after ligation of blood vessels (Fig. 2) followed by excision of the mass. Vaginal mucosa apposed with skin of vulval lips using Polyglactan 910 (Size 1) by simple interrupted suture pattern (Fig. 3). Povidone Iodine-Sucralfate ointment was applied over the surgical site to avoid secondary bacterial infection. Inj. Streptopenicillin (Dicrysticin-S®, Zenex Animal Health Pvt Ltd.) 5 g IM; Inj. Meloxicam (Melocox®, Heilen Animal Health) @ 0.5 mg/Kg BW IM and Inj. Chlorpheniramine maleate (Anistamin®, Intas Pharmaceuticals Pvt Ltd.) @ 0.5 mg/Kg BW IM were administered for 7 days. Surgical wound dressing with Povidone Iodine-Sucralfate ointment was done twice daily for one week. Complete healing of surgical wound was observed in 15 days after surgery and no signs of recurrence were observed.

Representative tissue sample (Fig. 4) from the excised mass was fixed in 10% neutral buffered formalin and the sectioned slides were stained with Hematoxylin and Eosin for histopathological analysis. Picrosirius red histochemical staining was done to differentiate muscle and connective tissue components. Immunohistochemistry (IHC) was done using vimentin and smooth muscle actin 1 (SMA -1) antibodies following manufacturer protocol (Pathn Situ, USA).

Microscopical examination revealed that the mass was non-encapsulated, arose from the muscle layer, composed of connective tissue and smooth muscle cells components. In some areas neoplastic cells were arranged in interlacing bundles of spindle shaped smooth muscle fibres with eosinophilic cytoplasm and the cells had fusiform, round or elongated nucleus with visible

*Corresponding author: drmonica31890@gmail.com

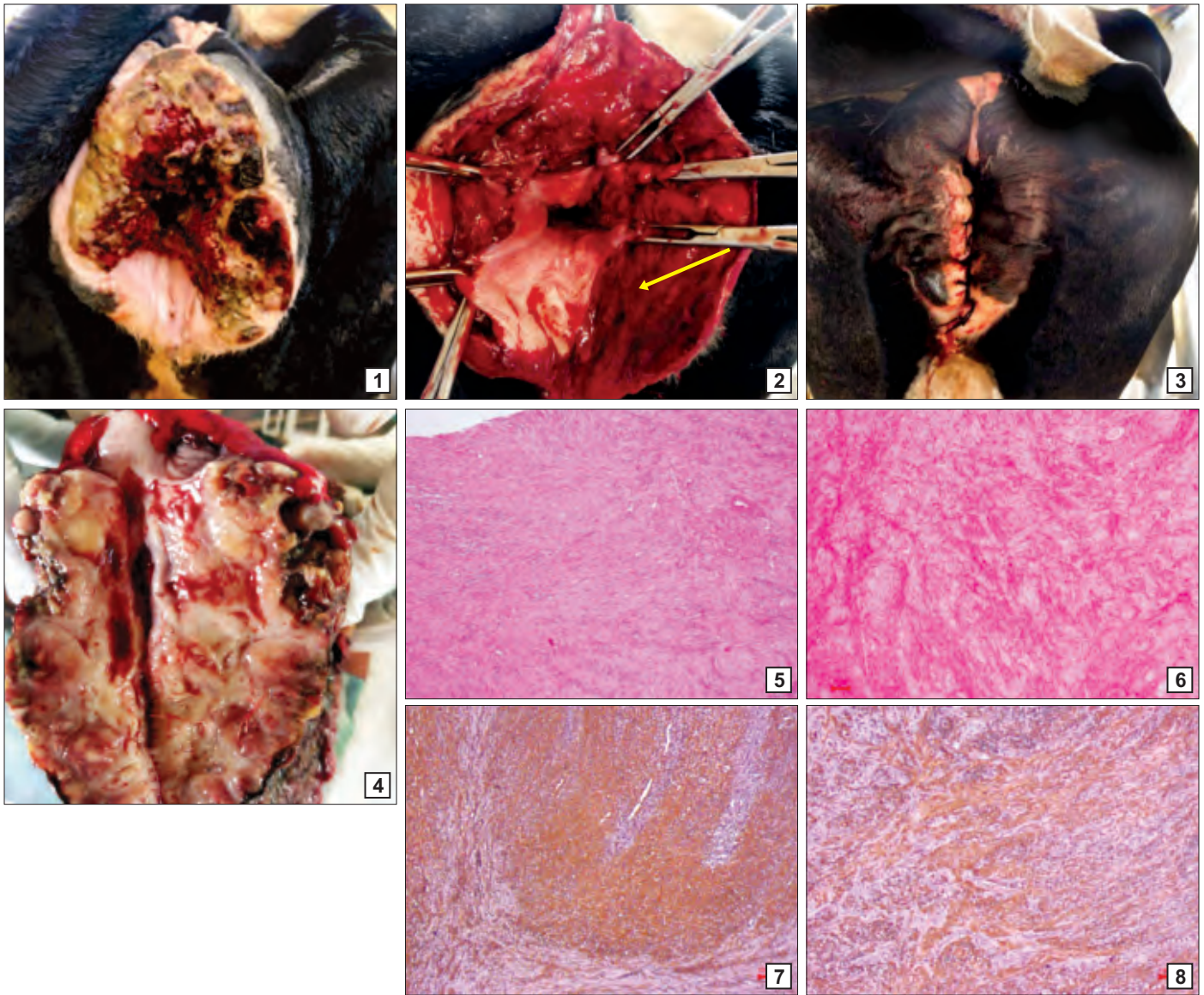


Fig. 1-8. (1) Tumor mass on the vagina along with maggots; (2) Arrows shows patent vaginal passage after excision of the tumor mass; (3) Apposition of vaginal mucosa with skin by simple interrupted suture; (4) Tumor mass after excision halved to reveal the mediastinum; (5) Vaginal fibroleiomyoma with minimal cellular pleomorphism and mitosis. H& E, bar=100 μ m; (6) Vaginal fibroleiomyoma. Intermittent collagen layer. Picrosirius red staining, bar = 20 μ m; (7) Vaginal fibroleiomyoma. Immunohistochemistry, Strong positive for Vimentin, bar = 100 μ m; (8) Vaginal fibroleiomyoma. Immunohistochemistry, Strong positive for Smooth muscle actin 1 (SMA-1), bar = 100 μ m

nucleolus. Minimal cellular pleomorphism and mitosis were noticed (Fig. 5). Picrosirius red clearly differentiated muscle and connective tissue components (Fig. 6). On IHC the tumour mass showed strong positive reaction to Vimentin (Fig. 7) and SMA (Fig. 8) and negative for CD34 and CD 68 as described by Avci *et al.* (2010).

Fibroleiomyomas, also known as leiomyomas, fibromyomas, myomas, fibroids and leiomyofibromatoses, are special types of leiomyoma and also have a significant fibrous component (Cooper and Valentine, 2002). This tumor occurs only in mature intact females and usually seen in multiples (Timurkaan *et al.*, 2009). The formation of fibroleiomyomas is believed to have a hormonal basis and an ovariectomy may cause regression

of growths (Cooper and Valentine, 2002). Fibroleiomyomas may be found at any location within the tubular genitalia, especially in the uterus and in some cases the vagina (Sapundzhev *et al.*, 2007). The tumours are commonly located on the anterior vaginal wall and the clinical signs of fibroleiomyomas are usually few, but under certain circumstances, such as large size and anatomic location, they may cause tenesmus, obstruction of the urethra, and vaginal bleeding (Park *et al.*, 2007). In the present case, the animal did not evince any kind of physiological abnormality except the maggot wound infestation. The obstetrical trauma during parturition would have paved way for minor injuries and attracted maggot infestation followed by spontaneous occurrence of tumour. The animal was held

by the owner for three months after surgery in which no signs of heat was observed. Later the cow was sold wherein the fertility of the cow could not be traced. Hence, a surgical removal is indicated for such tumors along with proper ligation of bleeding site.

Surgical excision of tumor mass under epidural anesthesia and wound management resulted in uneventful recovery of the animal.

REFERENCES

Avci, H., Serin, G., Aydogan, A. and Birincioglu, S. (2010). Primary vaginal fibroleiomyosarcoma in a 4-year-old Holstein-Friesian cow. *Turk. J. Vet. Anim. Sci.* **34(3)**: 307-311.

Cooper, B.J. and Valentine, B.A. (2002). Tumors of Muscle. 319-363. In: Mueten D.J. (Ed.): *Tumors in Domestic Animals*. (4th Ed.), Iowa State Press, Iowa. p. 788.

Park, S.J. Choi, S.J. Han, K.H. Park, K.H. Chung, H. and Song, J.M. (2007). Leiomyoma of the vagina that caused cyclic urinary retention. *Acta. Obstet. Gynecol. Scand.* **86**: 102-110.

Roberts, S.J. (1971). *Veterinary Obstetrics and Genital Diseases*. (2nd Edn.). C.B.S. Publisher and Distributors, Delhi. pp. 493-494.

Sapundzheiv, E. Pupaki, D. Zahariev, P. Georgiev, G. and Ivanov, I. (2007). Fibroleiomyoma in elephant uterus. *J. Am. Vet. Med. Assoc.* **54**: 499-500.

Timurkaan, N. Aydin, M. Yilmaz, F. and Cevik, A. (2009). Vaginal fibroleiomyoma in a cow: a case report. *Vet. Med.* **54(3)**: 138-141.

CONTRIBUTORS MAY NOTE

- Research/Clinical articles are invited for next issue from the Scientists/Veterinarians engaged in Veterinary Profession.
- Please follow strictly the format of 'The Haryana Veterinarian' for manuscript writing/submission.
- Please pay processing fee of Rs. 1000/- online in the account of Dean, College of Veterinary Sciences, along with each article.
- After revision, please return the revised manuscript and rebuttal at the earliest.
- Please mention your article reference number in all correspondence for a quick response.
- We solicit your co-operation.
- All correspondence should be addressed to 'The Editor', Haryana Veterinarian, Department of Veterinary Parasitology, College of Veterinary Sciences, LUVAS, Hisar-125004.

Editors