

FOETAL ECHOBIOOMETRY FOR PREDICTION OF GESTATIONAL AGE IN MEDIUM SIZED BITCHES

VINAY VIJAYAKUMAR*, K. KRISHNAKUMAR, A. METHAI¹ and P.S.L. SESH²

Department of Veterinary Gynaecology and Obstetrics, ¹Veterinary University Peripheral Hospital,

²Department of Veterinary Biochemistry, Tamil Nadu Veterinary and Animal Sciences University, Chennai-600 007 (T.N.)

Received: 29.11.2022; Accepted: 18.02.2023

ABSTRACT

Ultrasound measurement of foetal echobiometry with head and body measurement are commonly used to predict gestational age. In the present study, many more foetal structures measurements are taken to derive regression equations for determination of gestational age. Ten healthy normal bitches brought for pregnancy diagnosis aged between 2 and 6 years, already whelped once normally, 10 to 25 kg body weight with normal haematology and biochemistry values were utilized for this study. Serial echobiometric assessments using ultrasonography were performed on 10 days interval from day 30-35 upto whelping. The echobiometric values of placental thickness (PT), abdominal diameter (AD), occipito-frontal diameter (OFD), heart diameter (HD), heart length (HL), liver diameter (LD) and limb bud thickness (LB) showed highly significant ($P < 0.001$) correlation with gestational age. The significant results obtained on regression study ($P < 0.01$) of placental thickness ($r^2 = 98.4\%$), abdominal diameter ($r^2 = 98.6\%$), occipito-frontal diameter ($r^2 = 97.4\%$), heart diameter ($r^2 = 98.8\%$), heart length ($r^2 = 98.7\%$), liver diameter ($r^2 = 96.4\%$) and limb bud thickness ($r^2 = 98.5\%$) were utilized to derive regression equations for the prediction of the gestational age and assessment of foetal development in pregnant bitches. Based on the present study, it is inferred that more additional echobiometric parameters could be utilised to derive precise equations to arrive accurate gestational age in bitches.

Keywords: Echobiometry, Ultrasonography, Pregnant bitches

How to cite: Vijayakumar, V., Krishnakumar, K., Methai, A. and Sesh, P.S.L. (2023). Foetal echobiometry for prediction of gestational age in medium sized bitches. *The Haryana Veterinarian* 62(SI-2): 109-112.

Ultrasonography is emerging as a reliable, non-invasive, safe and less expensive tool for pregnancy diagnosis in bitches during last decade (Khatti *et al.*, 2017). Aside, pregnancy diagnosis, it also helps in detection of foetal viability, foetal abnormalities and uterine pathologies, prediction of adverse pregnancy outcomes and estimation of foetal growth. Embryonic structures and heartbeat can be detected at the earliest on day 17 and 18, respectively (Maronezi *et al.*, 2021). The measurement of organs dimensions, body parts or gestational structures using ultrasound is known as echobiometry. In general, B-mode ultrasonography is used to visualise the organ or structure and the callipers in-built are used to measure the organ. Nowadays, echobiometry is gaining much more importance in the field of obstetrics which aids in the diagnosis of restricted foetal growth and foetal abnormalities (Johnsen *et al.*, 2008). Foeto-maternal structures like gestational sac, foetal head and body length are measured and found to have good correlation with the age of the foetus; parameters like inner chorionic cavity diameter and head diameter are also used for the prediction of gestational age in canine pregnancy (Yeager *et al.*, 1992; Nyland and Mattoon, 2002). The echobiometry studies during mid-gestation is more accurate for the prediction of gestational age and correction factors could be applied for bitches coming under extreme body weight categories (Kutzler *et al.*, 2003). In the present study, the growth trend

of foetal and gestational structures were measured and correlated with the gestational age to assess the foetal growth.

MATERIALS AND METHODS

This study was conducted in 10 normal pregnant bitches under 6 years of age, body weight between 10-25 kg, with normal haematology and biochemistry values and a history of at least one whelping with healthy litter presented to small animal gynaecology outpatient unit of Madras Veterinary College Teaching Hospital.

The ultrasonographic scanning was performed for all the selected bitches without any sedation as per the standard technique by Nyland and Mattoon (2002). The ultrasound examinations were performed using Esaote Mylab Delta Vet scanner with a micro convex probe of 6 to 10 MHz frequency. All the selected bitches were diagnosed as pregnant and requested to present between day 30 and 35 after mating for echobiometry and the gestational age was confirmed by measuring gestational sac diameter/inner chorionic cavity diameter. Urinary bladder was located as the landmark and gestational sac and foetus were visualised in the neighbourhood. Parameters including placental thickness (PT), occipito-frontal diameter (OFD), abdominal diameter (AD), heart diameter (HD), heart length (HL), liver width (LW) and limb bud thickness (LB) were recorded using the measuring callipers.

The measurements were recorded at a fixed interval of 10 days till whelping in all the bitches. The accumulated

*Corresponding author: vinayvjkmr@gmail.com

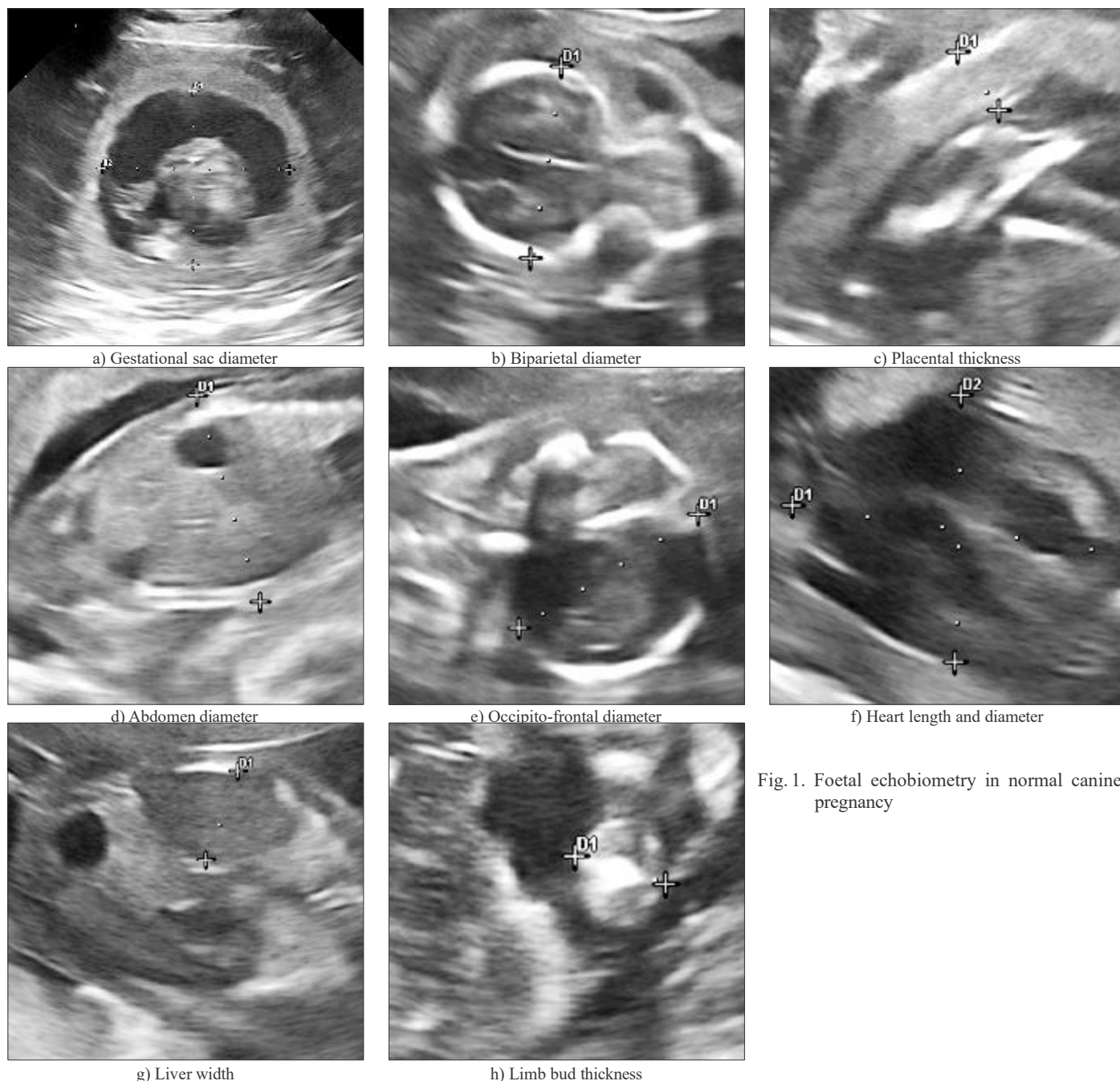


Fig. 1. Foetal echobiometry in normal canine pregnancy

Table 1. Mean (+SE) values of echobiometric parameters and regression equation with gestational age in normal pregnancy

Parameter	Day 30-35	Day 40-45	Day 50-55	Day 60-65	Regression equation	P value	R2
PT	0.396±0.014	0.598±0.008	0.761±0.009	0.835±0.011	$PT = 0.017 \times GA - 0.16$	<0.01	0.984**
AD	1.285±0.06	2.571±0.048	3.921±0.068	4.442±0.02	$AD = 0.121 \times GA - 2.772$	<0.01	0.986**
OFD	1.097±0.048	1.811±0.063	2.744±0.064	3±0.045	$OFD = 0.074 \times GA - 1.408$	<0.01	0.974**
HD	0.573±0.037	0.946±0.022	1.452±0.061	1.728±0.02	$HD = 0.043 \times GA - 0.894$	<0.01	0.988**
HL	0.633±0.028	1.113±0.045	1.816±0.079	2.329±0.019	$HL = 0.063 \times GA - 1.58$	<0.01	0.987**
LW	0.456±0.028	0.849±0.017	1.536±0.022	1.665±0.04	$LW = 0.049 \times GA - 1.208$	<0.01	0.964**
LB	0.296±0.021	0.59±0.017	0.87±0.041	1.141±0.034	$LB = 0.031 \times GA - 0.776$	<0.01	0.985**

**Correlation of determination have high level ($P < 0.01$) of significance

(PT – Placental Thickness, AD – Abdomen Diameter, OFD – Occipito-Frontal Diameter, HD – Heart Diameter, HL – Heart Length, LW- Liver Width and LB – Limb Bud thickness)

Table 2. Correlation matrix for echobiometric parameters with gestational age in normal pregnancy

	DAY	PT	AD	OFD	HD	HL	LW	LB
DAY	1	0.992***	0.993***	0.987***	0.994***	0.994***	0.982***	0.993***
PT	0.992***	1	0.996***	0.989***	0.983***	0.976***	0.985***	0.979***
AD	0.993***	0.996***	1	0.995***	0.989***	0.982***	0.991***	0.978***
OFD	0.987***	0.989***	0.995***	1	0.992***	0.983***	0.988***	0.979***
HD	0.994***	0.983***	0.989***	0.992***	1	0.997***	0.981***	0.991***
HL	0.994***	0.976***	0.982***	0.983***	0.997***	1	0.973***	0.993***
LW	0.982***	0.985***	0.991***	0.988***	0.981***	0.973***	1	0.961***
LB	0.993***	0.979***	0.978***	0.979***	0.991***	0.993***	0.961***	1

*** Correlation coefficients have high level ($P < 0.001$) of significance

(PT – Placental Thickness, AD – Abdomen Diameter, OFD – Occipito-Frontal Diameter, HD – Heart Diameter, HL – Heart Length, LW – Liver Width and LB – Limb Bud thickness)

data was statistically analysed using SPSS version 20.0 (IBM, USA) for Windows. Correlation analysis was performed to study the linear relationship between the parameters and gestational age of the foetus. Regression analysis was done to obtain the regression coefficient and to form the regression equation for the evaluation of foetal growth.

RESULTS AND DISCUSSION

The foeto-maternal echobiometric parameters which included PT, OFD, AD, HD, HL, LW and LB obtained by serial ultrasonographic assessments from mid gestation to whelping were significantly correlated ($P < 0.001$) with the gestational age of the foetus (Table 1). The correlation matrix of each measurement revealed a linear relationship with the gestational age of the foetus (Table 2).

Coefficient of determination derived for the measurements of abdominal diameter ($r^2 = 98.6\%$), heart diameter ($r^2 = 98.8\%$) and heart length ($r^2 = 98.7\%$) were significantly higher ($p < 0.01$) and regression equation formed could be applied to predict the gestational age of the foetus and evaluation of foetal growth. The results of echobiometry study of abdominal diameter was in agreement with observations of Miranda and Domingues (2010) who reported a high coefficient of determination ($p < 0.01$) for abdominal diameter ($r^2 = 97\%$) with respect to gestational age. Coefficients of determination obtained in the present study were higher than the observations of Feliciano *et al.* (2015) who reported lower coefficient values to the parameters abdominal diameter ($r^2 = 86\%$), heart diameter ($r^2 = 79\%$) and heart length ($r^2 = 79\%$) which might be due to the breed difference and wider body weight range of the bitches.

Occipito-frontal diameter ($r^2 = 97.4\%$) was having very good correlation with the gestational age. The results obtained in this study are in concurrence with the

observation of Miranda and Domingues (2010) who observed 99 per cent coefficient of determination. Placental thickness ($r^2 = 98.4\%$) was found to have significant correlation with gestational age and the results are in agreement with the observations of Maldonado *et al.* (2012) who reported a statistically significant positive correlation ($r^2 = 87\%$) between echobiometric measurement of placental thickness and gestational age. The results obtained in this study is in contrast to the observations of Feliciano *et al.* (2015) who reported a lower correlation ($r^2 = 37\%$) between placental thickness and gestational age and suggested that the parameter cannot be used for gestational age calculation. This variation could be due to the wider range of bodyweight of the bitches selected for the study and the high angle dependence of the parameter which demands measurement in a constant view of B mode ultrasonography.

In this study, liver diameter ($r^2 = 96.4\%$) and limb bud thickness ($r^2 = 98.5\%$) were observed to have sufficiently high correlation with gestational age of the foetus. Hence, the regression equation formed could be used to predict the gestational age of the foetus as well as for the evaluation of foetal growth. However, on perusal of literature, there is no data available for comparison and this could be the first report.

All the bitches included in this study delivered an average of 6 healthy pups from 61 to 65 days of gestation without any complication.

CONCLUSION

Foeto-maternal echobiometric values of various parameters derived in the present study could supplement to the conventional small animal reproductive ultrasound examination. Echobiometry of foetus had precise significance with the different stages of canine pregnancies and proved as an accurate diagnostic tool to predict the gestational age

which could be utilized for better whelping management.

REFERENCES

- Feliciano, M.A.R., Maciel, G.S., Coutinho, L.N., Almeida, V.T., Uscategui, R.R. and Vicente, W.R.R. (2015). Gestational echo biometry in brachycephalic pregnant bitches. *Ciê. Anim. Bras.* **16(3)**: 419-427.
- Johnsen, S.L., Wilsgaard, T., Rasmussen, S., Hanson, M.A., Gdofrey, K.M. and Kiserud, T. (2008). Foetal size in the second trimester is associated with the duration of pregnancy, small foetuses having longer pregnancies. *BMC Pregnancy Childbirth.* **8**: 1-7.
- Khatti, A., Jena, D., Singh, S. and Mondal, T. (2017). Application of ultrasonography in canine pregnancy: An overview. *Int. J. Livest. Res.* **7(2)**: 20-27.
- Kutzler, M.A., Yeager, A.E., Mohammed, H.O. and Meyers-Wallen, V.N. (2003). Accuracy of canine parturition date prediction using foetal measurements obtained by ultrasonography. *Theriogenol.* **60(7)**: 1309-1317.
- Maldonado, A.L., Araujo Júnior, E., Mendonça, D.S., Nardoza, L.M., Moron, A.F. and Ajzen, S.A. (2012). Ultrasound determination of gestational age using placental thickness in female dogs: an experimental study. *Vet. Med. Intern.* **2012**: 850867.
- Maronezi, M., Simões, A., Uscategui, R., Pavan, L., Rodriguez, M., Sitta G., Mariano, R., Santos, V. and Feliciano, M. (2021). Gestational echobiometry in brachycephalic bitches using high-definition ultrasonography. *Pesq. Vet. Bras.* **41**: e06650.
- Miranda, S.A. and Domingues, S.F.S. (2010). Conceptus ecobiometry and triplex Doppler ultrasonography of uterine and umbilical arteries for assessment of fetal viability in dogs. *Theriogenol.* **74**: 608-617.
- Nyland, T.G. and Mattoon, J.S. (2002). Ovaries and uterus. In: Small animal diagnostic ultrasound. WB Saunders Co. pp. 231-249.
- Yeager, A.E., Mohammed, H.O., Meyers-Wallen, V., Vannerson, L. and Concannon, P.W. (1992). Ultrasonographic appearance of the uterus, placenta, foetus, and foetal membranes throughout accurately timed pregnancy in beagles. *Am. J. Vet. Res.* **53(3)**: 342-351.

CONTRIBUTORS MAY NOTE

- Research/Clinical articles are invited for next issue from the Scientists/Veterinarians engaged in Veterinary Profession.
- Please follow strictly the format of 'The Haryana Veterinarian' for manuscript writing/submission.
- Please pay processing fee of Rs. 1000/- online in the account of Dean, College of Veterinary Sciences, along with each article.
- After revision, please return the revised manuscript and rebuttal at the earliest.
- Please mention your article reference number in all correspondence for a quick response.
- We solicit your co-operation.
- All correspondence should be addressed to 'The Editor', Haryana Veterinarian, Department of Veterinary Parasitology, College of Veterinary Sciences, LUVAS, Hisar-125004.

Editors