

## A SURVEY ON INCIDENCE AND RADIOGRAPHIC ASSESMENT OF HIP DISORDERS IN DOGS

S. KOKILA\*, S. DHARMACEELAN, S. KATHIRVEL, A. PALANISAMI and S. MUTHUKRISHNAN  
Department of Veterinary Surgery and Radiology, Veterinary College and Research Institute, Namakkal-637001  
Tamil Nadu Veterinary and Animal Sciences University, Tamil Nadu

Received: 28.10.2022; Accepted: 06.01.2023

## SUMMARY

The purpose of this study was to determine the prevalence of canine hip disorders at Small Animal Surgery unit of Veterinary Complex, Veterinary College and Research Institute, Namakkal from March 2021 to February 2022. Out of the 1204 orthopaedic cases reported during the study period, 193 cases were suspected for hip disorders based on history and orthopaedic examination. Out of these, 122 dogs of different age, breed and sex were diagnosed as having hip disorder based on confirmative radiographic examination which accounts 16.03%. The incidence of hip dysplasia was found to be high in German Shepherd (41.17%). The prevalence of hip disorder was higher in male (74.59 %) than female (25.40 %). All age groups were affected, but 1-5 years (n=55) showed higher incidence. Clinical signs and orthopaedic examination of hip disorders ranged from hindlimb limping, bunny hopping, non-weight bearing, crepitation during abduction, shortening of limb etc. Radiographic evaluation was done for 193 cases- two orthogonal views (Pelvis ventro-dorsal and medio-lateral). Norberg angle was measured in 23 dogs suspected for hip dysplasia. Out of which 14 cases were German Shepherd (83°- 100°) and 5 cases of Labrador (72°-98°). To conclude plain radiographic examination is the most basic and critical method for the diagnosis of hip disorders. This article reviews the standard protocols used to obtain radiographic projections of the hip and radiographic measurements used to adequately and reliably recognize structural diseases of the hip.

**Keywords:** Hip dysplasia, German Shepherd, Norberg angle

**How to cite:** Kokila, S., Dharmaceelan, S., Kathirvel, S., Palanisami, A. and Muthukrishnan, S. (2023). A survey on incidence and radiographic assesment of hip disorders in dogs. *The Haryana Veterinarian* 62(SI-2): 144-146.

The hip is the largest joint in the body, and susceptible to several injuries. Trauma, genetics, infections, or aging associated with normal wear and tear can all cause hip problems in dogs. Hip dysplasia, dislocation, osteochondrosis dissecans, osteoarthritis, fractures were the various disorders affecting hip joint. Hip dysplasia is a disease in dogs that causes malformation in the hip joint, leading to uneven rubbing of cartilage in the joint and resulting in pain, lameness, and early onset osteoarthritis (Schachner and Lopez, 2015). Osteoarthritis is a progressive inflammatory condition that results in swelling and loss of articular cartilage in the joint. Cartilage loss leads to pain and reduced mobility in dogs, and can be a significant issue in large breed dogs. There is no cure, but pain and mobility associated with osteoarthritis can be managed with medications, supplements, diet, exercise, and other therapies. Hip dislocation in dogs occurs when the hip joint becomes dislocated due to trauma or the hip dislocates due to severe hip dysplasia.

Dogs reported to Veterinary clinical complex with hip disorders were selected. Incidence study- age, breed and sex were recorded. Selected animals were subjected to radiographic evaluation and 23 animals were pre-medicated with Inj. Xylazine for measuring Norberg angle. Out of the 1204 orthopaedic cases presented to Veterinary Clinical Complex, Veterinary College and Research Institute, Namakkal during the period of March 2021 to February 2022, 193 cases were suspected for hip disorders based on history and orthopaedic examination. Out of these, 122 dogs of different

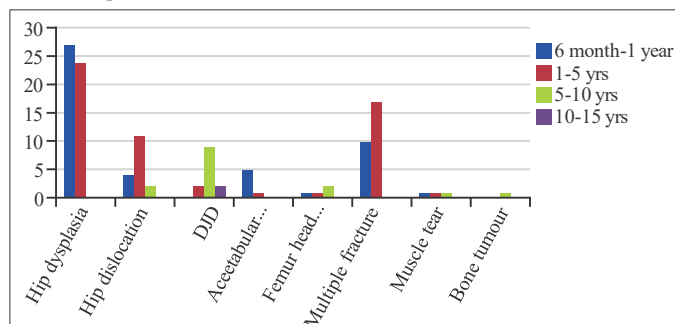
age, breed and sex were diagnosed as having hip disorder based on radiographic examination.

## i. Breed- wise occurrence

**Table 1. Breed wise incidence of hip disorders in dogs**

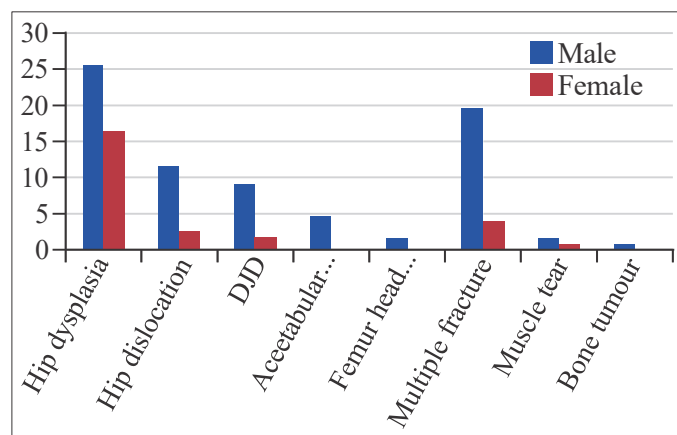
CONDITION	BREED									
	German shepherd	Labrador	Spitz	Dachshund	Rottweiler	Chippiparai	Nondescript	Great dane	Golden retriever	Dobermann
Hip dysplasia	21	12	2	-	1	1	6	3	2	3
Hip dislocation	2	2	3	2	2	-	7	-	-	-
DJD	5	6	2	-	-	-	-	-	-	-
Acetabular fracture	4	-	-	-	-	1	1	-	-	-
Femur head fracture	1	-	1	-	-	-	-	-	-	-
Multiple fracture	5	-	-	-	-	-	24	-	-	-
Sprain	-	1	-	-	-	-	1	-	-	-
Bone tumor	-	1	-	-	-	-	-	-	-	-

## ii. Age wise occurrence



\*Corresponding author: kokilagopal18@gmail.com

### iii. Sex wise occurrence



### V) Radiographic evaluation:

**Hip dysplasia:** Radiographic evaluation of hip dysplasia was done by taking three views-pelvis ventrodorsal extended view (Fig. 1), pelvis ventrodorsal frog leg view (Fig. 2) and pelvis lateral view (Fig. 3).

**Norberg angle :** It is the angle between a line starting at the center of the femoral head and drawn to the intersection between the craniolateral and dorsal acetabular margin of the acetabulum. Twenty three animals were measured Norberg angle to diagnose hip dysplasia.

**Table 2. Norberg angle for hip dysplasia**

Breed	No. of cases	Norberg angle
German Shepherd	14	83°- 100°
Labrador	5	72° - 98°
Great Dane	2	99°-101°
Rottweiler	1	101°
Golden retriever	1	98°

**Hip dislocation:** Hip dislocation was recorded in seventeen animals. Radiographic evaluation was done by taking two orthogonal view namely pelvis ventrodorsal and lateral view (Fig. 4). All were craniodorsal dislocation.

**Degenerative joint disease:** Degenerative osteoarthritic changes noticed in thirteen animals. Classical signs of hip subluxation, osteophyte formation and femur head remodeling were observed (Figs. 5 and 6).

**Fractures:** Acetabular rim (Fig. 7) and femur head (Fig. 8) fracture were noticed in eight animals. Multiple fractures were noticed in twenty nine animals. It involved not only multiple pelvis fracture but also femur, tibia, humerus and lumbar fractures. (Fig. 9)

**Tumour:** Sun burst appearance was noticed in one (Labrador) animal in right ilium and acetabulum (Fig. 10). Few focal, solid, metastatic lesions were also noticed in lung parenchyma (Fig. 11) suggestive of osteosarcoma.

Among the 1204 orthopaedic cases reported to VCC, Namakkal Small Animal Surgery Unit between March 2021 to February 2022, 122 cases were diagnosed for hip disorders. The incidence of hip disorders in dogs was 16.03%. In the present study among the hip disorders, the incidence of hip dysplasia was found to be high.

Among the breeds, incidence of hip dysplasia was found to be high in German Shepherd (41.17%) followed by Labrador (23.52%). This is in accordance with findings of (Leppanen *et al.*, 2000) who stated that the prevalence varies by breeds and breed groups, but is common in German Shepherds with a reported 37% incidence. This may be due to heredity and lack of awareness among

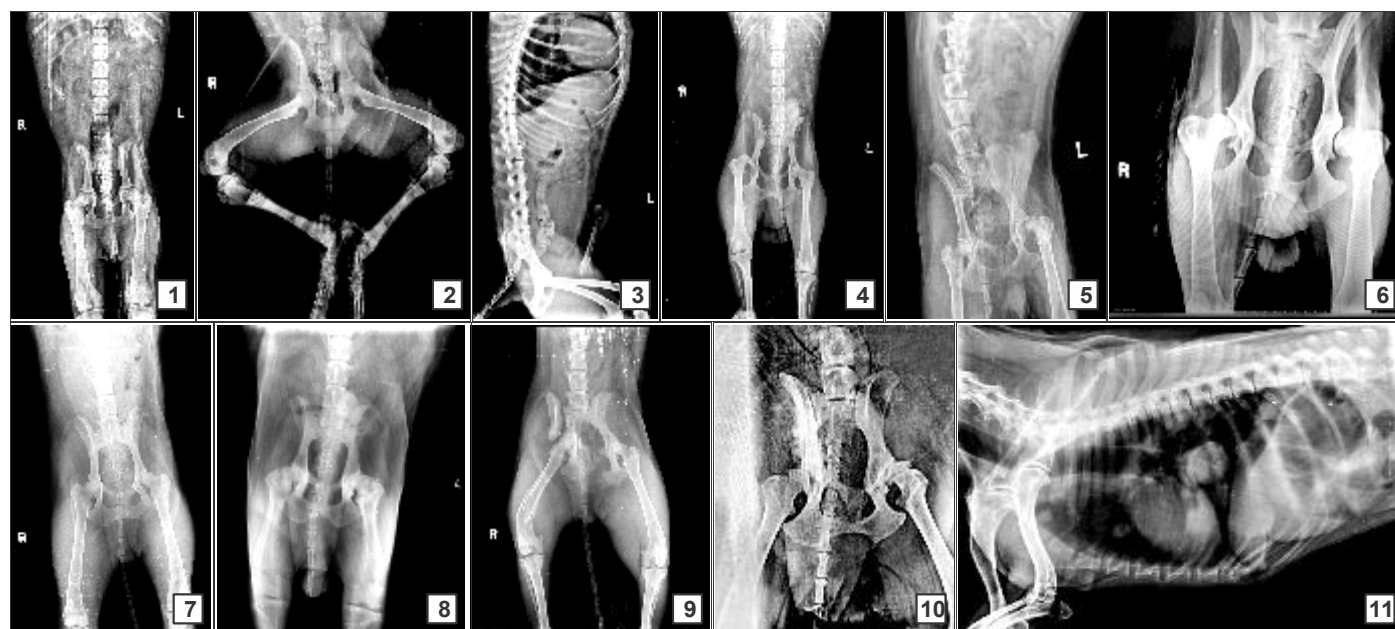

Fig. 1-11. (1) X-ray Pelvis Ventrodorsal; (2) X-ray-Pelvis-ventrodorsal-frog leg view; (3) X-ray-Pelvis-lateral view; (4) Right craniodorsal hip dislocation; (5) Osteoarthritic changes noticed in left hip; (6) Osteophyte formation in acetabular rim in right hip; (7) Left acetabular rim fracture; (8) Bilateral stable femur head Fracture; (9) Fracture of right ilium, pubis, acetabulum and distal femur; (10) Sun burst appearance of right ilium and acetabulum; (11) Metastatic lesion in lung parenchyma

owners not to use such animal for breeding. Severity of chronic hip dysplasia depends on environmental and genetic factors with signs appearing at the age of three to four years resulting in instability and subluxation. The incidence of degenerative joint disease (DJD) was more in Labrador (46.15%) and German Shepherd (38.46%). This correlate with the findings of (Smith *et al.*, 2000) who stated that the risk of having degenerative joint disease was 4.95 times the risk for German Shepherd of the other 3 breeds (Golden Retrievers, Labrador Retrievers, and Rottweilers) combined. In all breeds, the probability of having DJD increased with age.

Hip disorders were found to be high in the age group of one to five years followed by six month to one year. The prevalence of hip disorder was higher in male than female. This may be due to door dashing, fence jumping, wandering, roaming, fighting with other male dogs.

According to Anderson *et al.* (2020) osteoarthritis continues to be highly prevalent within the dog population, with substantial implications for quality of life and welfare.

Szabo *et al.* (2007) reported that the radiography has long been the gold standard to assess and quantify joint changes associated with canine hip dysplasia joint remodelling. Worldwide, there are five popular, standardized evaluation systems with distinct metrics that are used to grade canine radiographic coxofemoral joint conformation and degenerative changes. In the present study three views for hip dysplasia and two orthogonal views for other hip disorders were taken. Norberg angles was measured for twenty three animalsover one year of age. The angle measured coincides with the study result of (Tomlinson and Johnson, 2000) who studied percentage coverage of the femoral head (PC) and Norberg angle (NA) in 4 common breeds of dogs. His study results showed Norberg angle ranged from 67.4 to 124.4 degrees for Labrador Retrievers, 59.7 to 128.6 degrees for Rottweilers, 70.2 to

119.4 degrees for Golden Retrievers, and 55.3 to 121.3 degrees for German Shepherd.

Osteosarcoma of hip and pelvic bone was recorded in a nine year old, male Labrador. The dog also showed few solid metastases in lung parenchyma. Osteosarcoma (OS) is a malignant tumor of mesenchymal origin that produces osteoid. OS accounts for approximately 85% of all primary canine bone tumors and is almost exclusively observed in large or giant breeds. The median age of onset of clinical signs ranges from 8 to 10 years. This is in accordance with the findings of (Boerman *et al.*, 2012).

## REFERENCES

- Anderson, K.L., Zulch, H., O'Neill, D.G., Meeson, R.L. and Collins, L.M. (2020). Risk factors for canine osteoarthritis and its predisposing arthropathies: a systematic review. *Front. Vet. Sci.* **7**: 220.
- Boerman, I., Selvarajah, G.T., Nielen, M. and Kirpensteijn, J. (2012). Prognostic factors in canine appendicular osteosarcoma—a meta-analysis. *BMC Vet. Res.* **8**(1): 1-12.
- Leppanen, M., Maäki, K., Juga, J. and Saloniemi, H. (2000). Estimation of heritability for hip dysplasia in German Shepherd dogs in Finland. *J. Anim. Breed Genet.* **117**(2): 97-103.
- Schachner, E.R. and Lopez, M.J. (2015). Diagnosis, prevention, and management of canine hip dysplasia: a review. *Vet. Med. Res. Repo.* **6**: 181-192.
- Smith, G.K., Mayhew, P.D., Kapatkin, A.S., McKelvie, P.J., Shofer, F.S. and Gregor, T.P. (2001). Evaluation of risk factors for degenerative joint disease associated with hip dysplasia in German Shepherd dogs, Golden Retrievers, Labrador Retrievers, and Rottweilers. *J. Am. Vet. Med. Assoc.* **219**(12): 1719-1724.
- Szabo, S.D., Biery, D.N., Lawler, D.F., Shofer, F.S., Powers, M.Y., Kealy, R.D. and Smith, G.K. (2007). Evaluation of a circumferential femoral head osteophyte as an early indicator of osteoarthritis characteristic of canine hip dysplasia in dogs. *J. Am. Vet. Med. Assoc.* **231**(6): 889-892.
- Tomlinson, J.L. and Johnson, J.C. (2000). Quantification of measurement of femoral head coverage and Norberg angle within and among four breeds of dogs. *Am. J. Vet. Res.* **61**(12): 1492-1500.