

PATHOLOGY OF CONGENITAL GOITER IN A GOAT KID

ANKITA, RAKESH KUMAR*, SMRITI JAMWAL, ABHISHEK VERMA, SAHIL CHOUDHARY,
R.D. PATIL and R.K. ASRANI

Department of Veterinary Pathology, DGCN COVAS CSKHPKV, Palampur-176062, Himachal Pradesh, India

Received: 12.12.2022; Accepted: 05.04.2023

SUMMARY

A newly born goat kid was present for necropsy examination with bilateral enlargement at cranio-ventral region. A detailed post-mortem examination has revealed uniform bilateral enlargement in lobes of thyroid gland from which blood oozed out on cutting. Giemsa stained cytosmear examination revealed the presence of cluster of epithelial cells showing slight pleomorphism. Histopathological examination of preserved tissue section showed hyper chromatic and hyperplastic changes in follicular epithelial cells and parafollicular cells. Hence, above evidences establishes that the presented case is suspected to be died of respiratory failure resulted due to the compression of trachea caused by enlargement of thyroid gland.

Keywords: Goat, Goiter, Iodine deficiency, Thyroid gland

How to cite: Ankita, Kumar, R., Jamwal, S., Verma, A., Choudhary, S., Patil, R.D. and Asrani, R.K. (2023). Pathology of congenital goiter in a goat kid. *Haryana Vet.* 62(SI-2): 174-175.

Goiter is non-neoplastic and non-inflammatory enlargement of butterfly shaped thyroid gland located at base of neck (Cheema *et al.*, 2010). Human beings are often suffering with goiter due to iodine deficiency in diet. The outcome of iodine deficiency leads to hypertrophic and hyperplastic changes in the thyroid gland. Among domestic animals, goat kids are susceptible for suffering from congenital goiter. This condition is indicated by an increase in the size of fetus, prolonged gestation, myxoedema and dystocia (Bhardwaj *et al.*, 2022) in-utero deficiency of iodine, iodine deficiency in the diet of dam, ingestion of goitrogenic plants, hereditary and congenital hypothyroidism are the common causes for the enlargement of thyroid gland. Among these causes iodine deficiency is reported to be the most common cause for congenital goiter in goats. Iodine has a principal role in the production and secretion of triiodothyronine (T3) and thyroxine (T4), as iodination of thyroglobulin tyrosine, (iodotyrosines) leads to the formation of thyroid hormone which is stimulated by thyroid stimulating hormone. Survival rate of the lambs and kids is poor in goiter and attributed to the impaired thermoregulation, decreased surfactant secretion, reduction in cardiac output, and arrhythmia (Davoodi *et al.*, 2022).

In the present case study, a goat kid was presented with the history of sudden death due to swelling at cranio-ventral region. Post mortem examination was conducted in the necropsy facility of department of Veterinary Pathology, DGCN COVAS, CSKHPKV, Palampur. The carcass was thoroughly examined for gross pathological alterations. Impression smear was taken from the swelling and was stained with Giemsa stain. The 0.5 cm thick representative sections from swelling were collected in

10% neutral buffered formalin (NBF). The fixed tissue sections were dehydrated in ascending grades of alcohol, cleared in benzene, impregnated in molten paraffin and sectioned to 5 micron in microtome. Then cut tissue sections were stained with Haematoxylin and Eosin (H&E) stain as per the standard protocol (Luna, 1968). The microscopic lesions were examined under microscope and microphotography was done (OLUMPUS BX40).

The systemic necropsy examination of goat kid revealed uniform bilateral enlargement in the cranio-ventral region of neck. The skin at this region was pale-white, thickened with myxedema and devoid of hairs. These enlargements were palpated and found to be free from any attachments with surrounding tissue indicated the lobes of thyroid gland (Fig. 1). The cut section of the glands exhibited increased vascularity with oozing of free flowing blood. An impression smear collected from the cut surface of thyroid glands shown numerous cluster of glandular cells undergoing hyperchromatic changes with variation in their size (Fig. 2). A thorough histological examination has reflected variation in the size of thyroid follicles with profound hyperplastic changes (Fig. 3). The eosinophilic colloid material was found to be decreased in association with altered follicular architecture (Fig. 4). The histopathological finding in our study were in correlation with the results of a study conducted by Davoodi *et al.* (2022). On the basis of gross, cytological and histopathological findings, the kid was affected with congenital goiter as a result of the pituitary gland's excessive production of TSH and the thyroid's attempt to make up for a lack of thyroid hormones (Davoodi *et al.*, 2022). In the preset report, the enlargement at cranio-ventral region of neck has led to compression of tracheal lumen and death due to dyspnoea. Several previous studies

*Corresponding author: rkvetpath@gmail.com

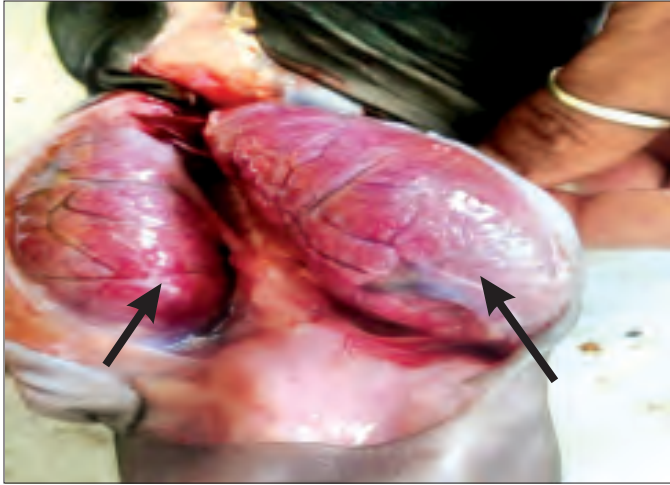


Fig.1. Uniform bilateral enlargement of thyroid gland with increased vascularity (thick arrows)

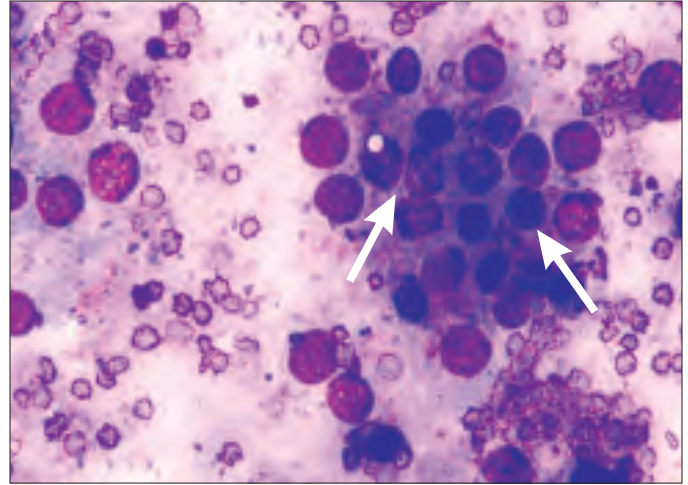


Fig.2. Epithelial cells in cluster with mild pleomorphism (arrows). Giemsa stain $\times 200$

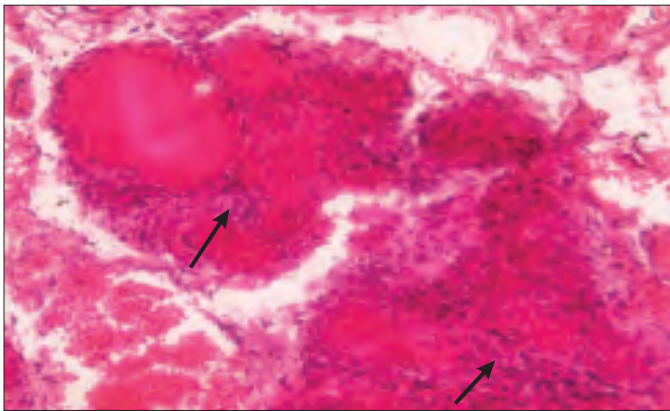


Fig.3. Columnar epithelial cells depicting hyperplastic changes (arrows). H&E $\times 200$

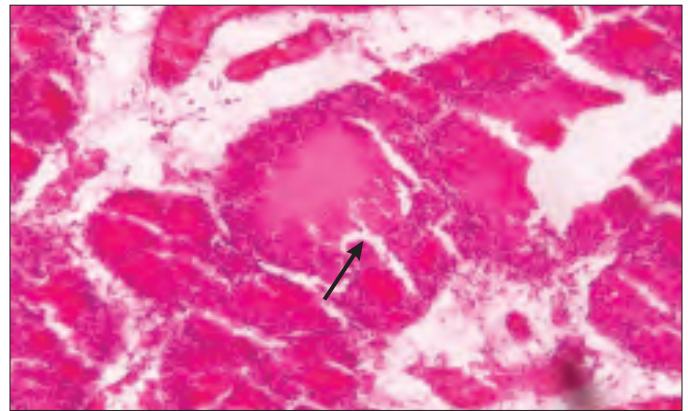


Fig.4. Thyroid follicle with partial depletion of colloid (arrow). H&E $\times 100$

in lambs and kids have shown hyperplastic changes in thyroid gland leading to the development of goiter (Bhardwaj 2018). Therefore, the presented case signifies the need of regular supplementation of iodine in the diet of pregnant doe and kids, especially in hilly area such as Himachal Pradesh.

REFERENCES

Bhardwaj, A., Jadhao, A., Sheetal, S.K. and Bawaskar, M.S. (2022). Thyroid profile of a hypothyroidism affected doe: A case report. *Haryana Vet.* **61(SI)**: 121-122.

Bhardwaj, R.K. (2018). Iodine deficiency in goats. In: *Goat science*.

London: Intech Open. <https://www.intechopen.com/chapters/58519>.

Cheema, A.H., Shakoar, A. and Shahzad, A.H. (2010). Congenital goitre in goats. *Pak. Vet. J.* **30**(1).

Davoodi, F., Zakian, A., Rocky, A. and Raisi, A. (2022). Incidence of iodine deficiency and congenital goitre in goats and kids of Darreh Garm region, Khorramabad. *Iran. J. Vet. Res.* **8(1)**: 336-342.

Luna, L.G. (1968). *Manual of histologic staining methods of the Armed Forces Institute of Pathology*. (3rd Edn.), McGraw-Hill, New York, pp. 32-39.